National Comprehensive Cancer Network®

NCCN Clinical Practice Guidelines in Oncology (NCCN Guidelines®)

Breast Cancer Screening and Diagnosis

Version 1.2026 — March 5, 2026

NCCN recognizes the importance of clinical trials and encourages participation when applicable and available. Trials should be designed to maximize inclusiveness and broad representative enrollment.

NCCN Guidelines for Patients® available at www.nccn.org/patients

Version 1.2026 03/05/26 © 2026 National Comprehensive Cancer Network® (NCCN®), All rights reserved. NCCN Guidelines® and this illustration may not be reproduced in any form without the express written permission of NCCN.

PLEASE NOTE that use of this NCCN Content is governed by the End-User License Agreement, and you MAY NOT distribute this Content or use it with any artificial intelligence model or tool.
Printed by Ambrish Chauhan on 5/1/2026 7:03:18 AM. Copyright © 2026 National Comprehensive Cancer Network, Inc. All Rights Reserved.

***Therese B. Bevers, MD/Chair Þ**
The University of Texas
MD Anderson Cancer Center

***Bethany L. Niell, MD, PhD/Vice-Chair ф**
Moffitt Cancer Center

Shadi Aminololama-Shakeri, MD ф
UC Davis Comprehensive Cancer Center

Jennifer L. Baker, MD ¶
UCLA Jonsson Comprehensive Cancer Center

Debbie L. Bennett, MD ф
Siteman Cancer Center at Barnes-Jewish Hospital and Washington University School of Medicine

Ermelinda Bonaccio, MD ф
Roswell Park Comprehensive Cancer Center

Astrid M. Botty van den Bruele, MD ¶
Duke Cancer Institute

Melissa S. Camp, MD ¶
Johns Hopkins Kimmel Cancer Center

Meghan R. Flanagan, MD, MPH ¶
Fred Hutchinson Cancer Center

Jeffrey R. Hawley, MD ф
The Ohio State University Comprehensive Cancer Center - James Cancer Hospital and Solove Research Institute

Mark Helvie, MD ф Þ
University of Michigan Rogel Cancer Center

Tamarya L. Hoyt, MD ф
Vanderbilt-Ingram Cancer Center

Dezheng Huo, PhD &
The UChicago Medicine Comprehensive Cancer Center

Jennifer L. Ivanovich, MS, CGC ₪
Indiana University Melvin and Bren Simon Comprehensive Cancer Center

Swati Kulkarni, MD ¶
Robert H. Lurie Comprehensive Cancer Center of Northwestern University

Rachael B. Lancaster, MD ¶
O'Neal Comprehensive Cancer Center at UAB

Caitlin B. Mauer Hall, MA, MS, CGC ₪ †
UT Southwestern Simmons Comprehensive Cancer Center

Rosa Nouvini, MD †
Memorial Sloan Kettering Cancer Center

Bhavika K. Patel, MD ф
Mayo Clinic Comprehensive Cancer Center

Liane Philpotts, MD ф
Yale Cancer Center/Smilow Cancer Hospital

Donna Plecha, MD ф
Case Comprehensive Cancer Center/ University Hospitals Seidman Cancer Center and Cleveland Clinic Taussig Cancer Institute

Rebecca Shatsky, MD †
UC San Diego Moores Cancer Center

Mary Lou Smith, JD, MBA ¥
Research Advocacy Network

Clarie L. Streibert, MD ф
Fox Chase Cancer Center

Roberta M. Strigel, MD, MS ф
University of Wisconsin Carbone Cancer Center

Regan M. Taylor, MD Þ
Fred & Pamela Buffett Cancer Center

Candice N. Thompson, MD ¶
Stanford Cancer Institute

Natascha S. Thompson, MD Þ
St. Jude Children's Research Hospital/ The University of Tennessee Health Science Center

Susan P. Weinstein, MD ф
Abramson Cancer Center at the University of Pennsylvania

Nicole S. Winkler, MD ф
Huntsman Cancer Institute at the University of Utah

Dulcy E. Wolverton, MD ф
University of Colorado Cancer Center

Eren Yeh, MD ф
Dana-Farber/Brigham and Women's Cancer Center

NCCN
Mary Anne Bergman
Katie Stehman, PA-C, MMS

NCCN Guidelines Panel Disclosures

ф Diagnostic/ Interventional radiology & Epidemiology	₪ Medical genetics/ genomics
Þ Internist/Internal medicine, including family practice, preventive management	† Medical oncology
	¥ Patient advocacy
	¶ Surgery/Surgical oncology
	* Discussion Section Writing Committee

Version 1.2026, 03/05/26 © 2026 National Comprehensive Cancer Network® (NCCN®), All rights reserved. NCCN Guidelines® and this illustration may not be reproduced in any form without the express written permission of NCCN.

PLEASE NOTE that use of this NCCN Content is governed by the End-User License Agreement, and you MAY NOT distribute this Content or use it with any artificial intelligence model or tool.
Printed by Ambrish Chauhan on 5/1/2026 7:03:18 AM. Copyright © 2026 National Comprehensive Cancer Network, Inc. All Rights Reserved.

NCCN Guidelines Version 1.2026
Breast Cancer Screening and Diagnosis

NCCN Breast Cancer Screening and Diagnosis Panel Members
Summary of the Guidelines Updates

Clinical Encounter Including Risk Assessment (BSCR-1)
Average Risk, Screening/Follow-Up (BSCR-1)
Increased Risk, Screening/Follow-Up (BSCR-2)
Signs/Symptoms During Clinical Encounter (BSCR-5)
- Palpable Symptom (BSCR-6)
- Nipple Inversion/Retraction without Palpable Mass (BSCR-8)
- Nipple Discharge, No Palpable Symptom (BSCR-9)
- Skin Changes (BSCR-10)
- Persistent or Severe Breast Pain (BSCR-11)
- Axillary Mass(es) Suspected to Represent Adenopathy (BSCR-13)

Presentation of Signs/Symptoms in Individuals Assigned Male at Birth (BSCR-14)
Mammographic and/or Ultrasound Evaluation and Follow-up (BSCR-18)
Breast Screening Considerations (BSCR-A)
Management of Breast Cancer Screening and Breast Symptoms During Pregnancy or Lactation (BSCR-B)
Breast Imaging Assessment Category Definitions (BSCR-C)

Abbreviations (ABBR-1)

Find an NCCN Member Institution: https://www.nccn.org/home/member-institutions.

NCCN Categories of Evidence and Consensus: All recommendations are category 2A unless otherwise indicated.

See NCCN Categories of Evidence and Consensus.

The NCCN Guidelines® are a statement of evidence and consensus of the authors regarding their views of currently accepted approaches to treatment. Any clinician seeking to apply or consult the NCCN Guidelines is expected to use independent medical judgment in the context of individual clinical circumstances to determine any patient's care or treatment. The National Comprehensive Cancer Network® (NCCN®) makes no representations or warranties of any kind regarding their content, use or application and disclaims any responsibility for their application or use in any way. The NCCN Guidelines are copyrighted by National Comprehensive Cancer Network®. All rights reserved. The NCCN Guidelines and the illustrations herein may not be reproduced in any form without the express written permission of NCCN. ©2026.

PLEASE NOTE that use of this NCCN Content is governed by the End-User License Agreement, and you MAY NOT distribute this Content or use it with any artificial intelligence model or tool.
Printed by Ambrish Chauhan on 5/1/2026 7:03:18 AM. Copyright © 2026 National Comprehensive Cancer Network, Inc. All Rights Reserved.

Updates in Version 1.2026 of the NCCN Guidelines for Breast Cancer Screening and Diagnosis:

Global
- Presenting Signs/Symptoms modified, *Signs/Symptoms During Clinical Encounter*.
- References have been updated throughout the guideline.

BSCR-1
Increased risk:
Footnotes
- Column 3, new: For individuals who meet criteria for multiple increased-risk categories, the most comprehensive set of screening recommendations should be followed.
- Column 4, bullet 2, bullet 4 and bullet 8, new: Periodic reassessment of risk is recommended, particularly when risk factors change. (Also for BSCR-2, BSCR-4).
  - Removed: bullet 5 and bullet 6: ~~and ≥20% residual lifetime risk.~~
- Bullet 8, new: 5-year risk of invasive breast cancer ≥1.7% as calculated by an imaging-based risk assessment model.
  - Leading to Increased Risk Screening Follow-up (BSCR-4)
- Column 5, age ≥40, bullet 2: moved category 1 after mammogram.

BSCR-1A
Footnote
- i, modified: Risk models that include...first-, second-, and, when *included in* ~~relevant to~~ the model, third-degree relatives. (Also for BSCR-2).

BSCR-2
Footnotes
- New: In a recent direct comparison trial, MRI had a cancer detection rate (CDR) approximately 4 times higher than ultrasound in patients with dense breasts. See Discussion.
- t, modified: Including first-, second-, and, when *included in* ~~relevant to~~ the model, third-degree relatives.

BSCR-4
Increased Risk
- New: 5-year risk of invasive breast cancer ≥1.7% as calculated by an imaging-based risk assessment model.
- Modified: ADH or Lobular neoplasia (LCIS/ALH) ~~and ≥20% residual lifetime risk~~

Screening/Follow-Up
- Clinical encounter
  - To begin when identified as being at increased risk ~~by Gail Model~~
- Annual Screening mammogram with tomosynthesis
  - To begin when identified as being at increased risk ~~by Gail Model~~
- *Consider annual breast MRI with and without contrast.*
  - *Consider CEM or MBI for those who qualify for but cannot undergo MRI. Whole breast ultrasound may be done if CEM or MBI is not available.*

BSCR-5
Presenting Signs/Symptoms
- New bullet under Skin changes: *Skin ulcers.*

Continued
UPDATES

PLEASE NOTE that use of this NCCN Content is governed by the End-User License Agreement, and you MAY NOT distribute this Content or use it with any artificial intelligence model or tool.
Printed by Ambrish Chauhan on 5/1/2026 7:03:18 AM. Copyright © 2026 National Comprehensive Cancer Network, Inc. All Rights Reserved.

Updates in Version 1.2026 of the NCCN Guidelines for Breast Cancer Screening and Diagnosis include:

BSCR-5 (continued)
Footnotes
- dd, modified: For ~~symptomatic~~ individuals *with signs and symptoms*, clinical encounter should include, at a minimum, a review of medical and family history, ~~ongoing risk assessment (by age 25), risk reduction counseling,~~ and CBE. *Subsequent visits should include risk assessment (by age 25 years) and risk reduction counseling*.
- New: Attention to timely diagnostic follow-up after abnormal breast screening is recommended, as racial disparities have been observed in time to diagnostic imaging and/or biopsy following abnormal breast screening. See Discussion. (Also for BSCR-18).

BSCR-7
BI-RADS category 2 (benign)
- If clinically suspicious, modified: Appropriate clinical management ~~Palpation- or image-guided tissue sampling [by core needle biopsy (BSCR-15), fine-needle aspiration (FNA) (BSCR-17), or excision.~~

BSCR-8
- Last column, middle pathway modified: Mammographic and/or ultrasound evaluation *if BI-RADS category 3 assessed* (BSCR-18).

BSCR-10
- Column 2, modified last pathway to include: *Skin thickening and Skin discoloration.*
- Column, 6 modified: Abnormal clinic and MRI imaging findings broken into two categories, with abnormal clinical findings leading to biopsy of skin or nipple and abnormal MRI imaging findings leading to core needle biopsy. Core needle biopsy no longer listed as preferred given that it is now the only listed option for abnormal MRI imaging findings.

BSCR-11
Follow-Up Evaluations
- Column 3, No physical findings, top pathway, New bullet added under Reassurance: Symptomatic treatment of breast related pain if needed/desired, with the following footnotes: *Patients with non-breast related pain may be referred back to initial provider for management and See Discussion for further details on symptomatic management of breast pain.*

BSCR-15
Footnotes
- eeee, modified: For select patients with other specific histologies (eg, classic LCIS, ALH, flat epithelial atypia [FEA], papillomas without atypia, fibroepithelial lesions favoring fibroadenoma, radial scars adequately sampled *without atypia* ~~or incidental ADH~~) *routine* excision *is generally not required*. ~~may be considered depending on level of suspicion~~.
- New: In certain situations, at the discretion of the radiologist, repeat attempt at percutaneous sampling may be warranted.

BSCR-16
Footnote
- New: Complete excision with negative margins would typically be performed for non-classic LCIS. However, outcomes data regarding treatment of individuals with non-classic LCIS are limited, due in part to a paucity of histologic categorization of variants of LCIS.

Continued

Version 1.2026, 03/05/26 © 2026 National Comprehensive Cancer Network® (NCCN®), All rights reserved. NCCN Guidelines® and this illustration may not be reproduced in any form without the express written permission of NCCN.

PLEASE NOTE that use of this NCCN Content is governed by the End-User License Agreement, and you MAY NOT distribute this Content or use it with any artificial intelligence model or tool.
Printed by Ambrish Chauhan on 5/1/2026 7:03:18 AM. Copyright © 2026 National Comprehensive Cancer Network, Inc. All Rights Reserved.

Updates in Version 1.2026 of the NCCN Guidelines for Breast Cancer Screening and Diagnosis include:

BSCR-A, 1 of 3
General Considerations
- Bullet 2, modified: Individuals should undergo breast cancer risk assessment by age 25 years and be counseled regarding potential benefits, risks, and limitations of breast screening in the context of their risk stratification. *For individuals who meet criteria for multiple increased-risk categories, the most comprehensive set of screening recommendations should be followed.* ~~care should be as per the highest increased risk level.~~
- Bullet 6, new: Attention to timely diagnostic follow-up after abnormal breast screening is recommended, as racial disparities have been observed in time to diagnostic imaging and/or biopsy following abnormal breast screening. See Discussion.

Upper Age Limit for Screening
- Bullet 2, modified: Consider severe comorbid conditions limiting life expectancy (eg, ≤10 years) and whether therapeutic interventions would be appropriate and acceptable to the patient. *Periodic reassessment of risk is recommended, particularly when risk factors change.*

BSCR-A, 2 of 3
Supplemental Screening Modalities
- Bullet 6, modified: ~~Supplemental~~ *Limited data exist regarding the use of MBI for breast cancer screening; however,* screening MBI has similar sensitivity but improved specificity and recall rate compared to ultrasound in studies with individuals with dense breasts. However, MBI has a whole-body effective radiation dose higher than standard mammography.
- Bullet 7: ~~Limited data exist regarding~~ *Emerging data support* the use of CEM for breast cancer screening.In individuals at increased risk for breast cancer, CEM increases CDR compared to mammography alone. CEM carries the risk of iodinated contrast reactions.

BSCR-B, 1 through 8
- The pregnancy and lactation pages have been combined and extensively revised.

MS-1
- The discussion section has been updated to reflect the changes in the algorithm.

Version 1.2026, 03/05/26 © 2026 National Comprehensive Cancer Network® (NCCN®), All rights reserved. NCCN Guidelines® and this illustration may not be reproduced in any form without the express written permission of NCCN.

PLEASE NOTE that use of this NCCN Content is governed by the End-User License Agreement, and you MAY NOT distribute this Content or use it with any artificial intelligence model or tool.
Printed by Ambrish Chauhan on 5/1/2026 7:03:18 AM. Copyright © 2026 National Comprehensive Cancer Network, Inc. All Rights Reserved.

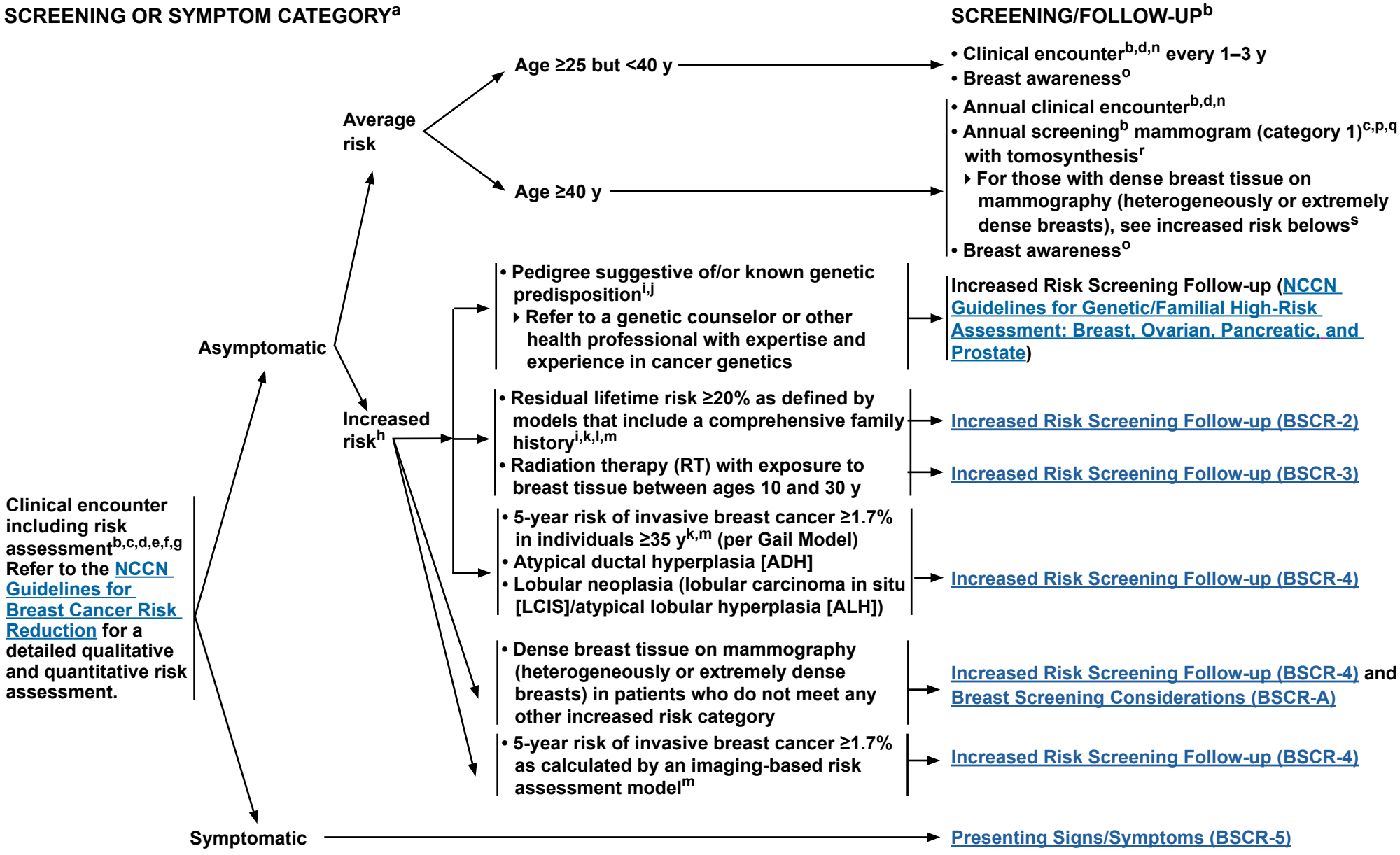

Note: All recommendations are category 2A unless otherwise indicated.

Footnotes on BSCR-1A

Version 1.2026, 03/05/26 © 2026 National Comprehensive Cancer Network® (NCCN®), All rights reserved. NCCN Guidelines® and this illustration may not be reproduced in any form without the express written permission of NCCN.

PLEASE NOTE that use of this NCCN Content is governed by the End-User License Agreement, and you MAY NOT distribute this Content or use it with any artificial intelligence model or tool.
Printed by Ambrish Chauhan on 5/1/2026 7:03:18 AM. Copyright © 2026 National Comprehensive Cancer Network, Inc. All Rights Reserved.

FOOTNOTES

[a] For individuals with a prior history of breast cancer, please refer to Surveillance/Follow-up in the NCCN Guidelines for Breast Cancer.
[b] Breast Screening Considerations (BSCR-A).
[c] Medicare and insurers allow the individual direct access to scheduling for screening mammography.
[d] At minimum, medical and family history should be reviewed and clinical encounter should encompass ongoing risk assessment (by age 25 years), risk reduction counseling, and preferably a clinical breast examination (CBE) even in individuals who are asymptomatic when feasible. Known breast density should be factored into risk assessment if available from a prior mammogram.
[e] There are limited data on screening in individuals assigned male at birth (AMAB) with increased risk for breast cancer. Consider screening for individuals AMAB on feminizing hormones.
[f] For pregnant and lactating individuals, see BSCR-B.
[g] Some veterans may now qualify for additional breast cancer risk assessment and/or mammography screening per the Dr. Kate Hendricks Thomas Supporting Expanded Review for Veterans in Combat Environments Act, also called the Dr. Kate Hendricks Thomas SERVICE Act 2022. Available at: https://www.congress.gov/117/plaws/publ133/PLAW-117publ133.pdf.
[h] For individuals who meet criteria for multiple increased-risk categories, the most comprehensive set of screening recommendations should be followed.
[i] Risk models that include a comprehensive family history, including first-, second-, and, when included in the model, third-degree relatives (eg, BRCAPRO, Tyrer-Cuzick, BOADICEA/CanRisk, Breast Cancer Surveillance Consortium (BCSC) Invasive Breast Cancer Risk Calculator). See NCCN Guidelines for Breast Cancer Risk Reduction and NCCN Guidelines for Genetic/Familial High-Risk Assessment: Breast, Ovarian, Pancreatic, and Prostate.
[j] There is variation in recommendations for initiation of screening for different genetic syndromes. See NCCN Guidelines for Genetic/Familial High-Risk Assessment: Breast, Ovarian, Pancreatic, and Prostate.
[k] See Comparison of Risk Assessment Models (NCCN Guidelines for Breast Cancer Risk Reduction).
[l] Individuals with a residual lifetime risk of 15%–20% may be considered for supplemental screening on an individual basis, depending on risk factors.
[m] Periodic reassessment of risk is recommended, particularly when risk factors change.
[n] Rationale for recommending clinical encounter is to maximize earliest detection of breast cancers and assure ongoing risk assessment, particularly in regions where mammographic screening may not be accessible. Randomized trials comparing incremental CBE versus mammographic screening have not been performed.
[o] Individuals should be familiar with their breasts and promptly report changes to their health care provider. See Signs/Symptoms During Clinical Encounter (BSCR-5).
[p] See Mammographic and/or ultrasound evaluation (BSCR-18).
[q] Shared decision-making is encouraged based on individuals' values and preferences.
[r] Tomosynthesis can decrease call-back rates and improve cancer detection compared with two-dimensional (2D) mammography alone.
[s] In patients with extremely dense breasts and normal mammograms, supplemental screening with breast MRI decreases interval cancers. In a prospective study, those randomized to breast MRI after a negative screening mammogram had significantly fewer interval breast cancers compared to those who did not have supplemental screening (category 1 for ages 50–75 y). The ideal frequency of supplemental screening MRI in this patient population is not yet known. See Discussion.

Note: All recommendations are category 2A unless otherwise indicated.

Version 1.2026, 03/05/26 © 2026 National Comprehensive Cancer Network® (NCCN®), All rights reserved. NCCN Guidelines® and this illustration may not be reproduced in any form without the express written permission of NCCN.

PLEASE NOTE that use of this NCCN Content is governed by the End-User License Agreement, and you MAY NOT distribute this Content or use it with any artificial intelligence model or tool.
Printed by Ambrish Chauhan on 5/1/2026 7:03:18 AM. Copyright © 2026 National Comprehensive Cancer Network, Inc. All Rights Reserved.

SCREENING OR SYMPTOM CATEGORY[a]	SCREENING/FOLLOW-UP[b]
Increased Risk:	
Residual lifetime risk ≥20% as defined by models that include a comprehensive family history[i,k,l,m] →	**• Clinical encounter[b,d,n] every 6–12 mo** **▸ To begin when identified as being at increased risk** **▸ Consider referral to a genetic counselor or other health professional with expertise and experience in cancer genetics, if not already done** **▸ Consider referral to a breast specialist as appropriate** **• Annual screening[b] mammogram[c,p] with tomosynthesis[r]** **▸ To begin no later than age 40 y, or 10 y prior to when the youngest family member[t] was diagnosed with breast cancer, not prior to age 30 y[u] (whichever comes first)** **• Annual breast MRI[b,v,w] with and without contrast** **▸ To begin no later than age 40 y, or 10 years prior to when the youngest family member[t] was diagnosed with breast cancer, not prior to age 25 y[x,y] (whichever comes first)** **▸ Consider contrast-enhanced mammography (CEM)[b] or molecular breast imaging (MBI)[b] for those who qualify for but cannot undergo MRI. Whole breast ultrasound[b] may be done if CEM or MBI is not available/accessible[z]** **• Consider risk reduction strategies (see NCCN Guidelines for Breast Cancer Risk Reduction)** **• Breast awareness[o]**

[a] For individuals with a prior history of breast cancer, please refer to Surveillance/Follow-up in the NCCN Guidelines for Breast Cancer.
[b] Breast Screening Considerations (BSCR-A).
[c] Medicare and insurers allow the individual direct access to scheduling for screening mammography.
[d] At minimum, medical and family history should be reviewed and clinical encounter should encompass ongoing risk assessment (by age 25 years), risk reduction counseling, and preferably a CBE even in individuals who are asymptomatic when feasible. Known breast density should be factored into risk assessment if available from a prior mammogram.
[i] Risk models that include a comprehensive family history, including first-, second-, and, when included in the model, third-degree relatives (eg, BRCAPRO, Tyrer-Cuzick, BOADICEA/CanRisk, BCSC Invasive Breast Cancer Risk Calculator). See NCCN Guidelines for Breast Cancer Risk Reduction and NCCN Guidelines for Genetic/Familial High-Risk Assessment: Breast, Ovarian, Pancreatic, and Prostate.
[k] See Comparison of Risk Assessment Models (NCCN Guidelines for Breast Cancer Risk Reduction).
[l] Individuals with a residual lifetime risk of 15%–20% may be considered for supplemental screening on an individual basis, depending on risk factors.
[m] Periodic reassessment of risk is recommended, particularly when risk factors change.
[n] Rationale for recommending clinical encounter is to maximize earliest detection of breast cancers and assure ongoing risk assessment, particularly in regions where mammographic screening may not be accessible. Randomized trials comparing incremental CBE versus mammographic screening have not been performed.
[o] Individuals should be familiar with their breasts and promptly report changes to their health care provider. See Signs/Symptoms During Clinical Encounter (BSCR-5).
[p] See Mammographic and/or ultrasound evaluation (BSCR-18).
[r] Tomosynthesis can decrease call-back rates and improve cancer detection compared with 2D mammography alone.
[t] Including first-, second-, and, when included in the model, third-degree relatives.
[u] Consider mammogram beginning at age 25 years on a case-by-case basis depending on family history or for patients who cannot undergo breast MRI.
[v] High-quality breast MRI requires a dedicated breast coil, access to biopsy under MRI guidance, experienced radiologists in breast MRI, and regional availability. MRI should be correlated with other breast imaging modalities.
[w] Many experts recommend alternating the mammogram and breast MRI with and without contrast every 6 months. While there are limited data to support this approach, the presumption is that this may lead to earlier identification of cancer.
[x] Except in rare circumstances of a family history of very-early-onset breast cancers before age 30 years.
[y] Of note, some individuals at increased risk of breast cancer may undergo breast MRI prior to qualifying for screening mammogram.
[z] In a recent direct comparison trial, MRI had a cancer detection rate (CDR) approximately 4 times higher than ultrasound in patients with dense breasts. See Discussion.

Note: All recommendations are category 2A unless otherwise indicated.

Version 1.2026, 03/05/26 © 2026 National Comprehensive Cancer Network® (NCCN®), All rights reserved. NCCN Guidelines® and this illustration may not be reproduced in any form without the express written permission of NCCN.

PLEASE NOTE that use of this NCCN Content is governed by the End-User License Agreement, and you MAY NOT distribute this Content or use it with any artificial intelligence model or tool.
Printed by Ambrish Chauhan on 5/1/2026 7:03:18 AM. Copyright © 2026 National Comprehensive Cancer Network, Inc. All Rights Reserved.

SCREENING OR SYMPTOM CATEGORY[a] SCREENING/FOLLOW-UP[b]

Increased Risk:

RT with exposure to breast tissue between ages 10 and 30 y[aa]

Current age <25 y →
- **Annual clinical encounter[b,d,n]**
  - **Begin 8 y after RT**
- **Breast awareness[o]**

Current age ≥25 y →
- **Clinical encounter[b,d,n] every 6–12 mo**
  - **Begin 8 y after RT**
- **Annual screening[b] mammogram[c,p] with tomosynthesis[r]**
  - **Begin 8 y after RT but not prior to age 25 y**
- **Annual breast MRI[b,v,w] with and without contrast**
  - **Consider CEM[b] or MBI[b] for those who qualify for but cannot undergo MRI. Whole breast ultrasound[b] may be done if CEM or MBI is not available/accessible**
  - **Begin 8 y after RT but not prior to age 25 y**
- **Consider risk reduction strategies (see NCCN Guidelines for Breast Cancer Risk Reduction)**
- **Breast awareness[o]**

[a] For individuals with a prior history of breast cancer, please refer to Surveillance/Follow-up in the NCCN Guidelines for Breast Cancer.
[b] Breast Screening Considerations (BSCR-A).
[c] Medicare and insurers allow the individual direct access to scheduling for screening mammography.
[d] At minimum, medical and family history should be reviewed and clinical encounter should encompass ongoing risk assessment (by age 25 years), risk reduction counseling, and preferably a CBE even in individuals who are asymptomatic when feasible. Known breast density should be factored into risk assessment if available from a prior mammogram.
[n] Rationale for recommending clinical encounter is to maximize earliest detection of breast cancers and assure ongoing risk assessment, particularly in regions where mammographic screening may not be accessible. Randomized trials comparing incremental CBE versus mammographic screening have not been performed.
[o] Individuals should be familiar with their breasts and promptly report changes to their health care provider. See Signs/Symptoms During Clinical Encounter (BSCR-5).
[p] See Mammographic and/or ultrasound evaluation (BSCR-18).
[r] Tomosynthesis can decrease call-back rates and improve cancer detection compared with 2D mammography alone.
[v] High-quality breast MRI requires a dedicated breast coil, access to biopsy under MRI guidance, experienced radiologists in breast MRI, and regional availability. MRI should be correlated with other breast imaging modalities.
[w] Many experts recommend alternating the mammogram and breast MRI with and without contrast every 6 months. While there are limited data to support this approach, the presumption is that this may lead to earlier identification of cancer.
[aa] Consider screening on a case-by-case basis for those who received RT with exposure to breast tissue outside of this age range. While screening mammography would not be done prior to age 25 years, breast MRI may be considered.

Note: All recommendations are category 2A unless otherwise indicated.

Version 1.2026, 03/05/26 © 2026 National Comprehensive Cancer Network® (NCCN®), All rights reserved. NCCN Guidelines® and this illustration may not be reproduced in any form without the express written permission of NCCN.

PLEASE NOTE that use of this NCCN Content is governed by the End-User License Agreement, and you MAY NOT distribute this Content or use it with any artificial intelligence model or tool.
Printed by Ambrish Chauhan on 5/1/2026 7:03:18 AM. Copyright © 2026 National Comprehensive Cancer Network, Inc. All Rights Reserved.

SCREENING OR SYMPTOM CATEGORY[a]	SCREENING/FOLLOW-UP[b]
Increased Risk: 5-year risk of invasive breast cancer ≥1.7% in individuals ≥35 y (per Gail Model)[k,m] 5-year risk of invasive breast cancer ≥1.7% as calculated by an imaging-based risk assessment model[m]	• Clinical encounter[b,d,n] every 6–12 mo ▸ To begin when identified as being at increased risk • Annual screening[b] mammogram[c,p] with tomosynthesis[r] ▸ To begin when identified as being at increased risk • Consider risk reduction strategies (see NCCN Guidelines for Breast Cancer Risk Reduction) • Breast awareness[o] • Consider annual breast MRI[b,v,w] with and without contrast ▸ Consider CEM[b] or MBI[b] for those who qualify for but cannot undergo MRI. Whole breast ultrasound[b] may be done if CEM or MBI is not available
ADH[bb] or Lobular neoplasia (LCIS/ALH)	• Clinical encounter[b,d,n] every 6–12 mo ▸ To begin at diagnosis of ADH or lobular neoplasia (LCIS/ALH) • Annual screening[b] mammogram[c,p] with tomosynthesis[r] ▸ To begin at diagnosis of ADH or lobular neoplasia (LCIS/ALH) but not prior to age 30 y • Consider annual breast MRI[b,v,w] with and without contrast ▸ Consider CEM[b] or MBI[b] for those who qualify for but cannot undergo MRI. Whole breast ultrasound[b] may be done if CEM or MBI is not available ▸ To begin at diagnosis of ADH or lobular neoplasia (LCIS/ALH) but not prior to age 25 y • Consider risk reduction strategies (see NCCN Guidelines for Breast Cancer Risk Reduction) • Breast awareness[o]
Dense breast tissue on mammography in patients who do not meet any other increased risk category → Heterogenously dense breasts	• Clinical encounter[b,d,n] every 6–12 mo ▸ To begin when identified on mammography • Annual screening[b] mammogram[c,p] with tomosynthesis[r] ▸ To begin no later than age 40 but not prior to age 30 y • Consider supplemental screening (BSCR-A) • Consider risk reduction strategies (see NCCN Guidelines for Breast Cancer Risk Reduction) • Breast awareness[o]
Dense breast tissue on mammography in patients who do not meet any other increased risk category → Extremely dense breasts	• Clinical encounter[b,d,n] every 6–12 mo ▸ To begin when identified on mammography • Annual screening[b] mammogram[c,p] with tomosynthesis[r] ▸ To begin no later than age 40 y but not prior to age 30 y • Breast MRI[b,v,w] with and without contrast[s] ▸ To begin at age 50 but can consider starting at age 40 y • Consider CEM[b] or MBI[b] for those who qualify for but cannot undergo MRI. Whole breast ultrasound[b] may be done if CEM or MBI is not available • Consider risk reduction strategies (see NCCN Guidelines for Breast Cancer Risk Reduction) • Breast awareness[o]

Footnotes on BSCR-4A

Note: All recommendations are category 2A unless otherwise indicated.

Version 1.2026, 03/05/26 © 2026 National Comprehensive Cancer Network® (NCCN®), All rights reserved. NCCN Guidelines® and this illustration may not be reproduced in any form without the express written permission of NCCN.

PLEASE NOTE that use of this NCCN Content is governed by the End-User License Agreement, and you MAY NOT distribute this Content or use it with any artificial intelligence model or tool.
Printed by Ambrish Chauhan on 5/1/2026 7:03:18 AM. Copyright © 2026 National Comprehensive Cancer Network, Inc. All Rights Reserved.

FOOTNOTES

[a] For individuals with a prior history of breast cancer, please refer to Surveillance/Follow-up in the NCCN Guidelines for Breast Cancer.
[b] Breast Screening Considerations (BSCR-A).
[c] Medicare and insurers allow the individual direct access to scheduling for screening mammography.
[d] At minimum, medical and family history should be reviewed and clinical encounter should encompass ongoing risk assessment (by age 25 years), risk reduction counseling, and preferably a CBE even in individuals who are asymptomatic when feasible. Known breast density should be factored into risk assessment if available from a prior mammogram.
[k] See Comparison of Risk Assessment Models (NCCN Guidelines for Breast Cancer Risk Reduction).
[m] Periodic reassessment of risk is recommended, particularly when risk factors change.
[n] Rationale for recommending clinical encounter is to maximize earliest detection of breast cancers and assure ongoing risk assessment, particularly in regions where mammographic screening may not be accessible. Randomized trials comparing incremental CBE versus mammographic screening have not been performed.
[o] Individuals should be familiar with their breasts and promptly report changes to their health care provider. See Signs/Symptoms During Clinical Encounter (BSCR-5).
[p] See Mammographic and/or ultrasound evaluation (BSCR-18).
[r] Tomosynthesis can decrease call-back rates and improve cancer detection compared with 2D mammography alone.
[s] In patients with extremely dense breasts and normal mammograms, supplemental screening with breast MRI decreases interval cancers. In a prospective study, those randomized to breast MRI after a negative screening mammogram had significantly fewer interval breast cancers compared to those who did not have supplemental screening (category 1 for ages 50–75 y). See Discussion. The ideal frequency of supplemental screening MRI in this patient population is not yet known.
[v] High-quality breast MRI requires a dedicated breast coil, access to biopsy under MRI guidance, experienced radiologists in breast MRI, and regional availability. MRI should be correlated with other breast imaging modalities.
[w] Many experts recommend alternating the mammogram and breast MRI with and without contrast every 6 months. While there are limited data to support this approach, the presumption is that this may lead to earlier identification of cancer.
[bb] Risk depends on age at diagnosis.

Note: All recommendations are category 2A unless otherwise indicated.

Version 1.2026, 03/05/26 © 2026 National Comprehensive Cancer Network® (NCCN®), All rights reserved. NCCN Guidelines® and this illustration may not be reproduced in any form without the express written permission of NCCN.

PLEASE NOTE that use of this NCCN Content is governed by the End-User License Agreement, and you MAY NOT distribute this Content or use it with any artificial intelligence model or tool.
Printed by Ambrish Chauhan on 5/1/2026 7:03:18 AM. Copyright © 2026 National Comprehensive Cancer Network, Inc. All Rights Reserved.

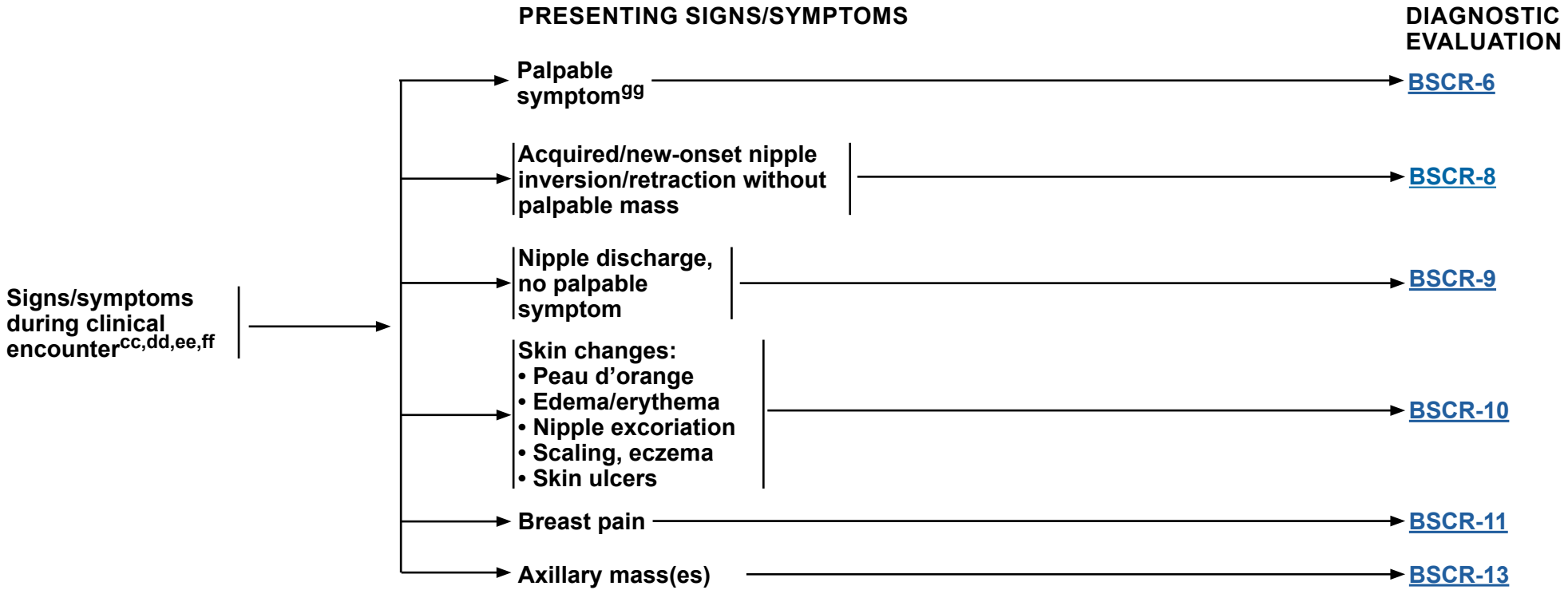

[cc] For management of signs/symptoms in individuals AMAB, see BSCR-14.

[dd] For individuals with signs and symptoms, clinical encounter should include, at a minimum, a review of medical and family history, and CBE. Subsequent visits should include risk assessment (by age 25 years) and risk reduction counseling. Known breast density should be factored into risk assessment if available from a prior mammogram.

[ee] Individuals with breast implants have a very small risk of developing breast implant-associated anaplastic large cell lymphoma (BIA-ALCL) (average 7–9 years after implantation) and breast implant-associated squamous cell carcinoma (BIA-SCC). The majority of cases of BIA-ALCL have been seen in textured implants, while BIA-SCC is associated with either smooth or textured implants. For breast-implant–related symptoms occurring >1 year post-implantation that are concerning for BIA-ALCL (effusion, enlargement, mass) or BIA-SCC (ulceration), consultation with a multidisciplinary team with experience in managing these disorders is recommended. For BIA-ALCL, also see NCCN Guidelines for T-Cell Lymphomas.

[ff] Attention to timely diagnostic follow-up after abnormal breast screening is recommended, as racial disparities have been observed in time to diagnostic imaging and/or biopsy following abnormal breast screening. See Discussion.

[gg] Including mass, new-onset asymmetric thickening/nodularity, asymmetric breast enlargement, or change in shape/contour (which may be due to implant rupture). See https://www.fda.gov/media/131885/download and BSCR-6.

Note: All recommendations are category 2A unless otherwise indicated.

Version 1.2026, 03/05/26 © 2026 National Comprehensive Cancer Network® (NCCN®), All rights reserved. NCCN Guidelines® and this illustration may not be reproduced in any form without the express written permission of NCCN.

PLEASE NOTE that use of this NCCN Content is governed by the End-User License Agreement, and you MAY NOT distribute this Content or use it with any artificial intelligence model or tool.
Printed by Ambrish Chauhan on 5/1/2026 7:03:18 AM. Copyright © 2026 National Comprehensive Cancer Network, Inc. All Rights Reserved.

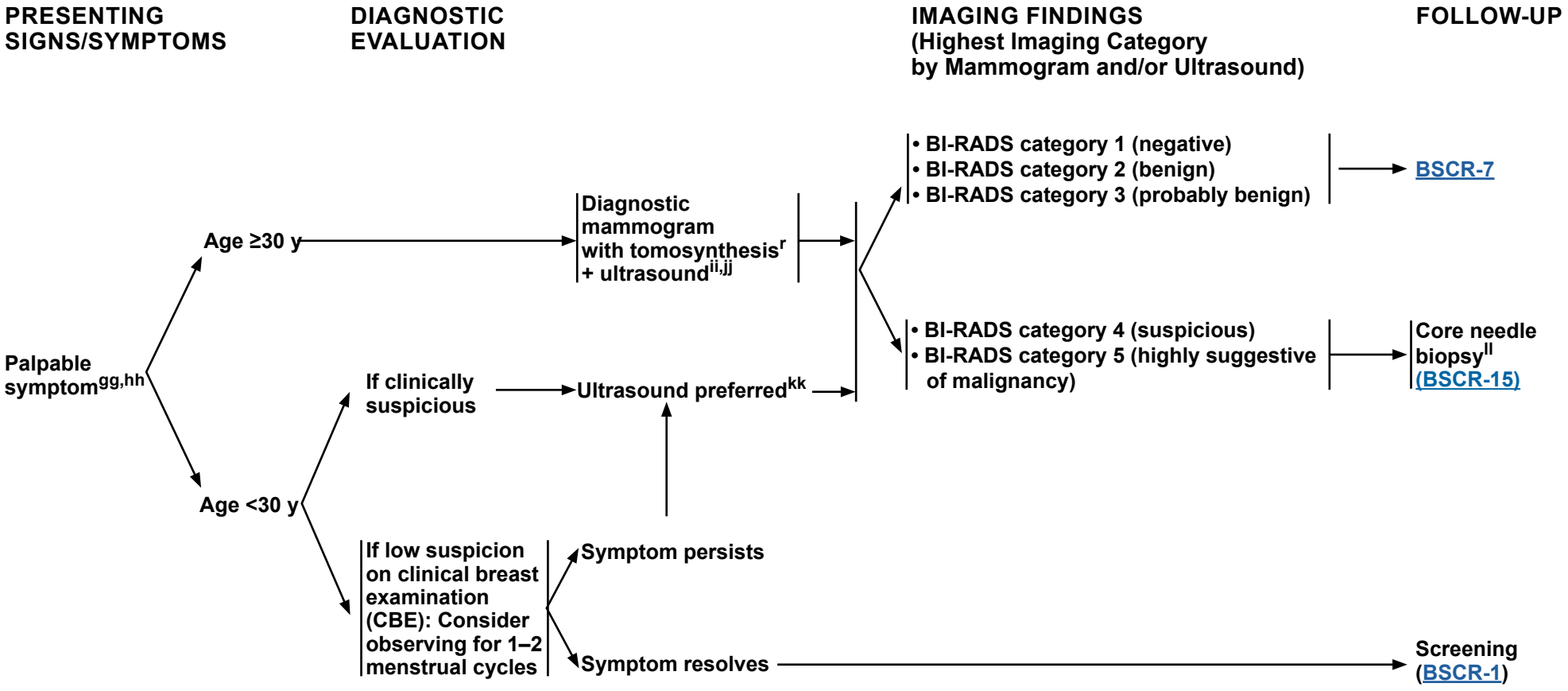

[r] Tomosynthesis can decrease call-back rates and improve cancer detection compared with 2D mammography alone.
[gg] Including mass, new-onset asymmetric thickening/nodularity, asymmetric breast enlargement, or change in shape/contour (which may be due to implant rupture). See https://www.fda.gov/media/131885/download.
[hh] It is critical for the location of physical findings from CBE to be documented, as clock/quadrant location and distance from nipple to facilitate geographic correlation with imaging findings.
[ii] Ultrasound may not be necessary for a palpable finding with a definitively benign finding (eg, calcified fat necrosis) on mammogram.
[jj] CEM in combination with ultrasound may be used as an alternative if available.
[kk] If high suspicion for malignancy by ultrasound, obtain diagnostic mammogram.
[ll] Confirm geographic correlation between clinical and imaging findings.

Note: All recommendations are category 2A unless otherwise indicated.

Version 1.2026, 03/05/26 © 2026 National Comprehensive Cancer Network® (NCCN®), All rights reserved. NCCN Guidelines® and this illustration may not be reproduced in any form without the express written permission of NCCN.

PLEASE NOTE that use of this NCCN Content is governed by the End-User License Agreement, and you MAY NOT distribute this Content or use it with any artificial intelligence model or tool.
Printed by Ambrish Chauhan on 5/1/2026 7:03:18 AM. Copyright © 2026 National Comprehensive Cancer Network, Inc. All Rights Reserved.

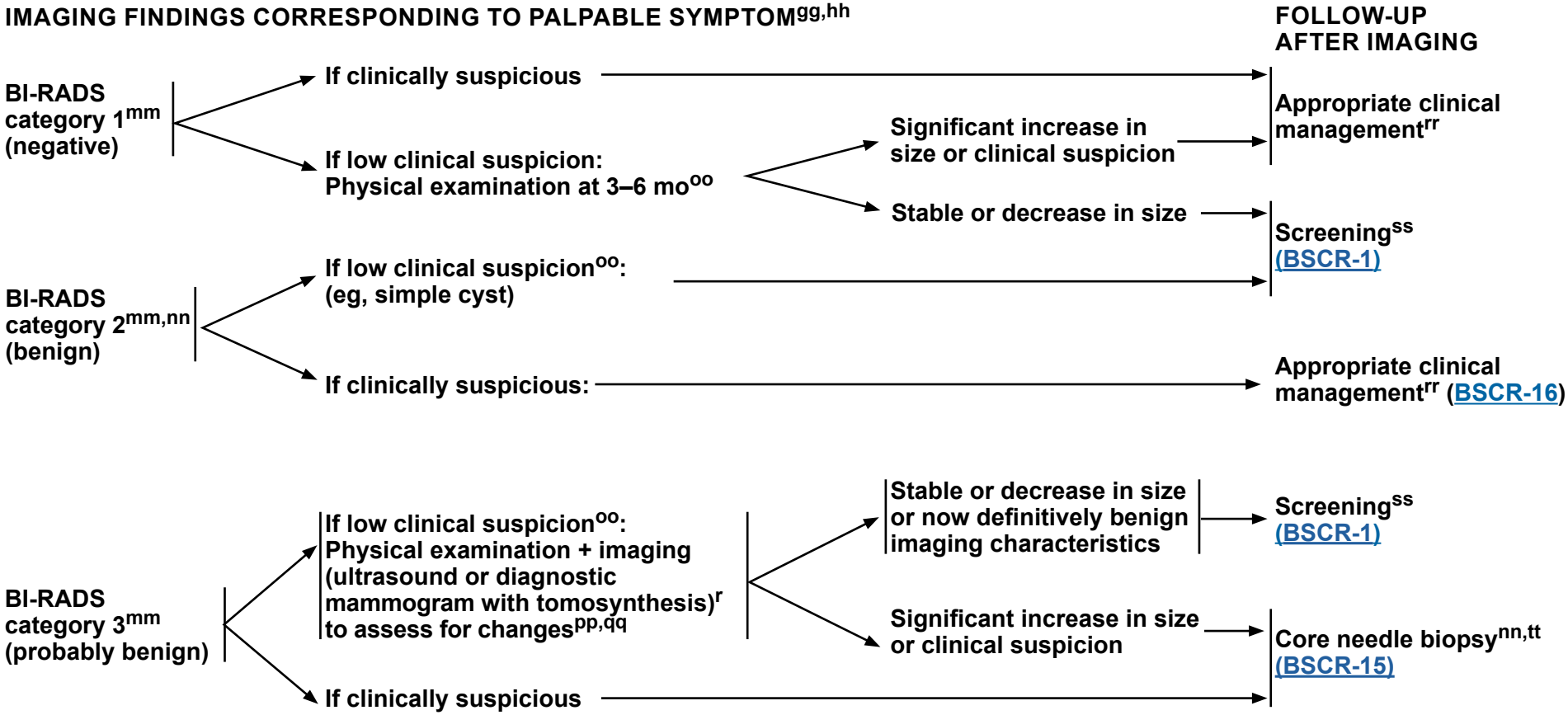

[r] Tomosynthesis can decrease call-back rates and improve cancer detection compared with 2D mammography alone.
[gg] Including mass, new-onset asymmetric thickening/nodularity, asymmetric breast enlargement, or change in shape/contour (which may be due to implant rupture). See https://www.fda.gov/media/131885/download and BSCR-6.
[hh] It is critical for the location of physical findings from CBE to be documented, as clock/quadrant location and distance from nipple to facilitate geographic correlation with imaging findings.
[mm] Assessment Category Definitions (BSCR-C).
[nn] Aspiration may be considered for symptomatic relief or possible abscess (BSCR-17).
[oo] Patients should be instructed to monitor for and report any changes.
[pp] Imaging modality would depend on original imaging. Probably benign findings are typically monitored at 6, 12, and 24 months.
[qq] If a return visit is uncertain or there is strong patient preference, may include biopsy.
[rr] Referral to a breast specialist, supplemental imaging, and/or tissue sampling.
[ss] Continue regular screening with age-appropriate imaging modality.
[tt] Core needle biopsy preferred; in some circumstances needle aspiration may be sufficient.

Note: All recommendations are category 2A unless otherwise indicated.

Version 1.2026, 03/05/26 © 2026 National Comprehensive Cancer Network® (NCCN®), All rights reserved. NCCN Guidelines® and this illustration may not be reproduced in any form without the express written permission of NCCN.

PLEASE NOTE that use of this NCCN Content is governed by the End-User License Agreement, and you MAY NOT distribute this Content or use it with any artificial intelligence model or tool.
Printed by Ambrish Chauhan on 5/1/2026 7:03:18 AM. Copyright © 2026 National Comprehensive Cancer Network, Inc. All Rights Reserved.

MANAGEMENT OF NIPPLE INVERSION/RETRACTION WITHOUT PALPABLE MASS

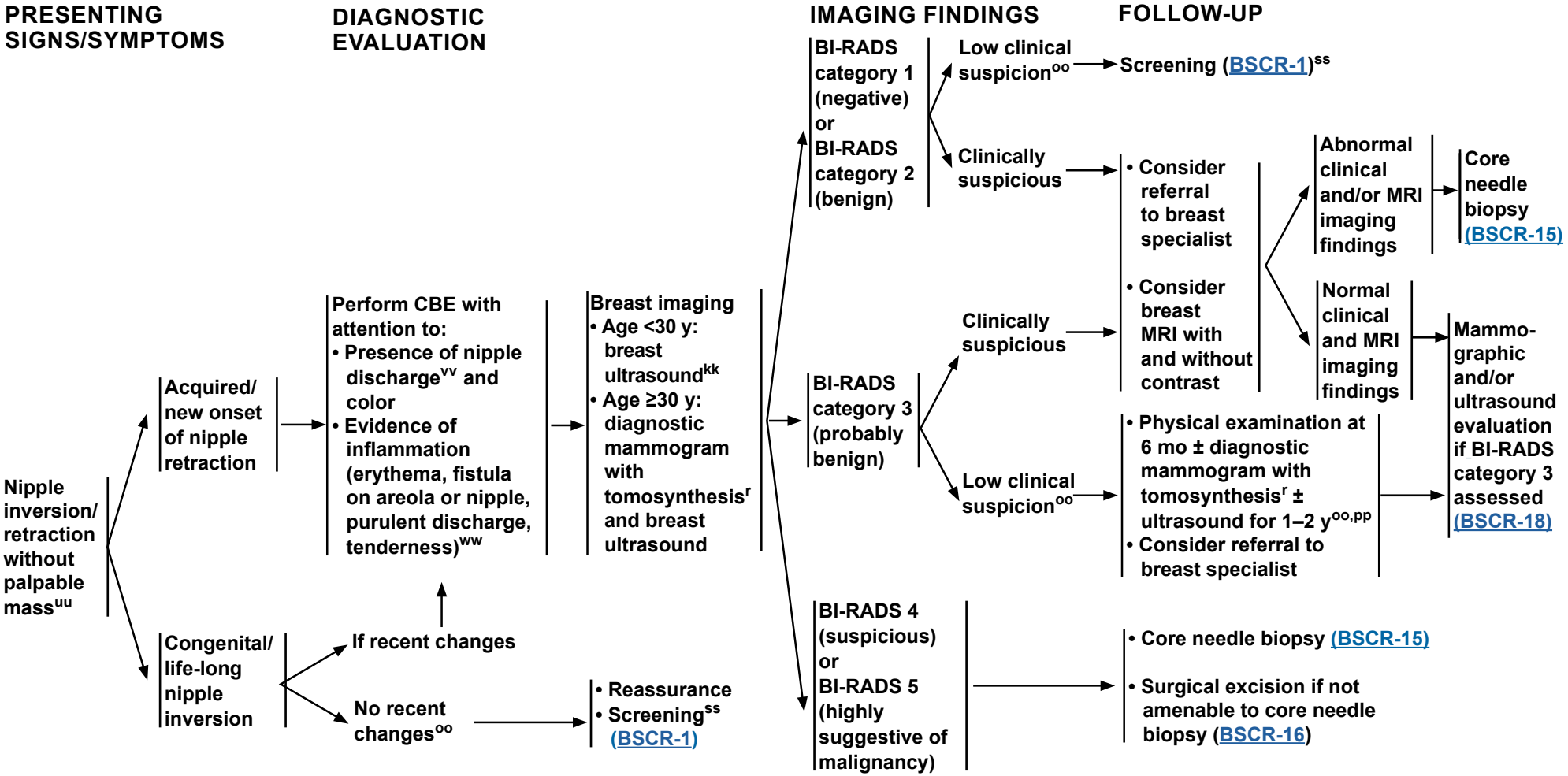

[r] Tomosynthesis can decrease call-back rates and improve cancer detection compared with 2D mammography alone.
[kk] If high suspicion for malignancy by ultrasound, obtain diagnostic mammogram.
[oo] Patients should be instructed to monitor for and report any changes.
[pp] Imaging modality would depend on original imaging. Probably benign findings are typically monitored at 6, 12, and 24 months.
[ss] Continue regular screening with age-appropriate imaging modality.
[uu] For palpable mass, see BSCR-6.
[vv] If nipple discharge is present, see also BSCR-9.
[ww] For evidence of inflammation, see also BSCR-10.

Note: All recommendations are category 2A unless otherwise indicated.

Version 1.2026, 03/05/26 © 2026 National Comprehensive Cancer Network® (NCCN®), All rights reserved. NCCN Guidelines® and this illustration may not be reproduced in any form without the express written permission of NCCN.

PLEASE NOTE that use of this NCCN Content is governed by the End-User License Agreement, and you MAY NOT distribute this Content or use it with any artificial intelligence model or tool.
Printed by Ambrish Chauhan on 5/1/2026 7:03:18 AM. Copyright © 2026 National Comprehensive Cancer Network, Inc. All Rights Reserved.

NCCN Guidelines Version 1.2026
Breast Cancer Screening and Diagnosis

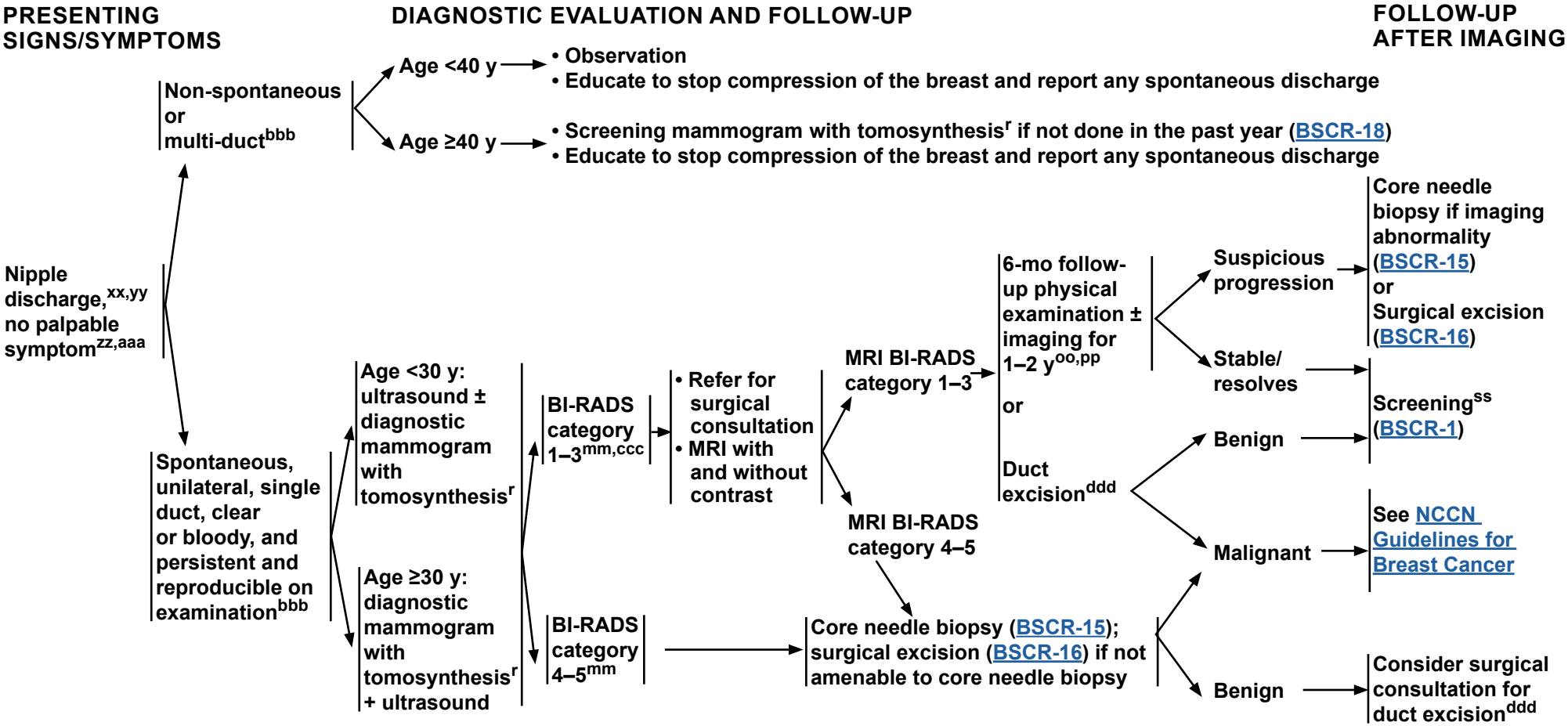

[r] Tomosynthesis can decrease call-back rates and improve cancer detection compared with 2D mammography alone.
[mm] Assessment Category Definitions (BSCR-C).
[oo] Patients should be instructed to monitor for and report any changes.
[pp] Imaging modality would depend on original imaging. Probably benign findings are typically monitored at 6, 12, and 24 months.
[ss] Continue regular screening with age-appropriate imaging modality.
[xx] A list of drugs that can cause nipple discharge (not all-inclusive): psychoactive drugs, antihypertensive medications, opiates, oral contraceptives, and estrogen.
[yy] For bilateral milky discharge consider endocrine workup.
[zz] If palpable symptom, see BSCR-6.
[aaa] Nipple smear cytology and ductography are not routinely recommended.
[bbb] Spontaneous multi-duct discharge that is milky may be due to pregnancy, and if not, should be evaluated for galactorrhea. Greenish, coffee-colored, yellow, brown/black multi-duct discharge is nearly always non-neoplastic, and reassurance can be provided. However, if the discharge is bothersome to the patient, referral to a breast specialist may be considered.
[ccc] If BI-RADS category 3 finding is unrelated to nipple discharge, manage mammographic finding by BSCR-18.
[ddd] Based on clinical suspicion and patient preference.

Note: All recommendations are category 2A unless otherwise indicated.

Version 1.2026, 03/05/26 © 2026 National Comprehensive Cancer Network® (NCCN®), All rights reserved. NCCN Guidelines® and this illustration may not be reproduced in any form without the express written permission of NCCN.

PLEASE NOTE that use of this NCCN Content is governed by the End-User License Agreement, and you MAY NOT distribute this Content or use it with any artificial intelligence model or tool.
Printed by Ambrish Chauhan on 5/1/2026 7:03:18 AM. Copyright © 2026 National Comprehensive Cancer Network, Inc. All Rights Reserved.

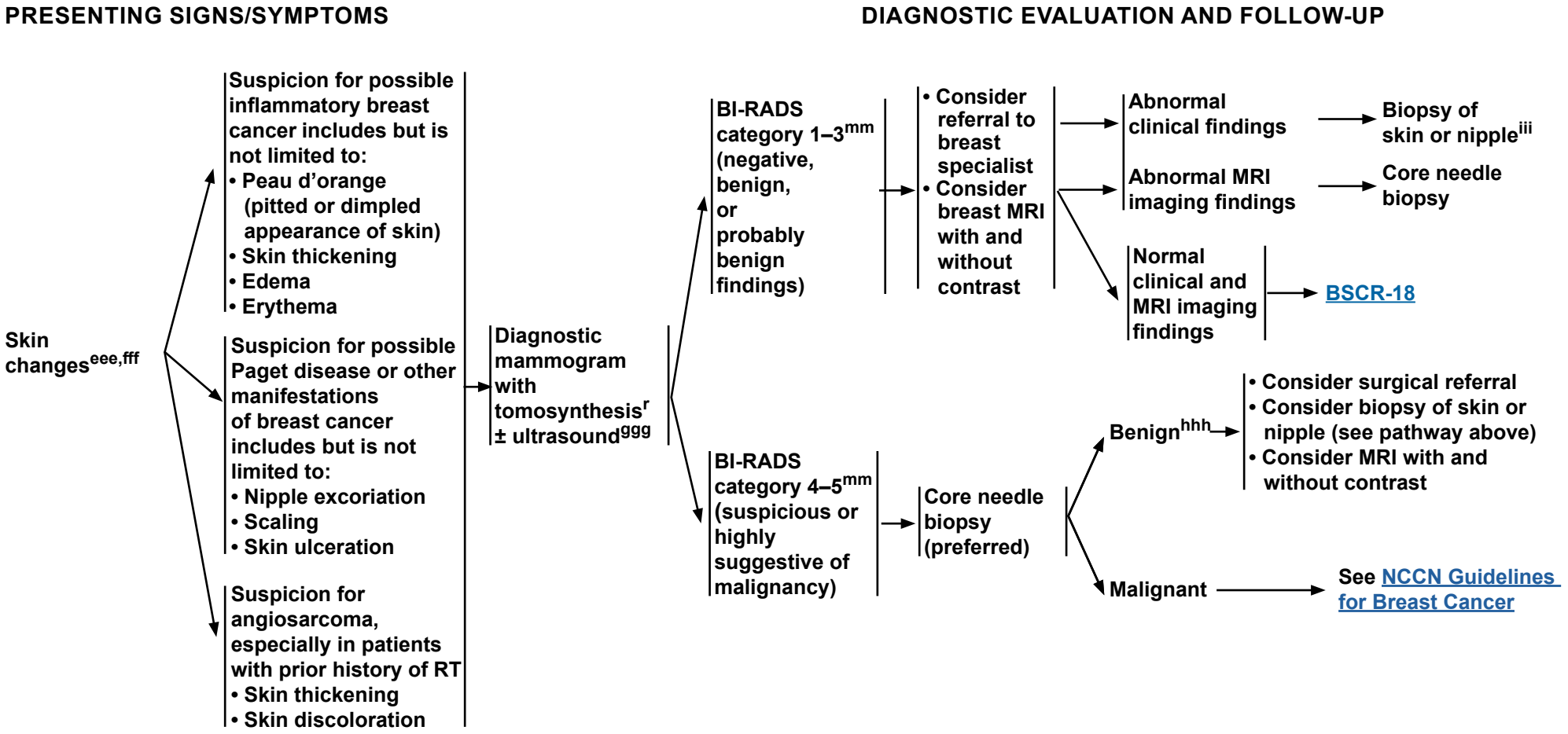

[r] Tomosynthesis can decrease call-back rates and improve cancer detection compared with 2D mammography alone.
[mm] Assessment Category Definitions (BSCR-C).
[eee] If clinically low suspicion for breast cancer or high suspicion for infection, a short trial (eg, 7–10 days) of antibiotics for mastitis, with short-term clinical follow-up after completion of antibiotics to assess for improvement/resolution, may be indicated. If not improved/resolved, continue with the workup recommended for skin changes.
[fff] If clinically low suspicion for Paget disease or high suspicion for eczema, a short trial of topical steroids, with clinical follow-up in 1–4 weeks to assess for improvement/resolution, may be indicated. If not improved/resolved, continue with the workup recommended for skin changes.
[ggg] CEM may be considered if available when clinically suspicious.
[hhh] A benign skin punch biopsy in a patient with a clinical suspicion of inflammatory breast cancer does not rule out malignancy. Further evaluation is recommended.
[iii] Inflammatory breast cancer is a clinical diagnosis and is not dependent on a positive punch biopsy.

Note: All recommendations are category 2A unless otherwise indicated.

Version 1.2026, 03/05/26 © 2026 National Comprehensive Cancer Network® (NCCN®), All rights reserved. NCCN Guidelines® and this illustration may not be reproduced in any form without the express written permission of NCCN.

PLEASE NOTE that use of this NCCN Content is governed by the End-User License Agreement, and you MAY NOT distribute this Content or use it with any artificial intelligence model or tool.
Printed by Ambrish Chauhan on 5/1/2026 7:03:18 AM. Copyright © 2026 National Comprehensive Cancer Network, Inc. All Rights Reserved.

PRESENTING SIGNS AND SYMPTOMS | **FOLLOW-UP EVALUATION**

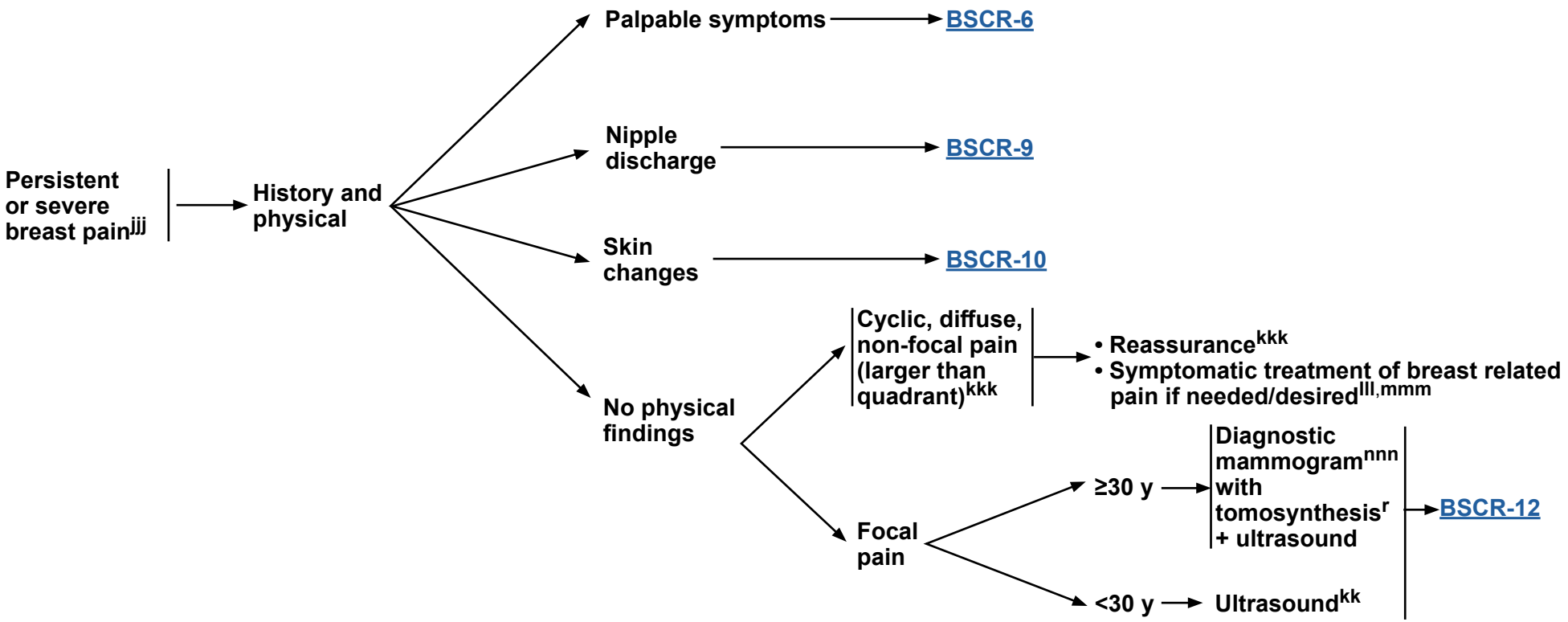

[r] Tomosynthesis can decrease call-back rates and improve cancer detection compared with 2D mammography alone.
[kk] If high suspicion for malignancy by ultrasound, obtain diagnostic mammogram.
[jjj] Defined as a minimum of 4–6 weeks duration; prior to that, symptomatic management unless patient reports other symptoms also present such as associated redness or mass. If other symptoms present, physical examination should be done at that time.
[kkk] Ensure that mammographic screening is up-to-date.
[lll] Patients with non-breast related pain may be referred back to the initial provider for management.
[mmm] See Discussion for further details on symptomatic management of breast pain.
[nnn] There are some clinical circumstances such as a suspected painful simple cyst in which ultrasound would be preferred as the first imaging modality and may suffice for individuals aged 30–39 years. Mammogram may not be necessary if performed and results were negative within the past 6 months. See Discussion.

Note: All recommendations are category 2A unless otherwise indicated.

Version 1.2026, 03/05/26 © 2026 National Comprehensive Cancer Network® (NCCN®), All rights reserved. NCCN Guidelines® and this illustration may not be reproduced in any form without the express written permission of NCCN.

PLEASE NOTE that use of this NCCN Content is governed by the End-User License Agreement, and you MAY NOT distribute this Content or use it with any artificial intelligence model or tool.
Printed by Ambrish Chauhan on 5/1/2026 7:03:18 AM. Copyright © 2026 National Comprehensive Cancer Network, Inc. All Rights Reserved.

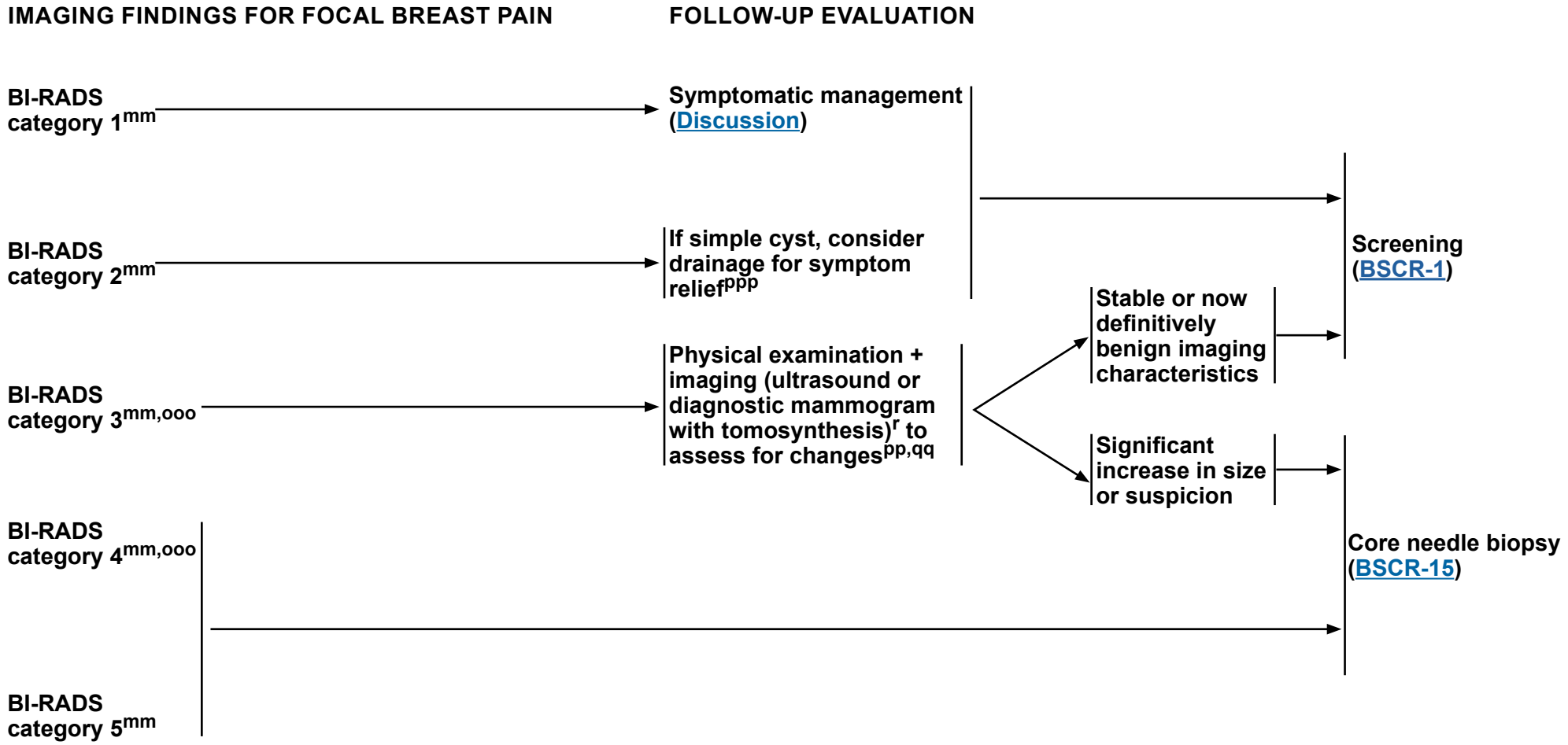

[r] Tomosynthesis can decrease call-back rates and improve cancer detection compared with 2D mammography alone.
[mm] Assessment Category Definitions (BSCR-C).
[pp] Imaging modality would depend on original imaging. Probably benign findings are typically monitored at 6, 12, and 24 months.
[qq] If a return visit is uncertain or there is strong patient preference, may include biopsy.
[ooo] When imaging indicates possible abscess as cause of focal pain, consider antibiotics, aspiration, and/or surgical consultation.
[ppp] If complicated cyst, consider aspiration.

Note: All recommendations are category 2A unless otherwise indicated.

Version 1.2026, 03/05/26 © 2026 National Comprehensive Cancer Network® (NCCN®), All rights reserved. NCCN Guidelines® and this illustration may not be reproduced in any form without the express written permission of NCCN.

PLEASE NOTE that use of this NCCN Content is governed by the End-User License Agreement, and you MAY NOT distribute this Content or use it with any artificial intelligence model or tool.
Printed by Ambrish Chauhan on 5/1/2026 7:03:18 AM. Copyright © 2026 National Comprehensive Cancer Network, Inc. All Rights Reserved.

RECOMMENDATIONS FOR WORKUP/DIAGNOSTIC EVALUATION OF AXILLARY MASS

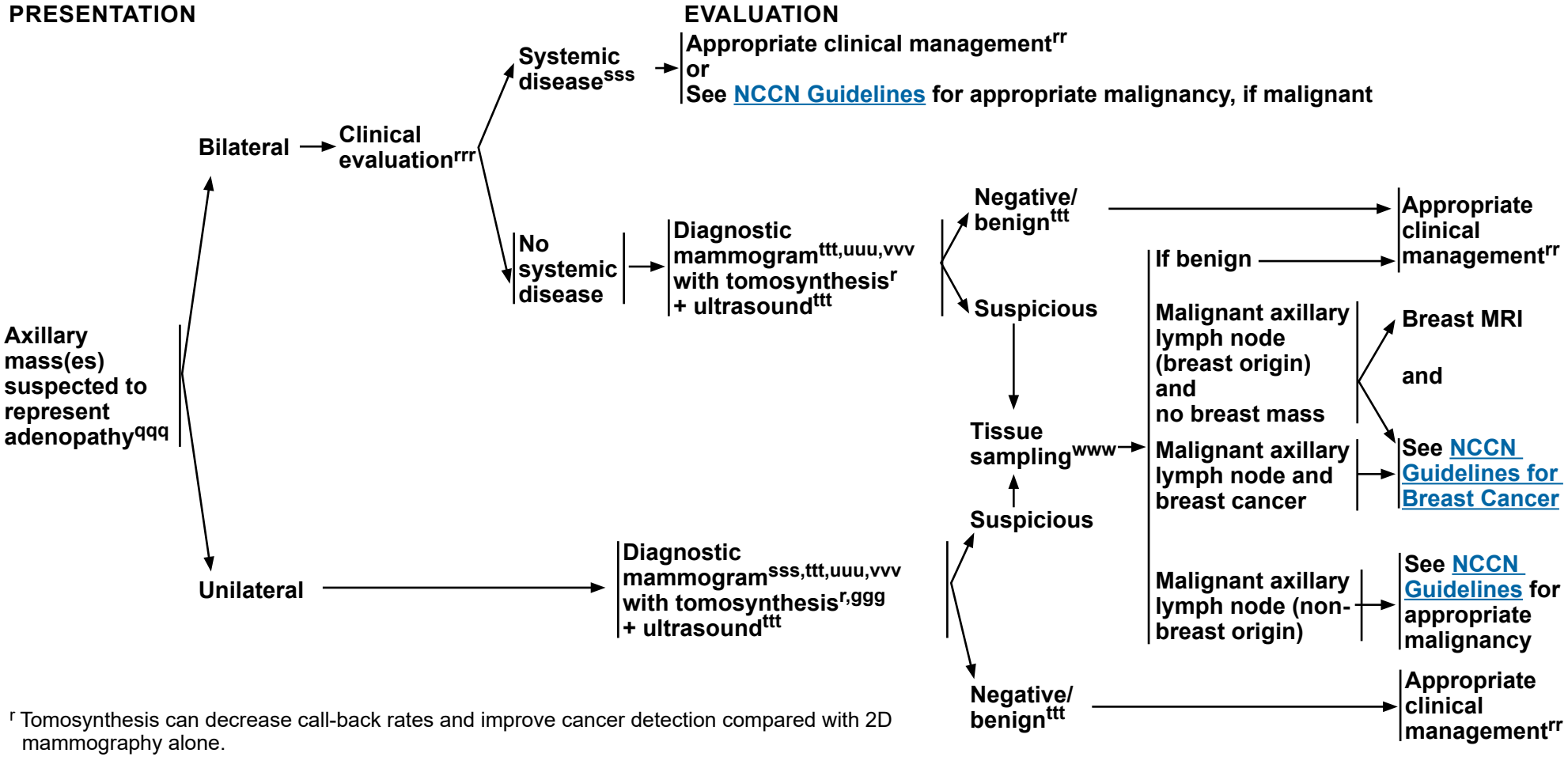

[r] Tomosynthesis can decrease call-back rates and improve cancer detection compared with 2D mammography alone.
[rr] Referral to a breast specialist, supplemental imaging, and/or tissue sampling.
[ggg] CEM may be considered if available when clinically suspicious.
[qqq] If not expected to represent adenopathy, see BSCR-5.
[rrr] Complete clinical evaluation to assess for other sites of adenopathy and potential non-breast etiologies of adenopathy.
[sss] Evidence of clinical conditions known to be associated with systemic adenopathy such as lupus, rheumatoid arthritis, human immunodeficiency virus (HIV) infection, and others. Assess recent vaccination status and manage accordingly.
[ttt] For additional guidance based upon BI-RADS category 3 (probably benign) assessment, see BSCR-18.
[uuu] If aged <30 years, mammogram is optional unless ultrasound results are suspicious.
[vvv] Mammogram is recommended in those ≥30 years.
[www] If lymphoma is suspected, tissue/specimen may require special pathologic processing and/or surgical excision.

Note: All recommendations are category 2A unless otherwise indicated.

Version 1.2026, 03/05/26 © 2026 National Comprehensive Cancer Network® (NCCN®), All rights reserved. NCCN Guidelines® and this illustration may not be reproduced in any form without the express written permission of NCCN.

PLEASE NOTE that use of this NCCN Content is governed by the End-User License Agreement, and you MAY NOT distribute this Content or use it with any artificial intelligence model or tool.
Printed by Ambrish Chauhan on 5/1/2026 7:03:18 AM. Copyright © 2026 National Comprehensive Cancer Network, Inc. All Rights Reserved.

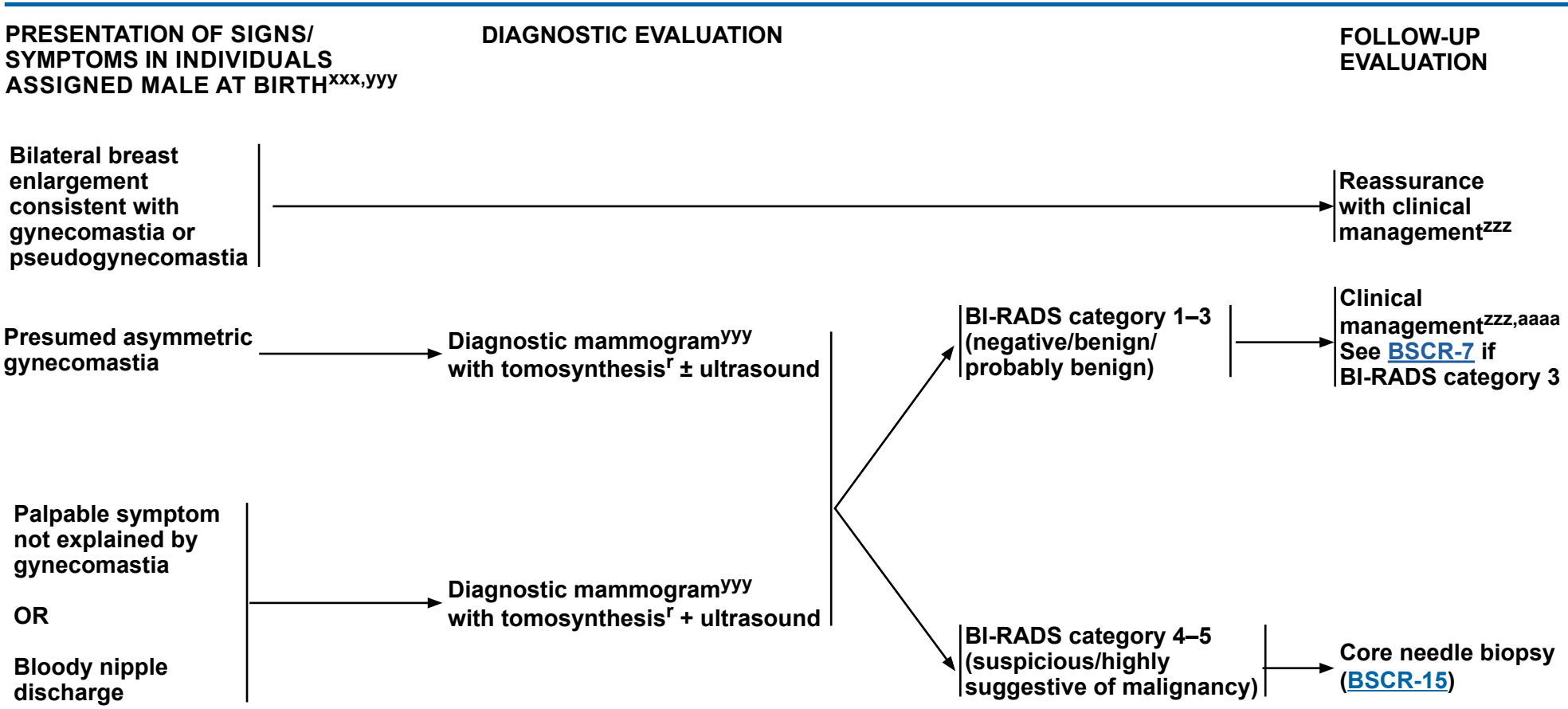

[r] Tomosynthesis can decrease call-back rates and improve cancer detection compared with 2D mammography alone.
[xxx] See NCCN Guidelines for Breast Cancer for management and special considerations for breast cancer in individuals AMAB.
[yyy] Mammogram generally not performed prior to age 25 years for individuals AMAB.
[zzz] Clinical management depends on the presumed cause (drug-induced, hypogonadism, hyperthyroidism, idiopathic), age of patient, duration, and presence of symptoms.
[aaaa] Consider surgical referral for suspicious clinical findings.

Note: All recommendations are category 2A unless otherwise indicated.

Version 1.2026, 03/05/26 © 2026 National Comprehensive Cancer Network® (NCCN®), All rights reserved. NCCN Guidelines® and this illustration may not be reproduced in any form without the express written permission of NCCN.

PLEASE NOTE that use of this NCCN Content is governed by the End-User License Agreement, and you MAY NOT distribute this Content or use it with any artificial intelligence model or tool.
Printed by Ambrish Chauhan on 5/1/2026 7:03:18 AM. Copyright © 2026 National Comprehensive Cancer Network, Inc. All Rights Reserved.

FOLLOW-UP EVALUATION AFTER CORE NEEDLE BIOPSY

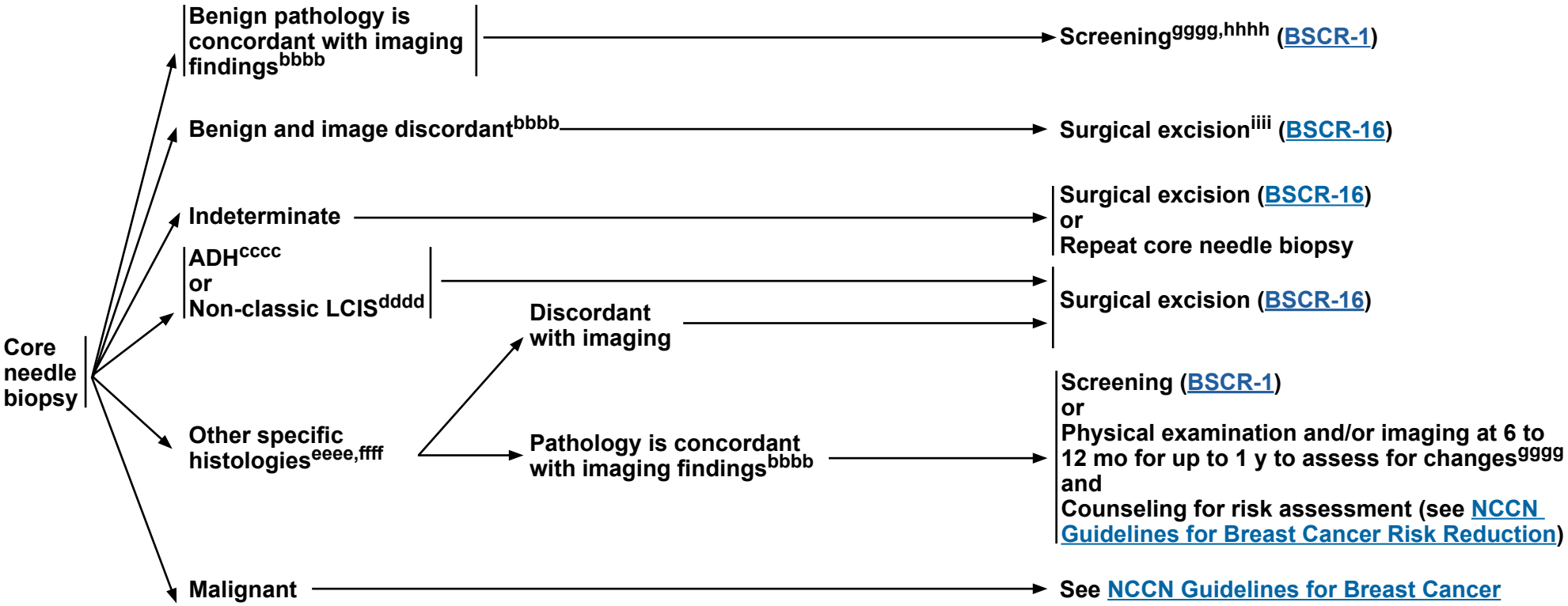

[bbbb] Concordance established by radiologist/breast specialist after review of core needle biopsy pathology report and imaging findings. This may require discussion/review with pathologist.

[cccc] Select patients may be suitable for monitoring in lieu of surgical excision.

[dddd] Clinicians should consider complete excision with negative margins for non-classic LCIS (pleomorphic or florid LCIS) on a core biopsy. However, outcomes data regarding treatment of individuals with non-classic LCIS are limited, due in part to a paucity of histologic categorization of variants of LCIS.

[eeee] For select patients with other specific histologies (eg, classic LCIS, ALH, flat epithelial atypia [FEA], papillomas without atypia, fibroepithelial lesions favoring fibroadenoma, radial scars adequately sampled without atypia) routine excision is generally not required.

[ffff] Other histologies that may require additional tissue: mucin-producing lesions, potential phyllodes tumor, papillary lesions, radial scar, or histologies of concern to pathologist.

[gggg] Physical examination and/or imaging at 6 or 12 months for up to 1 year may be considered to assess for changes. There may be variability on the follow-up interval of physical examination and/or imaging based on the level of suspicion.

[hhhh] While most would return to annual screening, there is the option of physical examination with or without further imaging for individuals <40 years.

[iiii] In certain situations, at the discretion of the radiologist, repeat attempt at percutaneous sampling may be warranted.

Note: All recommendations are category 2A unless otherwise indicated.

Version 1.2026, 03/05/26 © 2026 National Comprehensive Cancer Network® (NCCN®), All rights reserved. NCCN Guidelines® and this illustration may not be reproduced in any form without the express written permission of NCCN.

PLEASE NOTE that use of this NCCN Content is governed by the End-User License Agreement, and you MAY NOT distribute this Content or use it with any artificial intelligence model or tool.
Printed by Ambrish Chauhan on 5/1/2026 7:03:18 AM. Copyright © 2026 National Comprehensive Cancer Network, Inc. All Rights Reserved.

FOLLOW-UP EVALUATION AFTER SURGICAL EXCISION[jjjj]

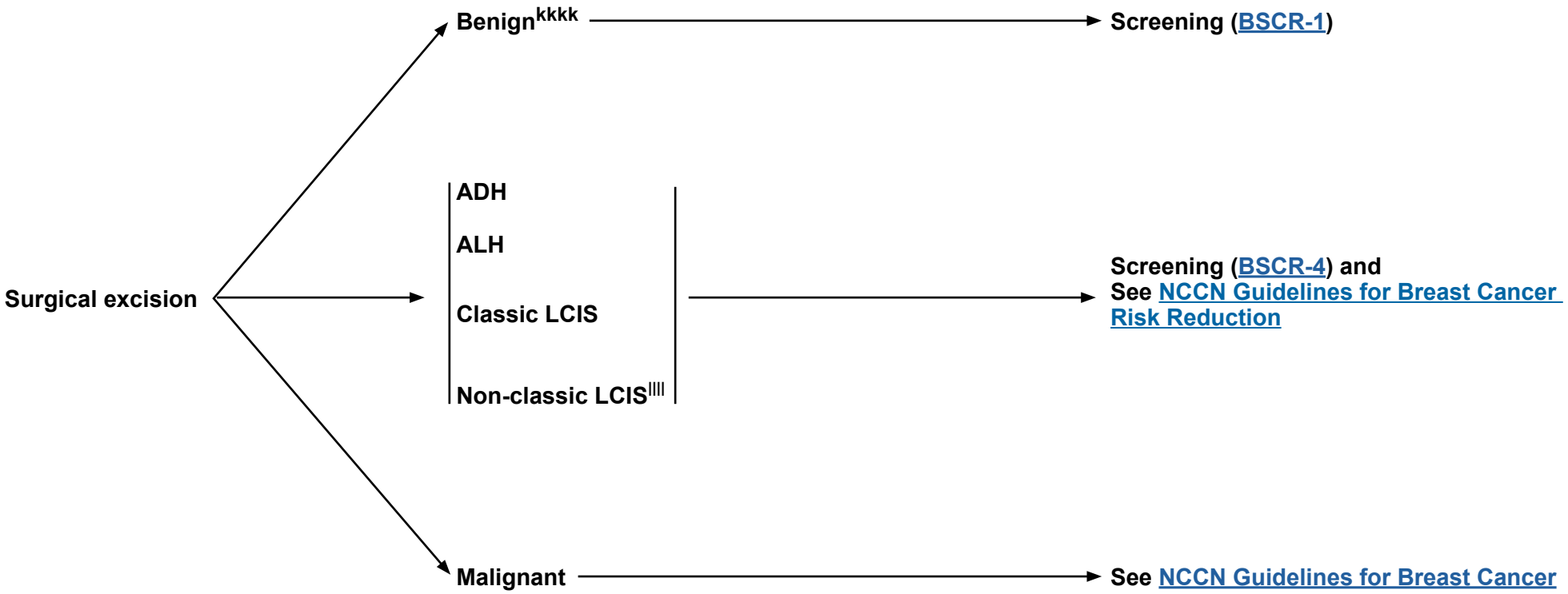

[jjjj] If surgical excision results are not concordant with imaging or core needle biopsy results, clinical correlation is recommended.
[kkkk] Includes lesions such as radial scar, papillomas, and FEA.
[llll] Complete excision with negative margins would typically be performed for non-classic LCIS. However, outcomes data regarding treatment of individuals with non-classic LCIS are limited, due in part to a paucity of histologic categorization of variants of LCIS.

Note: All recommendations are category 2A unless otherwise indicated.

Version 1.2026, 03/05/26 © 2026 National Comprehensive Cancer Network® (NCCN®), All rights reserved. NCCN Guidelines® and this illustration may not be reproduced in any form without the express written permission of NCCN.

PLEASE NOTE that use of this NCCN Content is governed by the End-User License Agreement, and you MAY NOT distribute this Content or use it with any artificial intelligence model or tool.
Printed by Ambrish Chauhan on 5/1/2026 7:03:18 AM. Copyright © 2026 National Comprehensive Cancer Network, Inc. All Rights Reserved.

FOLLOW-UP EVALUATION AFTER ASPIRATION FOLLOWING A CLINICALLY SUSPICIOUS PALPABLE BI-RADS CATEGORY 2 FINDING

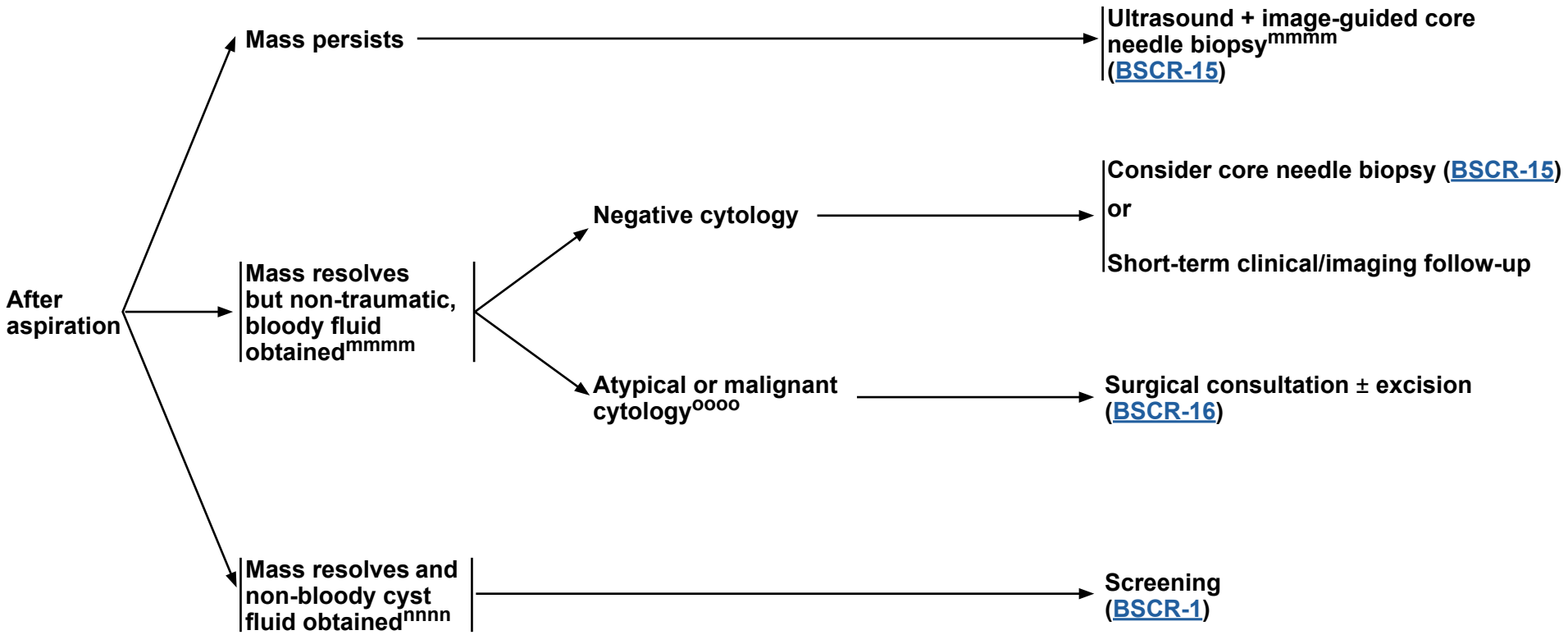

[mmmm] Place marker clip and send to pathology.
[nnnn] Routine cytology is not recommended.
[oooo] There are some circumstances in which cytology may be sufficient. If cytology is concordant, core needle biopsy may not be needed.

Note: All recommendations are category 2A unless otherwise indicated.

Version 1.2026, 03/05/26 © 2026 National Comprehensive Cancer Network® (NCCN®), All rights reserved. NCCN Guidelines® and this illustration may not be reproduced in any form without the express written permission of NCCN.

PLEASE NOTE that use of this NCCN Content is governed by the End-User License Agreement, and you MAY NOT distribute this Content or use it with any artificial intelligence model or tool.
Printed by Ambrish Chauhan on 5/1/2026 7:03:18 AM. Copyright © 2026 National Comprehensive Cancer Network, Inc. All Rights Reserved.

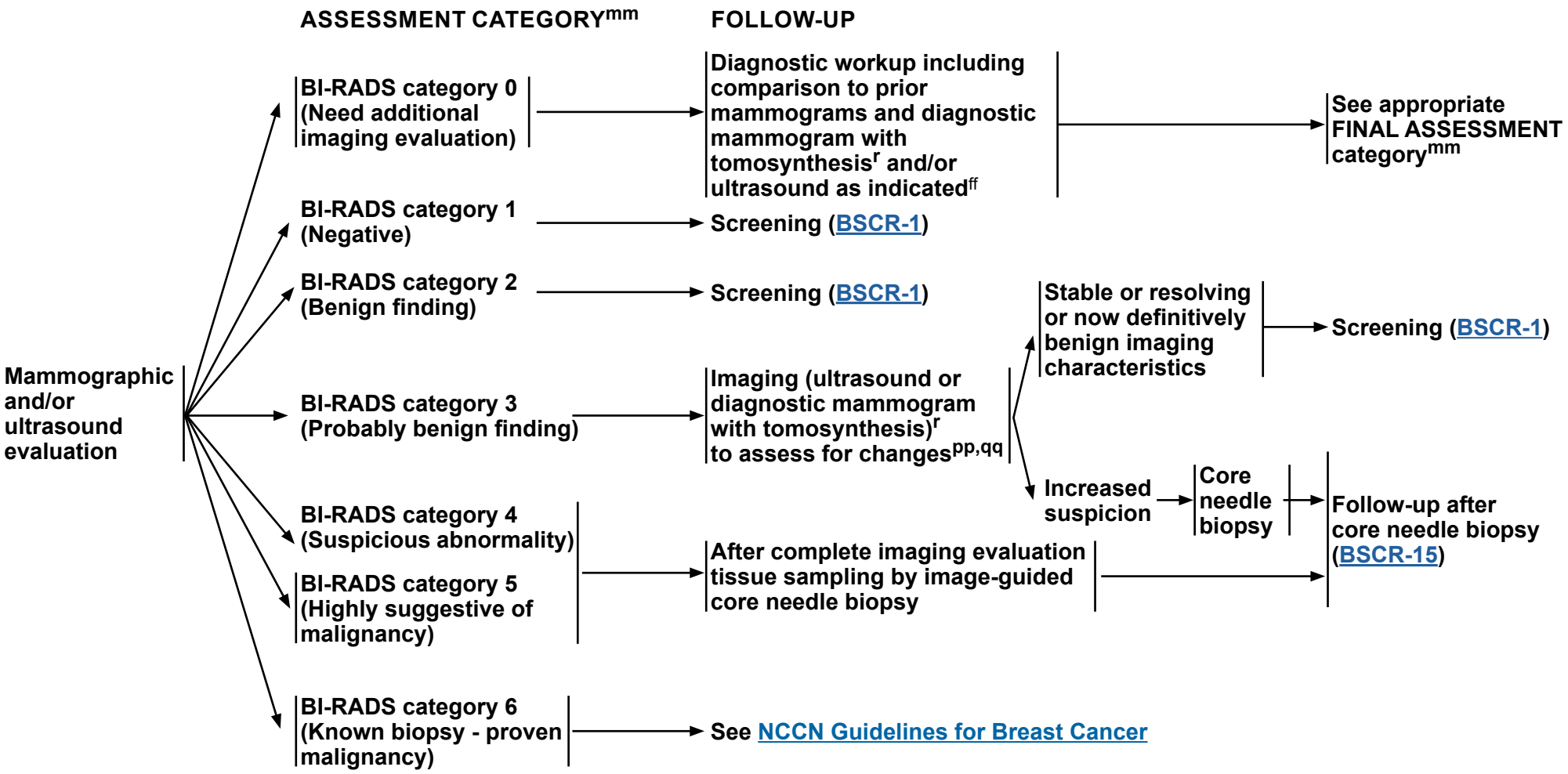

[r] Tomosynthesis can decrease call-back rates and improve cancer detection compared with 2D mammography alone.
[ff] Attention to timely diagnostic follow-up after abnormal breast screening is recommended, as racial disparities have been observed in time to diagnostic imaging and/or biopsy following abnormal breast screening. See Discussion.
[mm] Assessment Category Definitions (BSCR-C).
[pp] Imaging modality would depend on original imaging. Probably benign findings are typically monitored at 6, 12, and 24 months.
[qq] If a return visit is uncertain or there is strong patient preference, may include biopsy.

Note: All recommendations are category 2A unless otherwise indicated.

Version 1.2026, 03/05/26 © 2026 National Comprehensive Cancer Network® (NCCN®), All rights reserved. NCCN Guidelines® and this illustration may not be reproduced in any form without the express written permission of NCCN.

PLEASE NOTE that use of this NCCN Content is governed by the End-User License Agreement, and you MAY NOT distribute this Content or use it with any artificial intelligence model or tool.
Printed by Ambrish Chauhan on 5/1/2026 7:03:18 AM. Copyright © 2026 National Comprehensive Cancer Network, Inc. All Rights Reserved.

BREAST SCREENING CONSIDERATIONS

General Considerations

- These guidelines are intended for individuals assigned female at birth with residual native breast tissue; however, these guidelines do not provide screening guidance for transgender individuals. Certain organizations have developed consensus-based guidelines for transgender individuals, such as the ACR Appropriateness Criteria. NCCN endorses these criteria. Transgender individuals should consult with their primary care physician to determine when/whether screening would be appropriate.
- Individuals should undergo breast cancer risk assessment by age 25 years and be counseled regarding potential benefits, risks, and limitations of breast screening in the context of their risk stratification. For individuals who meet criteria for multiple increased-risk categories, the most comprehensive set of screening recommendations should be followed.
- Shared decision-making is encouraged based on a patient's values and preferences (Discussion).
- Screening mammography decreases breast cancer mortality. Digital breast tomosynthesis is recommended, when available. Multiple studies show that tomosynthesis can decrease call-back rates and improve cancer detection compared with two-dimensional (2D) mammography alone, though long-term data on incremental mortality reduction have not yet been demonstrated. Radiation exposure may be increased, but remain within FDA guidelines and can be reduced with FDA-approved synthesized 2D reconstruction.
- Current evidence does not support the use of thermography as a screening procedure.
- Attention to timely diagnostic follow-up after abnormal breast screening is recommended, as racial disparities have been observed in time to diagnostic imaging and/or biopsy following abnormal breast screening. See Discussion.

Upper Age Limit for Screening

- Upper age limit for mammographic screening is not yet established.
- Consider severe comorbid conditions limiting life expectancy (eg, ≤10 years) and whether therapeutic interventions would be appropriate and acceptable to the patient. Periodic reassessment of risk is recommended, particularly when risk factors change.

Note: All recommendations are category 2A unless otherwise indicated.

Version 1.2026, 03/05/26 © 2026 National Comprehensive Cancer Network® (NCCN®), All rights reserved. NCCN Guidelines® and this illustration may not be reproduced in any form without the express written permission of NCCN.

PLEASE NOTE that use of this NCCN Content is governed by the End-User License Agreement, and you MAY NOT distribute this Content or use it with any artificial intelligence model or tool.
Printed by Ambrish Chauhan on 5/1/2026 7:03:18 AM. Copyright © 2026 National Comprehensive Cancer Network, Inc. All Rights Reserved.

BREAST SCREENING CONSIDERATIONS

Breast Density and Other Risk Factors

- Dense breasts limit the sensitivity of mammography.
- Mammographically dense breast tissue is associated with an increased risk for breast cancer. Compared to patients with scattered areas of fibroglandular density, the odds ratio for developing breast cancer is 1.3 for heterogeneously dense and 1.8 for extremely dense breasts.[1] Increased breast density alone or in combination with other risk factors places patients at increased risk of developing breast cancer.
- For individuals in all breast density and risk categories, the Panel recommends shared decision-making with counseling on the risks and benefits of supplemental screening following evaluation of the individual's breast density and other risk factors.
- In addition to breast density, mammographic textural patterns also impact the sensitivity of mammography and are associated with breast cancer risk.[2]

Supplemental Screening Modalities

- Supplemental screening with breast MRI with and without contrast, abbreviated breast MRI with and without contrast, ultrasound, MBI, or CEM can increase cancer detection rates (CDRs) but may increase recalls and benign breast biopsies.
- For individuals at high risk for breast cancer who cannot undergo breast MRI, supplemental screening with CEM or MBI should be considered. Whole breast ultrasound may be done if contrast-enhanced imaging or functional imaging is not available/accessible.
- Abbreviated MRI has a higher CDR than mammography with tomosynthesis or ultrasound and likely has similar sensitivity compared to full protocol breast MRI.
- For individuals at high risk for breast cancer, based on current evidence and considering the FDA safety announcement[3] (gadolinium-based contrast agents), the Panel continues to recommend annual MRI in combination with annual screening mammography with tomosynthesis after shared decision-making.
- Although supplemental screening ultrasound detects more cancers compared to mammography with tomosynthesis alone, ultrasound demonstrates lower CDR than breast MRI or abbreviated breast MRI.
- Limited data exist regarding the use of MBI for breast cancer screening; however, screening MBI has similar sensitivity but improved specificity and recall rate compared to ultrasound in studies with individuals with dense breasts. However, MBI has a whole-body effective radiation dose higher than standard mammography.
- Emerging data support the use of CEM for breast cancer screening.[4,5] In individuals at increased risk for breast cancer, CEM increases CDR compared to mammography alone. CEM carries the risk of iodinated contrast reactions.
- Individuals with a residual lifetime risk of breast cancer of 15% to 20% may be considered for supplemental screening on an individual basis, depending on risk factors.

References on BSCR-A 3 of 3

Note: All recommendations are category 2A unless otherwise indicated.

Version 1.2026, 03/05/26 © 2026 National Comprehensive Cancer Network® (NCCN®), All rights reserved. NCCN Guidelines® and this illustration may not be reproduced in any form without the express written permission of NCCN.

PLEASE NOTE that use of this NCCN Content is governed by the End-User License Agreement, and you MAY NOT distribute this Content or use it with any artificial intelligence model or tool.
Printed by Ambrish Chauhan on 5/1/2026 7:03:18 AM. Copyright © 2026 National Comprehensive Cancer Network, Inc. All Rights Reserved.

BREAST SCREENING CONSIDERATIONS

REFERENCES

[1] Bodewes FTH, van Asselt AA, Dorrius MD, et al. Mammographic breast density and the risk of breast cancer: A systematic review and meta-analysis. Breast 2022;66:62-68.
[2] Wanders JOP, van Gils CH, Karssemeijer N, et al. The combined effect of mammographic texture and density on breast cancer risk: a cohort study. Breast Cancer Res 2018;20:36.
[3] FDA Drug Safety Communication: FDA warns that gadolinium-based contrast agents (GBCAs) are retained in the body; requires new class warnings: https://www.fda.gov/drugs/drug-safety-and-availability/fda-drug-safety-communication-fda-warns-gadolinium-based-contrast-agents-gbcas-are-retained-body.
[4] Berg WA, Vargo A, Lu AH, et al. Screening for breast cancer with contrast-enhanced mammography as an alternative to MRI: SCEMAM trial results. Radiology 2025;315:e242634.
[5] Gilbert FJ, Payne NR, Allajbeu I, et al. Comparison of supplemental breast cancer imaging techniques-interim results from the BRAID randomised controlled trial. Lancet 2025;405:1935-1944.

Note: All recommendations are category 2A unless otherwise indicated.

Version 1.2026, 03/05/26 © 2026 National Comprehensive Cancer Network® (NCCN®), All rights reserved. NCCN Guidelines® and this illustration may not be reproduced in any form without the express written permission of NCCN.

PLEASE NOTE that use of this NCCN Content is governed by the End-User License Agreement, and you MAY NOT distribute this Content or use it with any artificial intelligence model or tool.
Printed by Ambrish Chauhan on 5/1/2026 7:03:18 AM. Copyright © 2026 National Comprehensive Cancer Network, Inc. All Rights Reserved.

MANAGEMENT OF BREAST CANCER SCREENING AND BREAST SYMPTOMS DURING PREGNANCY OR LACTATION

Condition	Recommendation				Rationale for Recommendation/Other Considerations
	CBE	Mammogram with Tomosynthesis[a,b]	Ultrasound	MRI	
Average-Risk Screening in Individuals ≥40 Years	R	R	NR	NR	• While ionizing radiation exposure with mammography is many-fold below the threshold of fetal teratogenesis (see comments below), due to the infrequency of pregnancy-associated breast cancers (PABCs) and the decreased sensitivity and specificity of mammography during pregnancy, providers and patients may implement a short delay in routine breast imaging based on prior imaging and date of delivery in individuals who are at average risk until after pregnancy. • There are no data evaluating the use of ultrasound alone as an alternative screening method in individuals who are at average risk during pregnancy; therefore, this is not recommended as an alternative to screening mammography. • While there is both decreased sensitivity and specificity of screening mammography during lactation, there is no contraindication to screening mammography during lactation. • A short delay in routine breast imaging may be implemented until after lactation in those with average risk of getting breast cancer based on prior imaging results, particularly if they are not planning prolonged breastfeeding. • Pumping the breast or breastfeeding just prior to imaging is recommended for individuals who are lactating to improve sensitivity and comfort of the examination.

R = Recommended, NR = Not recommended, O = Optional, depending on individual circumstances

[a] Tomosynthesis can decrease call-back rates and improve cancer detection compared with 2D mammography alone.
[b] There is no contraindication to mammography during pregnancy or lactation.

Note: All recommendations are category 2A unless otherwise indicated.

Version 1.2026, 03/05/26 © 2026 National Comprehensive Cancer Network® (NCCN®), All rights reserved. NCCN Guidelines® and this illustration may not be reproduced in any form without the express written permission of NCCN.

PLEASE NOTE that use of this NCCN Content is governed by the End-User License Agreement, and you MAY NOT distribute this Content or use it with any artificial intelligence model or tool.
Printed by Ambrish Chauhan on 5/1/2026 7:03:18 AM. Copyright © 2026 National Comprehensive Cancer Network, Inc. All Rights Reserved.

MANAGEMENT OF BREAST CANCER SCREENING AND BREAST SYMPTOMS DURING PREGNANCY OR LACTATION

Condition	Recommendation				Rationale for Recommendation/Other Considerations
	CBE	Mammogram with Tomosynthesis[a,b]	Ultrasound	MRI	
Increased-Risk Screening (BSCR-1)	R	R	O during pregnancy; NR during lactation	NR during pregnancy; R during lactation	• In individuals who are at increased risk for breast cancer, it is appropriate to recommend age-appropriate screening mammography at routine intervals (BSCR-2, BSCR-3, and BSCR-4). • The use of screening ultrasound alone has not been evaluated as a method to reduce breast cancer mortality in individuals who are pregnant or lactating who are at increased risk for breast cancer. • Contrast-enhanced breast MRI is not recommended during pregnancy due to the trans-placental passage of gadolinium and potential concerns of exposure of gadolinium to the fetus. Non-contrast MRI is not recommended due to lack of sensitivity. • In individuals who are lactating who are at increased risk for breast cancer, it is appropriate to recommend screening breast MRI at routine intervals (BSCR-2, BSCR-3, and BSCR-4). ▸ It is considered safe to continue breastfeeding after an MRI.[1,2] There is minimal excretion of gadolinium into human breast milk, with <1% of permitted neonatal dose of contrast over the first 24 hours after maternal administration. Breast MRI appears to be highly sensitive for the detection of known PABC and may proceed if due during lactation in individuals who are at increased risk for breast cancer. • Pumping the breast or breastfeeding just prior to imaging is recommended for individuals who are lactating to improve sensitivity and comfort of the examination.

R = Recommended, NR = Not recommended, O = Optional, depending on individual circumstances

[a] Tomosynthesis can decrease call-back rates and improve cancer detection compared with 2D mammography alone.
[b] There is no contraindication to mammography during pregnancy or lactation.

[1] ACR Manual on Contrast Media 2023. https://www.acr.org/Clinical-Resources/Contrast-Manual.
[2] Committee opinion no. 723: Guidelines for diagnostic imaging during pregnancy and lactation. Obstet Gynecol 2017;130:e210-e216.

Note: All recommendations are category 2A unless otherwise indicated.

Version 1.2026, 03/05/26 © 2026 National Comprehensive Cancer Network® (NCCN®), All rights reserved. NCCN Guidelines® and this illustration may not be reproduced in any form without the express written permission of NCCN.

PLEASE NOTE that use of this NCCN Content is governed by the End-User License Agreement, and you MAY NOT distribute this Content or use it with any artificial intelligence model or tool.
Printed by Ambrish Chauhan on 5/1/2026 7:03:18 AM. Copyright © 2026 National Comprehensive Cancer Network, Inc. All Rights Reserved.

MANAGEMENT OF BREAST CANCER SCREENING AND BREAST SYMPTOMS DURING PREGNANCY OR LACTATION

Condition	Recommendation				Rationale for Recommendation/Other Considerations
	CBE	Mammogram with Tomosynthesis[a,b]	Ultrasound	MRI	
Palpable Symptom	R	R[c]	R	NR[d] during pregnancy; O during lactation	• Because it is rare to develop a milk fistula after core needle biopsy, image-guided core needle biopsy should proceed in the usual prompt timeframe following a BI-RADS 4 or BI-RADS 5 imaging result during pregnancy or lactation. • Contrast-enhanced breast MRI is not recommended during pregnancy due to the trans-placental passage of gadolinium and potential concerns of exposure of gadolinium to the fetus. Non-contrast MRI is not recommended due to lack of sensitivity. • Pumping the breast or breastfeeding just prior to imaging is recommended for individuals who are lactating to improve sensitivity and comfort of the examination.
Nipple Inversion/ Retraction without Palpable Mass	R	R[c]	R	NR[d] during pregnancy; O during lactation	• Because it is rare to develop a milk fistula after core needle biopsy, image-guided core needle biopsy should proceed in the usual prompt timeframe following a BI-RADS 4 or BI-RADS 5 imaging result during pregnancy or lactation. • Contrast-enhanced breast MRI is not recommended during pregnancy due to the trans-placental passage of gadolinium and potential concerns of exposure of gadolinium to the fetus. Non-contrast MRI is not recommended due to lack of sensitivity. • Breast MRI is not contraindicated for the management of nipple retraction/inversion during lactation if clinically indicated. • Pumping the breast or breastfeeding just prior to imaging is recommended for individuals who are lactating to improve sensitivity and comfort of the examination.

R = Recommended, NR = Not recommended, O = Optional, depending on individual circumstances.

[a] Tomosynthesis can decrease call-back rates and improve cancer detection compared with 2D mammography alone.
[b] There is no contraindication to mammography during pregnancy or lactation.
[c] Age-appropriate evaluation of a palpable symptom during pregnancy or lactation should proceed similar to that outlined in BSCR-6.
[d] If mammographic and/or ultrasound imaging is negative and findings are clinically suspicious, consider CEM.

Note: All recommendations are category 2A unless otherwise indicated.

Version 1.2026, 03/05/26 © 2026 National Comprehensive Cancer Network® (NCCN®), All rights reserved. NCCN Guidelines® and this illustration may not be reproduced in any form without the express written permission of NCCN.

PLEASE NOTE that use of this NCCN Content is governed by the End-User License Agreement, and you MAY NOT distribute this Content or use it with any artificial intelligence model or tool.
Printed by Ambrish Chauhan on 5/1/2026 7:03:18 AM. Copyright © 2026 National Comprehensive Cancer Network, Inc. All Rights Reserved.

MANAGEMENT OF BREAST CANCER SCREENING AND BREAST SYMPTOMS DURING PREGNANCY OR LACTATION

Condition	Recommendation				Rationale for Recommendation/Other Considerations
	CBE	Mammogram with Tomosynthesis[a,b]	Ultrasound	MRI	
Nipple Discharge, No Palpable Symptom	R	R	R	NR[d] during pregnancy; O during lactation	• Because of the frequency of normal nipple discharge during pregnancy or lactation, abnormal nipple discharge is defined as: Persistent, spontaneous uniductal, unilateral bloody or clear nipple discharge. • Due to normal physiologic changes of pregnancy, bloody nipple discharge is common, but usually short-lived (eg, 1 or 2 episodes). Persistence beyond 1 or 2 episodes should undergo evaluation. • Age-appropriate evaluation of abnormal nipple discharge during lactation should proceed similar to that outlined in BSCR-9. • Because it is rare to develop a milk fistula after core needle biopsy, image-guided core needle biopsy should proceed in the usual prompt timeframe following a BI-RADS 4 or BI-RADS 5 imaging result during pregnancy or lactation. • If there is persistent bloody nipple discharge without abnormal breast imaging, a breast surgical expert should be consulted to discuss possible further diagnostic testing (eg, duct excision). • Contrast-enhanced breast MRI is not recommended during pregnancy due to the trans-placental passage of gadolinium, and potential concerns of exposure of gadolinium to the fetus. Non-contrast MRI is not recommended due to lack of sensitivity. • Breast MRI is not contraindicated for the management of abnormal nipple discharge during lactation if clinically indicated. • Pumping the breast or breastfeeding just prior to imaging is recommended for individuals who are lactating to improve sensitivity and comfort of the examination.

R = Recommended, NR = Not recommended, O = Optional, depending on individual circumstances.

[a] Tomosynthesis can decrease call-back rates and improve cancer detection compared with 2D mammography alone.
[b] There is no contraindication to mammography during pregnancy or lactation.
[d] If mammographic and/or ultrasound imaging is negative and findings are clinically suspicious, consider CEM.

Note: All recommendations are category 2A unless otherwise indicated.

Version 1.2026, 03/05/26 © 2026 National Comprehensive Cancer Network® (NCCN®), All rights reserved. NCCN Guidelines® and this illustration may not be reproduced in any form without the express written permission of NCCN.

PLEASE NOTE that use of this NCCN Content is governed by the End-User License Agreement, and you MAY NOT distribute this Content or use it with any artificial intelligence model or tool.
Printed by Ambrish Chauhan on 5/1/2026 7:03:18 AM. Copyright © 2026 National Comprehensive Cancer Network, Inc. All Rights Reserved.

MANAGEMENT OF BREAST CANCER SCREENING AND BREAST SYMPTOMS DURING PREGNANCY OR LACTATION

Condition	Recommendation				Rationale for Recommendation/Other Considerations
	CBE	Mammogram with Tomosynthesis[a,b]	Ultrasound	MRI	
Suspicious Skin Changes	R	R	R	NR[e] during pregnancy; O during lactation	• Suspicious breast erythema or skin changes during lactation may be due to puerperal mastitis; all patients should undergo evaluation and, if clinically consistent with mastitis, appropriate treatment should proceed, including the use of antimicrobials. • During pregnancy, and during lactation if there is no evidence of mastitis (absence of pain or fever), suspicious breast erythema or skin changes should undergo age-appropriate breast imaging evaluation similar to that outlined on BSCR-10. • During lactation, failure to resolve mastitis with usual treatment should result in both clinical and imaging evaluation for alternative etiologies (eg, breast abscess, breast cancer). ▸ Breast imaging is nearly always indicated to assist in the diagnosis of persistent breast erythema or skin changes that have not improved with usual treatment for mastitis. In this circumstance, age-appropriate evaluation should proceed similar to that outlined on BSCR-10. ▸ Breast ultrasound is particularly useful in diagnosing breast abscess and may be the appropriate first imaging modality and if found, drainage is usually indicated and provides a definitive diagnosis. ▸ However, if a breast abscess is not definitively identified, individuals should promptly undergo evaluation for breast cancer (BSCR-10). • Contrast-enhanced breast MRI is not recommended during pregnancy due to the transplacental passage of gadolinium, and potential concerns of exposure of gadolinium to the fetus. Non-contrast MRI is not recommended due to lack of sensitivity. • Pumping the breast or breastfeeding just prior to imaging is recommended for individuals who are lactating to improve sensitivity and comfort of the examination.

R = Recommended, NR = Not recommended, O = Optional, depending on individual circumstances.

[a] Tomosynthesis can decrease call-back rates and improve cancer detection compared with 2D mammography alone.
[b] There is no contraindication to mammography during pregnancy or lactation.
[e] If mammographic and/or ultrasound imaging is negative and findings are clinically suspicious, consider CEM or skin punch biopsy.

Note: All recommendations are category 2A unless otherwise indicated.

Version 1.2026, 03/05/26 © 2026 National Comprehensive Cancer Network® (NCCN®), All rights reserved. NCCN Guidelines® and this illustration may not be reproduced in any form without the express written permission of NCCN.

PLEASE NOTE that use of this NCCN Content is governed by the End-User License Agreement, and you MAY NOT distribute this Content or use it with any artificial intelligence model or tool.
Printed by Ambrish Chauhan on 5/1/2026 7:03:18 AM. Copyright © 2026 National Comprehensive Cancer Network, Inc. All Rights Reserved.

MANAGEMENT OF BREAST CANCER SCREENING AND BREAST SYMPTOMS DURING PREGNANCY OR LACTATION

Condition	Recommendation				Rationale for Recommendation/Other Considerations
	CBE	Mammogram with Tomosynthesis[a,b]	Ultrasound	MRI	
Persistent or Severe Focal Breast Pain	R	R	R	NR[f]	• While breast pain is common due to the physiologic changes of pregnancy or lactation and is considered normal, focal persistent breast pain (defined as 4–6 weeks duration) should undergo evaluation similar to that outlined on BSCR-11. • Because it is rare to develop a milk fistula after core needle biopsy, image-guided biopsy should proceed in the usual prompt timeframe following a BI-RADS 4 or BI-RADS 5 imaging result during pregnancy or lactation. • Contrast-enhanced breast MRI is not recommended during pregnancy due to the transplacental passage of gadolinium and potential concerns of exposure of gadolinium to the fetus. Non-contrast MRI is not recommended due to lack of sensitivity. • While breast MRI is not contraindicated for the management of persistent, focal breast pain during lactation, it is usually not indicated. • Pumping the breast or breastfeeding just prior to imaging is recommended for individuals who are lactating to improve sensitivity and comfort of the examination.

R = Recommended, NR = Not recommended, O = Optional, depending on individual circumstances.

[a] Tomosynthesis can decrease call-back rates and improve cancer detection compared with 2D mammography alone.
[b] There is no contraindication to mammography during pregnancy or lactation.
[f] If mammographic and/or ultrasound imaging is negative and findings are clinically suspicious, consider CEM or palpable biopsy.

Note: All recommendations are category 2A unless otherwise indicated.

Version 1.2026, 03/05/26 © 2026 National Comprehensive Cancer Network® (NCCN®), All rights reserved. NCCN Guidelines® and this illustration may not be reproduced in any form without the express written permission of NCCN.

PLEASE NOTE that use of this NCCN Content is governed by the End-User License Agreement, and you MAY NOT distribute this Content or use it with any artificial intelligence model or tool.
Printed by Ambrish Chauhan on 5/1/2026 7:03:18 AM. Copyright © 2026 National Comprehensive Cancer Network, Inc. All Rights Reserved.

MANAGEMENT OF BREAST CANCER SCREENING AND BREAST SYMPTOMS DURING PREGNANCY OR LACTATION

Condition	Recommendation				Rationale for Recommendation/Other Considerations
	CBE	Mammogram with Tomosynthesis[a,b]	Ultrasound	MRI	
BI-RADS Category 3 Imaging Follow-up (BSCR-18)	R‡‡	R‡	R‡	NR‡‡‡	• Pregnancy or lactation should not change the management of follow-up of a BI-RADS 3 finding, and appropriate follow-up imaging and/or examination should proceed as outlined in BSCR-18. • In the case of a BI-RADS 3 finding on MRI during pregnancy without associated ultrasound or mammography findings, a breast expert should be consulted to assist with counseling regarding follow-up and management recommendations (eg, defer to after pregnancy). • Contrast-enhanced breast MRI is not recommended during pregnancy due to the transplacental passage of gadolinium and potential concerns of exposure of gadolinium to the fetus. Non-contrast MRI is not recommended due to lack of sensitivity. • Pumping the breast or breastfeeding just prior to imaging is recommended for individuals who are lactating to improve sensitivity and comfort of the examination.

R = Recommended, NR = Not recommended, O = Optional, depending on individual circumstances. ‡Recommended if this is the imaging modality that initially resulted in the BI-RADS 3 finding. ‡‡If an abnormal CBE finding was associated with the BI-RADS 3 imaging result, it may be appropriate to repeat CBE. ‡‡‡Recommended during lactation if MRI was the imaging modality that initially resulted in the BI-RADS 3 finding and there are no ultrasound or mammographic correlates.

[a] Tomosynthesis can decrease call-back rates and improve cancer detection compared with 2D mammography alone.
[b] There is no contraindication to mammography during pregnancy or lactation.

Note: All recommendations are category 2A unless otherwise indicated.

Version 1.2026, 03/05/26 © 2026 National Comprehensive Cancer Network® (NCCN®), All rights reserved. NCCN Guidelines® and this illustration may not be reproduced in any form without the express written permission of NCCN.

PLEASE NOTE that use of this NCCN Content is governed by the End-User License Agreement, and you MAY NOT distribute this Content or use it with any artificial intelligence model or tool.
Printed by Ambrish Chauhan on 5/1/2026 7:03:18 AM. Copyright © 2026 National Comprehensive Cancer Network, Inc. All Rights Reserved.

MANAGEMENT OF BREAST CANCER SCREENING AND BREAST SYMPTOMS DURING PREGNANCY OR LACTATION

Condition	Recommendation				Rationale for Recommendation/Other Considerations
	CBE	Mammogram with Tomosynthesis[a,b]	Ultrasound	MRI	
Axillary Mass(es) Suspected to Represent Adenopathy[g]	R	R[g]	R	NR	• The development of an axillary mass during pregnancy or lactation may be due to normal breast enlargement or lactational changes that occur during pregnancy or lactation in accessory axillary breast tissue that is present in ~15% of individuals. It is also not uncommon for this to be asymmetric. The development of an axillary mass within the first 2 weeks following delivery is clinically consistent with lactational changes due to the presence of axillary breast tissue. • If after clinical examination there remains concern that the physical findings are not due to normal axillary breast tissue that has enlarged due to pregnancy, providers should proceed with evaluation as outlined in BSCR-13. • Contrast-enhanced breast MRI is not recommended during pregnancy due to the transplacental passage of gadolinium and potential concerns of exposure of gadolinium to the fetus. Non-contrast MRI is not recommended due to lack of sensitivity. • Pumping the breast or breastfeeding just prior to imaging is recommended for individuals who are lactating to improve sensitivity and comfort of the examination.

R = Recommended, NR = Not recommended, O = Optional, depending on individual circumstances.

[a] Tomosynthesis can decrease call-back rates and improve cancer detection compared with 2D mammography alone.
[b] There is no contraindication to mammography during pregnancy or lactation.
[g] If suspicious axillary lymph nodes are identified, mammography is recommended.

Note: All recommendations are category 2A unless otherwise indicated.

Version 1.2026, 03/05/26 © 2026 National Comprehensive Cancer Network® (NCCN®), All rights reserved. NCCN Guidelines® and this illustration may not be reproduced in any form without the express written permission of NCCN.

PLEASE NOTE that use of this NCCN Content is governed by the End-User License Agreement, and you MAY NOT distribute this Content or use it with any artificial intelligence model or tool.
Printed by Ambrish Chauhan on 5/1/2026 7:03:18 AM. Copyright © 2026 National Comprehensive Cancer Network, Inc. All Rights Reserved.

MAMMOGRAPHIC ASSESSMENT CATEGORY DEFINITIONS[1,2]

BI-RADS® - MAMMOGRAPHY FINDINGS

A. Assessment Is Incomplete:
Category 0: Incomplete - Need Additional Imaging Evaluation:
There is a finding for which additional evaluation is needed. This is almost always used in a screening situation. Under certain circumstances this assessment category may be used in a diagnostic mammography report, such as when ultrasound equipment or personnel are not immediately available, or when the patient is unable or unwilling to wait for completion of a full diagnostic examination. A recommendation for additional imaging evaluation includes the use of spot compression (with or without magnification), special mammographic views, and ultrasound. Category 0 should not be used for diagnostic breast imaging findings that warrant further evaluation with MRI. Rather, the interpreting physician should issue a final assessment in a report that is made before the MRI examination is performed. In most circumstances and when feasible, if a mammography examination is not assessed as negative or benign, the current examination should be compared with prior examination(s). The interpreting physician should use judgment on how vigorously to attempt obtaining prior examinations, given the likelihood of success of such an endeavor and the likelihood that comparison will affect the final assessment. In this context, it is important to note that comparison with previous examination(s) may be irrelevant when a finding is inherently suspicious for malignancy.

Category 0: Incomplete - Need Prior Mammograms for Comparison: should be used for prior image comparison only when such comparison is required to make a final assessment. When category 0 is used in the context of awaiting prior examinations for comparison, there should be in place a tracking procedure guaranteeing with 100% reliability that a final assessment will be made within 30 days (preferably sooner) even if prior examinations do not become available. Some mammography practices may reasonably choose never to use category 0 in the context of awaiting prior examinations simply because they do not have a 100% reliable tracking procedure. If a mammography examination is assessed as category 0 in the context of awaiting prior examinations and then the prior examinations do become available, an addendum to the initial mammography report should be issued, including a revised assessment. For auditing purposes, the revised assessment should replace the initial assessment.

[1] Mammography results are mandated to be reported using Final Assessment categories (Quality Mammography Standards: Final Rule. Federal Register. September 10, 2024).
[2] Terminology in this table is reflective of the American College of Radiology (ACR). ACR-BI-RADS®--5th Edition. ACR Breast Imaging Reporting and Data System, Breast Imaging Atlas; BI-RADS®. Reston, VA. American College of Radiology, 2014. For more information, see www.acr.org.
Reprinted with permission from the American College of Radiology. No other representation of this document is authorized without express, written permission from the American College of Radiology.

Note: All recommendations are category 2A unless otherwise indicated.

Version 1.2026, 03/05/26 © 2026 National Comprehensive Cancer Network® (NCCN®), All rights reserved. NCCN Guidelines® and this illustration may not be reproduced in any form without the express written permission of NCCN.

PLEASE NOTE that use of this NCCN Content is governed by the End-User License Agreement, and you MAY NOT distribute this Content or use it with any artificial intelligence model or tool.
Printed by Ambrish Chauhan on 5/1/2026 7:03:18 AM. Copyright © 2026 National Comprehensive Cancer Network, Inc. All Rights Reserved.

MAMMOGRAPHIC ASSESSMENT CATEGORY DEFINITIONS[1,2]

BI-RADS® - MAMMOGRAPHY FINDINGS

B. Assessment Is Complete - Final Assessment Categories:
Category 1: Negative:
There is nothing to comment on. This is a normal examination.

Category 2: Benign:
Like Category 1, this is a "normal" assessment, but here, the interpreter chooses to describe a benign finding in the mammography report. Involuting, calcified fibroadenomas, skin calcifications, metallic foreign bodies (such as core biopsy and surgical clips), and fat-containing lesions (such as oil cysts, lipomas, galactoceles, and mixed-density hamartomas) all have characteristically benign appearances and may be described with confidence. The interpreter may also choose to describe intramammary lymph nodes, vascular calcifications, implants, or architectural distortion clearly related to prior surgery while still concluding that there is no mammographic evidence of malignancy. On the other hand, the interpreter may choose not to describe such findings, in which case the examination should be assessed as negative (category 1).

Note that both category 1 and category 2 assessments indicate that there is no mammographic evidence of malignancy. Both should be followed by the management recommendation for routine mammography screening. The difference is that category 2 should be used when describing one or more specific benign mammographic findings in the report, whereas category 1 should be used when no such findings are described (even if such findings are present).

[1] Mammography results are mandated to be reported using Final Assessment categories (Quality Mammography Standards: Final Rule. Federal Register. September 10, 2024).
[2] Terminology in this table is reflective of the American College of Radiology (ACR). ACR-BI-RADS®--5th Edition. ACR Breast Imaging Reporting and Data System, Breast Imaging Atlas; BI-RADS®. Reston, VA. American College of Radiology, 2014. For more information, see www.acr.org.
Reprinted with permission from the American College of Radiology. No other representation of this document is authorized without express, written permission from the American College of Radiology.

Note: All recommendations are category 2A unless otherwise indicated.

Version 1.2026, 03/05/26 © 2026 National Comprehensive Cancer Network® (NCCN®), All rights reserved. NCCN Guidelines® and this illustration may not be reproduced in any form without the express written permission of NCCN.

PLEASE NOTE that use of this NCCN Content is governed by the End-User License Agreement, and you MAY NOT distribute this Content or use it with any artificial intelligence model or tool.
Printed by Ambrish Chauhan on 5/1/2026 7:03:18 AM. Copyright © 2026 National Comprehensive Cancer Network, Inc. All Rights Reserved.

MAMMOGRAPHIC ASSESSMENT CATEGORY DEFINITIONS[1,2]

BI-RADS® - MAMMOGRAPHY FINDINGS

Category 3: Probably Benign:
A finding assessed using this category should have a ≤2% likelihood of malignancy, but greater than the essentially 0% likelihood of malignancy of a characteristically benign finding. A probably benign finding is not expected to change over the suggested period of imaging surveillance, but the interpreting physician prefers to establish stability of the finding before recommending management limited to routine mammography screening.
There are several prospective clinical studies demonstrating the safety and efficacy of periodic mammographic surveillance instead of biopsy for specific mammographic findings.
Three specific findings are validated as being probably benign (the noncalcified circumscribed solid mass, the focal asymmetry, and solitary group of punctate calcifications). All the previously cited studies emphasize the need to conduct a complete diagnostic imaging evaluation before making a probably benign (category 3) assessment; hence, it is recommended not to render such an assessment in interpreting a screening mammography examination. The practice of rendering category 3 assessments directly from screening examination also has been shown to result in adverse outcomes: 1) unnecessary follow-up of many lesions that could have been promptly assessed as benign; and 2) delayed diagnosis of a small number of cancers that otherwise may have been smaller in size and less likely to be advanced in stage. Also, all the previously cited studies exclude palpable lesions, so the use of a probably benign assessment for a palpable lesion is not supported by robust scientific data, although there are two single-institution studies that do report successful outcomes for palpable lesions. Finally, because evidence from previously cited studies indicates the need for biopsy rather than continued surveillance when a probably benign finding increases in size or extent, it is not prudent to render a category 3 assessment when a finding that otherwise meets "probably benign" imaging criteria is either new or has increased in size or extent.

While the vast majority of probably benign findings are managed with an initial short-interval follow-up (6-month) examination followed by additional examinations until long-term (2- or 3-year) stability is demonstrated, there may be occasions in which a biopsy is done instead (patient preference or overriding clinical concern).

[1] Mammography results are mandated to be reported using Final Assessment categories (Quality Mammography Standards: Final Rule. Federal Register. September 10, 2024).
[2] Terminology in this table is reflective of the American College of Radiology (ACR). ACR-BI-RADS®--5th Edition. ACR Breast Imaging Reporting and Data System, Breast Imaging Atlas; BI-RADS®. Reston, VA. American College of Radiology, 2014. For more information, see www.acr.org.
Reprinted with permission from the American College of Radiology. No other representation of this document is authorized without express, written permission from the American College of Radiology.

Note: All recommendations are category 2A unless otherwise indicated.

Version 1.2026, 03/05/26 © 2026 National Comprehensive Cancer Network® (NCCN®), All rights reserved. NCCN Guidelines® and this illustration may not be reproduced in any form without the express written permission of NCCN.

PLEASE NOTE that use of this NCCN Content is governed by the End-User License Agreement, and you MAY NOT distribute this Content or use it with any artificial intelligence model or tool.
Printed by Ambrish Chauhan on 5/1/2026 7:03:18 AM. Copyright © 2026 National Comprehensive Cancer Network, Inc. All Rights Reserved.

MAMMOGRAPHIC ASSESSMENT CATEGORY DEFINITIONS[1,2]

BI-RADS® - MAMMOGRAPHY FINDINGS

Category 4: Suspicious:
This category is reserved for findings that do not have the classic appearance of malignancy but are sufficiently suspicious to justify a recommendation for biopsy. The ceiling for category 3 assessment is a 2% likelihood of malignancy and the floor for category 5 assessment is 95%, so category 4 assessments cover the wide range of likelihood of malignancy in between. Thus, almost all recommendations of breast interventional procedures will come from assessments made using this category. By subdividing category 4[3] into 4A, 4B, and 4C, as recommended in Guidance chapter and using the cut point indicated therein, it is hoped that patients and referring clinicians will more readily make informed decisions on the ultimate course of action.

Category 5: Highly Suggestive of Malignancy:
These assessments carry a very high probability (≥95%) of malignancy. This category initially was established to involve lesions for which 1-stage surgical treatment was considered without preliminary biopsy, in an era when preoperative wire localization was the primary breast interventional procedure. Nowadays, given the widespread acceptance of imaging-guided percutaneous biopsy, 1-stage surgery is rarely, if ever, performed. Rather, current oncologic management almost always involves tissue diagnosis of malignancy via percutaneous tissue sampling to facilitate treatment options, such as when sentinel node biopsy is included in surgical management or when neoadjuvant chemotherapy is administered prior to surgery. Therefore, the current rationale for using a category 5 assessment is to identify lesions for which any non-malignant percutaneous tissue diagnosis is automatically considered discordant, resulting in the recommendation for repeat (usually surgical) biopsy.

Category 6: Known Biopsy - Proven Malignancy:
This category is reserved for examinations performed after biopsy proof of malignancy (imaging performed after percutaneous biopsy but prior to complete surgical excision) in which there are no mammographic abnormalities other than the known cancer that might need additional evaluation.

[1] Mammography results are mandated to be reported using Final Assessment categories (Quality Mammography Standards: Final Rule. Federal Register. September 10, 2024).
[2] Terminology in this table is reflective of the American College of Radiology (ACR). ACR-BI-RADS®--5th Edition. ACR Breast Imaging Reporting and Data System, Breast Imaging Atlas; BI-RADS®. Reston, VA. American College of Radiology, 2014. For more information, see www.acr.org.
[3] The BI-RADS® cut points for the risk of malignancy are as follows: 4A (>2% – ≤10%), 4B (>10% – ≤50%), 4C (>50% – <95%).
Reprinted with permission for the American College of Radiology. No other representation of this document is authorized without express, written permission from the American College of Radiology.

Note: All recommendations are category 2A unless otherwise indicated.

Version 1.2026, 03/05/26 © 2026 National Comprehensive Cancer Network® (NCCN®), All rights reserved. NCCN Guidelines® and this illustration may not be reproduced in any form without the express written permission of NCCN.

PLEASE NOTE that use of this NCCN Content is governed by the End-User License Agreement, and you MAY NOT distribute this Content or use it with any artificial intelligence model or tool.
Printed by Ambrish Chauhan on 5/1/2026 7:03:18 AM. Copyright © 2026 National Comprehensive Cancer Network, Inc. All Rights Reserved.

ULTRASOUND ASSESSMENT CATEGORY DEFINITIONS[1,2]

BI-RADS® - ULTRASOUND FINDINGS

A. Assessment Is Incomplete:
Category 0: Incomplete - Need Additional Imaging Evaluation:
There is a finding for which additional imaging evaluation is needed. This is almost always used in a screening situation. In this context, additional imaging evaluation includes the recording of (nonstandard) ultrasound images to supplement the standard images recorded for a screening examination. Note that this does not include repeat real-time scanning by the interpreting physician and/or colleague as long as additional images are not recorded. This respects the unique real-time nature of ultrasound and does not penalize its use.

Under certain circumstances, assessment category 0 may be used in a diagnostic ultrasound report, such as when equipment or personnel are not immediately available to perform a needed concurrent diagnostic mammography examination, or when the patient is unable or unwilling to wait for completion of a full diagnostic examination. Category 0 should not be used for diagnostic breast imaging findings that warrant further evaluation with MRI. Rather, the interpreting physician should issue a final assessment in a report that is made before the MRI examination is performed.

In most circumstances and when feasible, if a screening ultrasound examination is not assessed as negative or benign, the current examination should be compared to prior examination(s), if any exist. The interpreting physician should use judgment on how vigorously to attempt obtaining prior examinations, given the likelihood of success of such an endeavor and the likelihood that comparison will affect the final assessment. In this context, it is important to note that comparison to previous examination(s) may be irrelevant when a finding is inherently suspicious for malignancy.

Category 0 should be used for prior image comparison only when such comparison is required to make a final assessment. When category 0 is used in the context of awaiting prior examinations for comparison, there should be in place a tracking system guaranteeing with 100% reliability that a final assessment will be made within 30 days (preferably sooner), even if prior examinations do not become available. Some breast imaging practices may reasonably choose never to use category 0 in the context of awaiting prior examinations simply because they do not have a 100% reliable tracking system. If an ultrasound examination is assessed as category 0 in the context of awaiting prior examinations and then the prior examinations do become available, an addendum to the initial ultrasound report should be issued, including a revised assessment. For auditing purposes, the revised assessment should replace the initial assessment.

A need for previous studies to determine appropriate management might also temporarily defer a final assessment.

[1] Mammography results are mandated to be reported using Final Assessment categories (Quality Mammography Standards: Final Rule. Federal Register. September 10, 2024).
[2] Terminology in this table is reflective of the American College of Radiology (ACR). ACR-BI-RADS®--5th Edition. ACR Breast Imaging Reporting and Data System, Breast Imaging Atlas; BI-RADS®. Reston, VA. American College of Radiology, 2014. For more information, see www.acr.org.
Reprinted with permission from the American College of Radiology. No other representation of this document is authorized without express, written permission from the American College of Radiology.

Note: All recommendations are category 2A unless otherwise indicated.

Version 1.2026, 03/05/26 © 2026 National Comprehensive Cancer Network® (NCCN®), All rights reserved. NCCN Guidelines® and this illustration may not be reproduced in any form without the express written permission of NCCN.

PLEASE NOTE that use of this NCCN Content is governed by the End-User License Agreement, and you MAY NOT distribute this Content or use it with any artificial intelligence model or tool.
Printed by Ambrish Chauhan on 5/1/2026 7:03:18 AM. Copyright © 2026 National Comprehensive Cancer Network, Inc. All Rights Reserved.

ULTRASOUND ASSESSMENT CATEGORY DEFINITIONS[1,2]

BI-RADS® - ULTRASOUND FINDINGS

B. Assessment Is Complete — Final Categories:
Category 1: Negative:
There is nothing to comment on. This is a normal examination.

Category 2: Benign:
As with category 1, this is a "normal" assessment, but here the interpreter chooses to describe a benign finding in the ultrasound report. For example, the interpreter may choose to describe one or more simple cysts, intramammary lymph nodes, postsurgical fluid collections, breast implants, or complicated cysts/probable fibroadenomas that are unchanged for at least 2 or 3 years, while still concluding that there is no sonographic evidence of malignancy. On the other hand, the interpreter may choose not to describe such findings, in which case the examination should be assessed as negative (category 1).

Note that both category 1 and category 2 assessments indicate that there is no sonographic evidence of malignancy. Both should be followed by the management recommendation for routine age-appropriate screening. The difference is that category 2 should be used when describing one or more specific benign sonographic findings in the report, whereas category 1 should be used when no such findings are described (even if such findings are present).

[1] Mammography results are mandated to be reported using Final Assessment categories (Quality Mammography Standards: Final Rule. Federal Register. September 10, 2024).
[2] Terminology in this table is reflective of the American College of Radiology (ACR). ACR-BI-RADS®--5th Edition. ACR Breast Imaging Reporting and Data System, Breast Imaging Atlas; BI-RADS®. Reston, VA. American College of Radiology, 2014. For more information, see www.acr.org.
Reprinted with permission from the American College of Radiology. No other representation of this document is authorized without express, written permission from the American College of Radiology.

Note: All recommendations are category 2A unless otherwise indicated.

Version 1.2026, 03/05/26 © 2026 National Comprehensive Cancer Network® (NCCN®), All rights reserved. NCCN Guidelines® and this illustration may not be reproduced in any form without the express written permission of NCCN.

PLEASE NOTE that use of this NCCN Content is governed by the End-User License Agreement, and you MAY NOT distribute this Content or use it with any artificial intelligence model or tool.
Printed by Ambrish Chauhan on 5/1/2026 7:03:18 AM. Copyright © 2026 National Comprehensive Cancer Network, Inc. All Rights Reserved.

ULTRASOUND ASSESSMENT CATEGORY DEFINITIONS[1,2]

BI-RADS® - ULTRASOUND FINDINGS

Category 3: Probably Benign:
Assessment category 3, probably benign, is not an indeterminate category for use simply when the radiologist is unsure whether to render a benign (BI-RADS® category 2) or suspicious (BI-RADS® category 4) assessment, but is one that is reserved for specific imaging findings known to have >0% but ≤2% likelihood of malignancy. For ultrasound, there is robust evidence that a solid mass with a circumscribed margin, oval shape, and parallel orientation (most commonly fibroadenoma) and an isolated complicated cyst have a likelihood of malignancy in the defined (≤2%), probably benign range, for which short-interval (6-month) follow-up sonography and then periodic sonographic surveillance may represent appropriate management. Similar data have been reported for clustered microcysts, but these data are less strong because they involve much fewer cases. The use of assessment category 3 for sonographic findings other than these three should be considered only if the radiologist has personal experience to justify a watchful-waiting approach, preferably involving observation of a sufficient number of cases of an additional sonographic finding to suggest a likelihood of malignancy within the defined (≤2%), probably benign range.

This edition of the BI-RADS® Atlas also emphasizes the recommendation that a category 3 assessment should not be made at screening; rather, this should be done only after completion of full diagnostic breast imaging examination. This recommendation is appropriate for screening mammography, for which batch interpretation usually is utilized, because in this setting there is no opportunity to complete the diagnostic workup before interpreting the screening examination. However, screening ultrasound almost always is interpreted online, so a full diagnostic examination also is completed while the patient remains in the breast imaging facility, and a single breast imaging report may be issued that combines the findings of both screening and diagnostic components of the examination. Hence, there is no purpose in recommending against category 3 assessment at screening ultrasound, because the diagnostic workup would be completed simultaneously. Note that for auditing purposes, the screening component of a category 3-assessed screening ultrasound examination will be audit-positive, not only because additional nonstandard (diagnostic) images will be recorded but also because a category 3 assessment at screening is defined as being audit-positive.

[1] Mammography results are mandated to be reported using Final Assessment categories (Quality Mammography Standards: Final Rule. Federal Register. September 10, 2024).
[2] Terminology in this table is reflective of the American College of Radiology (ACR). ACR-BI-RADS®--5th Edition. ACR Breast Imaging Reporting and Data System, Breast Imaging Atlas; BI-RADS®. Reston, VA. American College of Radiology, 2014. For more information, see www.acr.org.
Reprinted with permission from the American College of Radiology. No other representation of this document is authorized without express, written permission from the American College of Radiology.

Note: All recommendations are category 2A unless otherwise indicated.

Version 1.2026, 03/05/26 © 2026 National Comprehensive Cancer Network® (NCCN®), All rights reserved. NCCN Guidelines® and this illustration may not be reproduced in any form without the express written permission of NCCN.

PLEASE NOTE that use of this NCCN Content is governed by the End-User License Agreement, and you MAY NOT distribute this Content or use it with any artificial intelligence model or tool.
Printed by Ambrish Chauhan on 5/1/2026 7:03:18 AM. Copyright © 2026 National Comprehensive Cancer Network, Inc. All Rights Reserved.

ULTRASOUND ASSESSMENT CATEGORY DEFINITIONS[1,2]

BI-RADS® - ULTRASOUND FINDINGS

For category 3 assessments, the initial short-term follow-up interval is usually 6 months and involves the breast(s) containing the probably benign finding(s). Assuming stability at this 6-month examination, a category 3 assessment again is rendered with a management recommendation for a second short-interval follow-up examination in 6 months. Again assuming stability at this second short-interval follow-up, the examination is once more assessed as category 3, but now the recommended follow-up interval usually is lengthened to 1 year due the already-observed 12-month stability. Note that although the 1-year follow-up coincides with the routine screening interval in the United States, a category 3 assessment is rendered to indicate that the period of imaging surveillance is still underway. As with surveillance using mammography, after 2 to 3 years of stability, the final assessment category should be changed to benign (BI-RADS® category 2). A benign evaluation may also be rendered before completion of category 3 analysis if, in the opinion of the interpreter, the finding has no chance of malignancy and is thus a category 2.

Category 4: Suspicious:
This category is reserved for findings that do not have the classic appearance of malignancy but are sufficiently suspicious to justify a recommendation for biopsy. The ceiling for category 3 assessment is a 2% likelihood of malignancy, and the floor for category 5 assessment is 95%, so category 4 assessments cover the wide range of likelihood of malignancy in between. Thus, almost all recommendations for breast interventional procedures will come from assessments made using this category. By subdividing category 4[3] into 4A, 4B, and 4C, it is hoped that patients and referring clinicians will more readily make informed decisions on the ultimate course of action.

[1] Mammography results are mandated to be reported using Final Assessment categories (Quality Mammography Standards: Final Rule. Federal Register. September 10, 2024).
[2] Terminology in this table is reflective of the American College of Radiology (ACR). ACR-BI-RADS®--5th Edition. ACR Breast Imaging Reporting and Data System, Breast Imaging Atlas; BI-RADS®. Reston, VA. American College of Radiology, 2014. For more information, see www.acr.org.
[3] The BI-RADS® cut points for the risk of malignancy are as follows: 4A (>2% – ≤10%), 4B (>10% – ≤50%), 4C (>50% – <95%).
Reprinted with permission from the American College of Radiology. No other representation of this document is authorized without express, written permission from the American College of Radiology.

Note: All recommendations are category 2A unless otherwise indicated.

Version 1.2026, 03/05/26 © 2026 National Comprehensive Cancer Network® (NCCN®), All rights reserved. NCCN Guidelines® and this illustration may not be reproduced in any form without the express written permission of NCCN.

PLEASE NOTE that use of this NCCN Content is governed by the End-User License Agreement, and you MAY NOT distribute this Content or use it with any artificial intelligence model or tool.
Printed by Ambrish Chauhan on 5/1/2026 7:03:18 AM. Copyright © 2026 National Comprehensive Cancer Network, Inc. All Rights Reserved.

ULTRASOUND ASSESSMENT CATEGORY DEFINITIONS[1,2]

BI-RADS® - ULTRASOUND FINDINGS

Category 5: Highly Suggestive of Malignancy:
These assessments carry a very high probability (≥95%) of malignancy. This category initially was established to involve lesions for which 1-stage surgical treatment could be considered without preliminary biopsy in an era when preoperative wire localization was the primary breast interventional procedure. Nowadays, given the widespread acceptance of imaging-guided percutaneous biopsy, 1-stage surgery rarely, if ever, is performed. Rather, current oncologic management almost always involves tissue diagnosis of malignancy via percutaneous tissue sampling to facilitate treatment options, such as when sentinel node imaging is included in surgical management or when neoadjuvant chemotherapy is administered prior to surgery. Therefore, the current rationale for using a category 5 assessment is to identify lesions for which any nonmalignant percutaneous tissue diagnosis is considered discordant, resulting in the recommendation for repeat (usually vacuum-assisted or surgical) biopsy. Also note that whereas the fourth edition simply indicated that "appropriate action should be taken" as management for category 5 assessments, the fifth edition provides the more directed management recommendation that "biopsy should be performed in the absence of clinical contraindication." This new text unequivocally specifies tissue diagnosis as the interpreting physician's management recommendation for category 5 assessments, appropriately and effectively transferring the burden of establishing a contraindication to this recommendation to the referring clinician.

Category 6: Known Biopsy-Proven Malignancy:
This category is reserved for examinations performed after biopsy proof of malignancy (imaging performed after percutaneous biopsy but prior to surgical excision), in which there are no abnormalities other than the known cancer that might need additional evaluation.

[1] Mammography results are mandated to be reported using Final Assessment categories (Quality Mammography Standards: Final Rule. Federal Register. September 10, 2024).
[2] Terminology in this table is reflective of the American College of Radiology (ACR). ACR-BI-RADS®--5th Edition. ACR Breast Imaging Reporting and Data System, Breast Imaging Atlas; BI-RADS®. Reston, VA. American College of Radiology, 2014. For more information, see www.acr.org.
Reprinted with permission from the American College of Radiology. No other representation of this document is authorized without express, written permission from the American College of Radiology.

Note: All recommendations are category 2A unless otherwise indicated.

Version 1.2026, 03/05/26 © 2026 National Comprehensive Cancer Network® (NCCN®), All rights reserved. NCCN Guidelines® and this illustration may not be reproduced in any form without the express written permission of NCCN.

PLEASE NOTE that use of this NCCN Content is governed by the End-User License Agreement, and you MAY NOT distribute this Content or use it with any artificial intelligence model or tool.
Printed by Ambrish Chauhan on 5/1/2026 7:03:18 AM. Copyright © 2026 National Comprehensive Cancer Network, Inc. All Rights Reserved.

ABBREVIATIONS

2D	two-dimensional
ADH	atypical ductal hyperplasia
ALH	atypical lobular hyperplasia
AMAB	assigned male at birth
BCSC	Breast Cancer Surveillance Consortium
BIA-ALC	breast implant-associated anaplastic large cell lymphoma
BIA-SCC	breast implant-associated squamous cell carcinoma
BI-RADS	Breast Imaging Reporting and Data System
CBE	clinical breast examination
CDR	cancer detection rate
CEM	contrast-enhanced mammography
FEA	flat epithelial atypia
HIV	human immunodeficiency virus
LCIS	lobular carcinoma in situ
MBI	molecular breast imaging
PABC	pregnancy-associated breast cancer

Version 1.2026, 03/05/26 © 2026 National Comprehensive Cancer Network® (NCCN®), All rights reserved. NCCN Guidelines® and this illustration may not be reproduced in any form without the express written permission of NCCN.

PLEASE NOTE that use of this NCCN Content is governed by the End-User License Agreement, and you MAY NOT distribute this Content or use it with any artificial intelligence model or tool.
Printed by Ambrish Chauhan on 5/1/2026 7:03:18 AM. Copyright © 2026 National Comprehensive Cancer Network, Inc. All Rights Reserved.

NCCN Categories of Evidence and Consensus	
Category 1	Based upon high-level evidence (≥1 randomized phase 3 trials or high-quality, robust meta-analyses), there is uniform NCCN consensus (≥85% support of the Panel) that the intervention is appropriate.
Category 2A	Based upon lower-level evidence, there is uniform NCCN consensus (≥85% support of the Panel) that the intervention is appropriate.
Category 2B	Based upon lower-level evidence, there is NCCN consensus (≥50%, but <85% support of the Panel) that the intervention is appropriate.
Category 3	Based upon any level of evidence, there is major NCCN disagreement that the intervention is appropriate.

All recommendations are category 2A unless otherwise indicated.

Note: All recommendations are category 2A unless otherwise indicated.

Version 1.2026, 03/05/26 © 2026 National Comprehensive Cancer Network® (NCCN®), All rights reserved. NCCN Guidelines® and this illustration may not be reproduced in any form without the express written permission of NCCN.

PLEASE NOTE that use of this NCCN Content is governed by the End-User License Agreement, and you MAY NOT distribute this Content or use it with any artificial intelligence model or tool.
Printed by Ambrish Chauhan on 5/1/2026 7:03:18 AM. Copyright © 2026 National Comprehensive Cancer Network, Inc. All Rights Reserved.

Discussion

This discussion corresponds to the NCCN Guidelines for Breast Cancer Screening and Diagnosis. Last updated: March 5th, 2026.

Table of Contents

Overview 2
Guidelines Update Methodology 2
Literature Search Criteria 2
Sensitive/Inclusive Language Usage 2
Breast Screening Components 3
- Clinical Encounter 3
- Breast Awareness 4
- Breast Cancer Risk Assessment 4
- Breast Imaging Modalities 5

Screening Recommendations for Individuals at Average Risk of Breast Cancer 7
- Those with Average Risk Between 25 and 39 Years of Age 7
- Those with Average Risk ≥40 Years of Age 8
- Rationale for Mammographic Screening Starting at 40 Years of Age 8
- Screening Interval and Rationale for Annual Mammogram Screening 12

Screening Recommendations for Individuals at Increased Risk of Breast Cancer 13
- Those with a Known Genetic Predisposition or Pedigree Suggestive of a Genetic Predisposition 13
- Those with a Lifetime Risk of Breast Cancer ≥20% Based on Models That Include a Comprehensive Family History 13
- Those Who Have Received Prior Irradiation with Exposure to Breast Tissue Between 10 and 30 Years of Age 14
- Individuals ≥35 Years of Age with a 5-Year Risk of Invasive Breast Carcinoma ≥1.7% by the Modified Gail Model or as Calculated by an Imaging-Based Risk Assessment Model 15
- Those with a History of ADH or Lobular Neoplasia (LCIS/ALH) 16
- Mammographic Breast Density (Heterogeneously or Extremely Dense Breasts) in Patients Who Do Not Meet any Other Increased Risk Category 16

Diagnostic Evaluation 17
- Diagnostic Imaging After Screening Mammography Recall 18
- Breast Tissue Biopsy 20
- Diagnostic Evaluation for Symptomatic Findings on Physical Examination 21
- Mammographic and/or Ultrasound Findings Corresponding to Palpable Symptom 22
- Presentation of Signs and Symptoms in Individuals Assigned Male at Birth 29

Breast Imaging During Pregnancy and Lactation 30
- Breast Cancer Screening During Pregnancy and Lactation 31
- Management of Breast Signs and Symptoms During Pregnancy and Lactation 31

Summary 33
References 35

Version 1.2026 © 2026 National Comprehensive Cancer Network© (NCCN©), All rights reserved. NCCN Guidelines® and this illustration may not be reproduced in any form without the express written permission of NCCN.

PLEASE NOTE that use of this NCCN Content is governed by the End-User License Agreement, and you MAY NOT distribute this Content or use it with any artificial intelligence model or tool.
Printed by Ambrish Chauhan on 5/1/2026 7:03:18 AM. Copyright © 2026 National Comprehensive Cancer Network, Inc. All Rights Reserved.

Overview

The average lifetime risk of breast cancer for a female in the United States has been estimated at 12.3% (or 1 in 8 females).[1] For 2026, the American Cancer Society (ACS) estimates that 324,580 cases of invasive breast cancer (321,910 in females and 2670 in males) and 60,730 cases of carcinoma in situ of the breast in females will be diagnosed in the United States.[2] About 42,670 breast cancer-related deaths are estimated for 2026.[2] While breast cancer incidence rates increased by 0.5% each year from 2010 through 2019, mortality rates declined, falling an average of 1.3% each year from 2011 to 2020.[3] This decrease has been attributed to a combination of screening and treatment advances.[4]

The NCCN Clinical Practice Guidelines in Oncology (NCCN Guidelines®) for Breast Cancer Screening and Diagnosis are for facilitating clinical decision-making. The general public and health care providers (HCPs) need to be aware that mammography with tomosynthesis or any other imaging modality is not a stand-alone procedure. Neither the current technology of mammography with tomosynthesis or other imaging tests nor the subsequent interpretation of such tests is foolproof. Clinical judgment is needed to ensure appropriate management. The patient's concerns and physical findings must be taken into account along with imaging results and histologic assessment.

Guidelines Update Methodology

The complete details of the Development and Update of the NCCN Guidelines are available at www.NCCN.org.

Literature Search Criteria

Prior to the update of the NCCN Guidelines® for Breast Cancer Screening and Diagnosis, an electronic search of the PubMed database was performed to obtain key literature in Breast Cancer Screening and Diagnosis published since the previous Guidelines updates, using the following search terms: breast cancer screening; screening mammography; breast cancer diagnosis; tomosynthesis; breast MRI; contrast-enhanced mammography (CEM); or molecular breast imaging (MBI). The PubMed database was chosen as it remains the most widely used resource for medical literature and indexes peer-reviewed biomedical literature.[5] Results were confined to the following article types: Clinical Trial, Phase II; Clinical Trial, Phase III; Clinical Trial, Phase IV; Guideline; Practice Guideline; Randomized Controlled Trial; Meta-Analysis; Systematic Reviews; and Validation Studies.

The data from key PubMed articles as well as articles from additional sources deemed as relevant to these Guidelines as discussed by the Panel have been included in this version of the Discussion section. Recommendations for which high-level evidence is lacking are based on the Panel's review of lower-level evidence and expert opinion.

Sensitive/Inclusive Language Usage

NCCN Guidelines strive to use language that advances the goals of equity, inclusion, and representation. NCCN Guidelines endeavor to use language that is person-first; not stigmatizing; anti-racist, anti-classist, anti-misogynist, anti-ageist, anti-ableist, and anti-weight-biased; and inclusive of individuals of all sexual orientations and gender identities. NCCN Guidelines incorporate non-gendered language, instead focusing on organ-specific recommendations. This language is both more accurate and more inclusive and can help fully address the needs of individuals of all sexual orientations and gender identities. NCCN Guidelines will continue to use the terms men, women, female, and male when citing statistics, recommendations, or data from organizations or sources that do not use inclusive terms. Most studies do not report how sex and gender data are collected and use these terms interchangeably or inconsistently. If sources do not differentiate gender from sex assigned at birth or organs present, the information is presumed to predominantly represent cisgender

Version 1.2026 © 2026 National Comprehensive Cancer Network© (NCCN©), All rights reserved. NCCN Guidelines® and this illustration may not be reproduced in any form without the express written permission of NCCN.

PLEASE NOTE that use of this NCCN Content is governed by the End-User License Agreement, and you MAY NOT distribute this Content or use it with any artificial intelligence model or tool.
Printed by Ambrish Chauhan on 5/1/2026 7:03:18 AM. Copyright © 2026 National Comprehensive Cancer Network, Inc. All Rights Reserved.

individuals. NCCN encourages researchers to collect more specific data in future studies and organizations to use more inclusive and accurate language in their future analyses.

Breast Screening Components

Breast screening is performed in individuals without any signs or symptoms of breast cancer so that disease can be detected as early as possible. Earlier disease detection may decrease the overall treatment needed and reduces morbidity and mortality rates. Diagnostic breast evaluation and imaging differ from breast screening in that they are used to evaluate an existing problem (eg, palpable mass, discharge from the nipple, mammographic finding). NCCN screening recommendations are largely intended for individuals assigned female at birth with residual native breast tissue due to the preponderance of data in this population. There are limited data on screening in individuals assigned male at birth, though consideration should be made for screening individuals assigned male at birth on feminizing hormones. For breast cancer screening of transgender individuals, the NCCN Panel endorses the consensus-based guidelines developed by the American College of Radiology (ACR) Appropriateness Criteria.[6] Transgender individuals should consult with their primary care provider to determine when and/or whether screening would be appropriate.

The components of a breast screening evaluation are dependent on age and other factors such as medical and family history, and can include breast awareness (ie, familiarity with one's own breasts); regular clinical encounters, which include breast cancer risk assessment and clinical breast exam (CBE); breast imaging with screening mammography with tomosynthesis; and, in selected cases, breast MRI with and without contrast or breast ultrasound.

Clinical Encounter

The starting point of these guidelines for screening and evaluating breast abnormalities is a clinical encounter, which includes at a minimum, a medical history and family history followed by breast cancer risk assessment, risk reduction counseling, and preferably a CBE even in asymptomatic individuals when feasible. The frequency of the clinical encounter depends on the age and risk assessment of the patient (see *Clinical Encounter Including Risk Assessment* in the algorithm).

The rationale for recommending the clinical encounter is to maximize the earliest detection of breast cancers and to ensure ongoing risk assessment, particularly in regions where mammographic screening may not be easily accessible. In a review of controlled trials and case-control studies that included CBE as part of the screening modality, sensitivity of CBE was found to be 54% and specificity 94%.[7] While randomized trials comparing incremental CBE versus mammographic screening have not been performed, a study based in Mumbai, India comparing CBE and cancer awareness information to no screening revealed that the addition of CBE and cancer awareness information led to an earlier age at breast cancer diagnosis, a significant reduction in breast cancers diagnosed at stages III or IV, a non-significant reduction in mortality of 15% in the overall study population (ages 35–64 years), as well as a significant relative reduction in mortality of nearly 30% in individuals >50 years of age.[8]

Overdiagnosis and overtreatment is not a significant issue with CBE, as the majority of palpable cancers found on a CBE are invasive cancers. CBE is an important component of a clinical encounter and is important in order to detect early-stage palpable cancers, especially those that are mammographically occult (eg, lobular carcinomas). Inspection of the breasts should be performed with the patient in both upright and supine positions and should include palpation of all components of the breast

Version 1.2026 © 2026 National Comprehensive Cancer Network© (NCCN©), All rights reserved. NCCN Guidelines® and this illustration may not be reproduced in any form without the express written permission of NCCN.

PLEASE NOTE that use of this NCCN Content is governed by the End-User License Agreement, and you MAY NOT distribute this Content or use it with any artificial intelligence model or tool.
Printed by Ambrish Chauhan on 5/1/2026 7:03:18 AM. Copyright © 2026 National Comprehensive Cancer Network, Inc. All Rights Reserved.

(lateral-medial: from mid-axillary line to sternum; cephalad-caudad: from clavicle to inframammary ridge), axilla, and clavicular lymph node basins. Positioning may be done so as to elicit any subtle shape or contour changes in the breast.[7] Time spent on the palpable portion of the exam is associated with increased detection of palpable abnormalities. It is critical for the location of any physical findings from a CBE to be documented, as clock/quadrant location and distance from nipple to facilitate geographic correlation with imaging findings.

Breast Awareness

Individuals should be familiar with their breasts and any changes to them.[9,10] Data from a large, randomized trial of breast self-examination (BSE) screening have shown that instruction in BSE has no effect on reducing breast cancer mortality. In this study, 266,064 females of Chinese descent who were not undergoing routine mammographic screening were randomized to either receive instruction in BSE or not.[11] Adherence was encouraged through feedback and reinforcement sessions. After 10 to 11 years of follow-up, 135 breast cancer deaths in the group that received instruction and 131 in the control group were observed. The cumulative breast cancer mortality rates were not significantly different between the two arms (relative risk [RR], 1.04; 95% CI, 0.82–1.33; $P = .72$). The number of benign breast lesions detected in the BSE instruction group was higher than that detected in the control group. Nevertheless, individuals should be encouraged to be aware of their breasts since this may facilitate detection of interval cancers between routine screenings. The NCCN Panel recommends breast awareness, specifically that all individuals should be familiar with their breasts and promptly report any changes to their HCP.

Breast Cancer Risk Assessment

If the physical examination is negative in an asymptomatic individual, the next decision point is based on risk stratification. Individuals should undergo breast cancer risk assessment by 25 years of age and be counseled regarding potential benefits, risks, and limitations of breast screening in the context of their risk stratification. Shared decision-making is encouraged based on a patient's values and preferences. Known breast density should be factored into risk assessment if available from a prior mammogram.

Individuals are stratified into two basic categories of risk for the purpose of screening recommendations: average risk and increased risk of developing breast cancer. Risk assessment is outlined in the NCCN Guidelines for Breast Cancer Risk Reduction (available at www.NCCN.org). The increased risk category consists of seven groups: 1) those with a known genetic predisposition or a pedigree suggestive of a genetic predisposition; 2) those who have a lifetime risk ≥20% as defined by models that include a comprehensive family history, including first, second, and, when included in the model, third degree relatives (eg, BRCAPRO,[12] Tyrer-Cuzick,[13] Breast and Ovarian Analysis of Disease Incidence and Carrier Estimation Algorithm [BOADICEA]/CanRisk,[14] Breast Cancer Surveillance Consortium [BCSC] Invasive Breast Cancer Risk Calculator[15]); 3) those that received prior radiation therapy (RT) with exposure to breast tissue between the ages of 10 and 30 years (eg, mantle irradiation); 4) those ≥35 years of age with a 5-year risk of invasive breast cancer ≥1.7% (per Gail Model); 5) those with a 5-year risk of invasive breast cancer ≥1.7% as calculated by an imaging-based risk assessment model; 6) those with a history of atypical ductal hyperplasia (ADH) or lobular neoplasia (lobular carcinoma in situ [LCIS] or atypical lobular hyperplasia [ALH]); 7) those with mammographic breast density (heterogenously or extremely dense breasts) who do not meet any other increased risk category.

Some veterans may now qualify for additional breast cancer risk assessment and/or mammography screening per the Dr. Kate Hendricks

Version 1.2026 © 2026 National Comprehensive Cancer Network© (NCCN©), All rights reserved. NCCN Guidelines® and this illustration may not be reproduced in any form without the express written permission of NCCN.

PLEASE NOTE that use of this NCCN Content is governed by the End-User License Agreement, and you MAY NOT distribute this Content or use it with any artificial intelligence model or tool.
Printed by Ambrish Chauhan on 5/1/2026 7:03:18 AM. Copyright © 2026 National Comprehensive Cancer Network, Inc. All Rights Reserved.

Thomas Supporting Expanded Review for Veterans in Combat Environments Act, also called the Dr. Kate Hendricks Thomas SERVICE Act 2022.[16]

Breast Imaging Modalities

Screening Mammography

Of the various imaging modalities, mammography remains the most important as it is the only one to demonstrate a mortality reduction. A screening mammogram typically involves two x-ray images of each breast (ie, one taken from the top [craniocaudal] of the breast and the other from the side [mediolateral oblique]). Technical aspects of mammography can affect the quality of screening results. Digital mammography, which has replaced film-screen mammography in the United States, generates an electronic image of the breast and allows for computer storage and processing of the image, thereby increasing the ability to detect subtle abnormalities.[17,18]

In a study of 49,528 females who underwent both film and digital mammography, no difference was seen in the overall accuracy of the two procedures.[19,20] However, digital mammography was significantly more accurate in females <50 years of age with dense breasts, and there was a nonsignificant trend toward improved accuracy of film mammography in females ≥65 years of age. In another trial of females aged 45 to 69 years randomly assigned to film or digital screening mammography, the latter procedure was shown to result in a higher rate of cancer detection.[21]

More recently, combined use of digital mammography (two-dimensional, 2D) in conjunction with tomosynthesis improves cancer detection and reduces false-positive call-back rates,[22-34] including for those with dense breasts.[35,36] Tomosynthesis allows acquisition of multiple low-dose x-ray images across a limited arc and a digital detector. These data are reconstructed using computer algorithms to generate thin sections displayed in a quasi-3D format. The combined use of 2D and tomosynthesis results in double the radiation exposure compared with mammography alone. However, this increase in radiation dose falls below the dose limits of radiation set by the U.S. Food and Drug Administration (FDA) for standard mammography. The radiation dose can be minimized by newer tomosynthesis techniques that create a synthetic 2D image from the tomosynthesis acquisition, which may obviate the need for a conventional digital image.[23,37,38] A meta-analysis comparing the use of synthetic 2D mammography rather than standard 2D digital mammography with tomosynthesis revealed comparable diagnostic accuracy, with 85% versus 84% sensitivity and 93% versus 91% specificity, respectively.[39]

Screening Ultrasound

Due to limitations of mammographic screening, especially in those with dense breasts, other imaging modalities are being explored to supplement mammography, including ultrasound, MRI, CEM, and MBI. Unlike mammographic screening, these technologies lack evidence from randomized controlled trials (RCTs) of screening efficacy, although ultrasound is widely used in the diagnostic setting. Most clinical ultrasound screening studies have found increased cancer detection to be incremental to screening mammograms in females with dense breasts; however, they may increase recall and benign breast biopsies. For example, a large prospective study in females with dense breasts and elevated risk for breast cancer found that adding screening ultrasound to mammography identified an additional 4.3 cancers per 1000 females screened (95% CI, 1.1–7.2 cancers per 1000) but increased the number of false-positive results.[40] Subsequent follow-up studies showed similar results.[41,42] However, in females with dense breasts, the mammographic sensitivity was found to be 50% (95% CI, 33.8%–66.2%) and the sensitivity of mammography plus ultrasound was 77.5% (95% CI, 61.6%–

Version 1.2026 © 2026 National Comprehensive Cancer Network© (NCCN©), All rights reserved. NCCN Guidelines® and this illustration may not be reproduced in any form without the express written permission of NCCN.

PLEASE NOTE that use of this NCCN Content is governed by the End-User License Agreement, and you MAY NOT distribute this Content or use it with any artificial intelligence model or tool.
Printed by Ambrish Chauhan on 5/1/2026 7:03:18 AM. Copyright © 2026 National Comprehensive Cancer Network, Inc. All Rights Reserved.

89.2%).[40] Application of screening ultrasound to females with dense breasts in clinical populations has produced similar results.[43]

Although there is increasing evidence that breast ultrasonography can be useful in the incremental detection of breast cancer as an adjunct to screening mammography in the evaluation of females with dense breasts,[40,41,44-46] the routine use of ultrasound as a universal supplemental *screening* test in individuals at average risk of breast cancer is *not* recommended by the NCCN Panel at this time. Ultrasonography is commonly used for *diagnostic* follow-up of an abnormality seen on screening mammography and palpable clinical concerns. Additionally, a recent direct comparison trial revealed that whole breast ultrasound had an approximately 4 times lower cancer detection rate compared to MRI in patients with dense breasts.[47]

Screening MRI

The sensitivity of contrast-enhanced breast MRI at detecting breast cancer is higher than the sensitivity of mammography, although the specificity of the former procedure is often lower, resulting in a higher rate of false-positive findings.[48] In addition, microcalcifications are not detectable with MRI.[49,50] Similar to screening ultrasound, whether MRI screening impacts survival has not been addressed in randomized clinical trials. Therefore, careful patient selection for additional screening with MRI is needed. Although current evidence does not support the use of breast MRI to screen females at average risk of breast cancer, the benefits of screening MRI for early detection of breast cancer in females at high risk of breast cancer, such as those ages 10 through 30 years with a history of prior thoracic radiation, a known genetic predisposition for breast cancer, or a strong family history of the disease have been demonstrated in multiple studies.[51-59] The ACS has published guidelines recommending use of breast MRI as an adjunct to screening mammography in certain populations of females at high risk of breast cancer.[60] Nevertheless, a high false-positive rate for screening MRI was identified in several studies. For example, in one study of females at high risk of breast cancer, many of whom were young (age range of entire cohort, 35–49 years) and had very dense breast tissue, screening MRI led to 3 times as many benign biopsies as mammography.[61]

A single retrospective study of asymptomatic females with atypical hyperplasia or LCIS enrolled in a high-risk screening program has evaluated use of MRI in this population.[62] Approximately half of the females underwent screening with mammography and MRI, whereas the other half was screened with mammography alone. For those undergoing both types of screening, MRI detected breast cancer in 4% of patients with LCIS who had negative mammogram results. MRI screening did not affect the rate of cancer detection in females with atypical hyperplasia. Females who underwent screening with MRI were more likely to be younger and premenopausal, and to have a stronger family history of breast cancer than those who were evaluated by mammography alone. However, only one female with cancer detected by MRI following a negative mammography finding had reported a family history of breast cancer, and no difference was seen in the percentages of patients who ultimately developed cancer in the two groups.

Studies have reported that deposits of gadolinium, a component of MRI contrast agents, remain in the brain of some patients who undergo four or more contrast MRI scans, long after the last administration.[63-66] Retention of gadolinium has also been seen in the bone.[67,68] The clinical significance and practice implications of these observations are unclear and are being investigated. In 2015, the FDA issued a safety warning alerting that investigations were ongoing for the risk associated with gadolinium deposits in the brain following its repeated use with MRI. In 2017, the FDA issued an update stating that its review of available data had not identified

Version 1.2026 © 2026 National Comprehensive Cancer Network© (NCCN©), All rights reserved. NCCN Guidelines® and this illustration may not be reproduced in any form without the express written permission of NCCN.

PLEASE NOTE that use of this NCCN Content is governed by the End-User License Agreement, and you MAY NOT distribute this Content or use it with any artificial intelligence model or tool.
Printed by Ambrish Chauhan on 5/1/2026 7:03:18 AM. Copyright © 2026 National Comprehensive Cancer Network, Inc. All Rights Reserved.

adverse health effects from gadolinium retained in the brain.[69] Patients will be asked to read a medication guide prior to receiving gadolinium.

Abbreviated MRI has a higher cancer detection rate than mammogram with tomosynthesis among individuals with dense breasts[70] and meta-analyses comparing abbreviated versus full protocol MRI revealed similar sensitivity and specificity between the two modalities.[71,72]

In individuals with a genetic mutation, or an untested first-degree relative of a gene mutation carrier, or those with a history of radiation with exposure to breast tissue between ages 10 and 30 years, or a lifetime risk of ≥20% based on models such as BRCAPRO, Tyrer-Cuzick, BOADICEA/CanRisk, or the BCSC Invasive Breast Cancer Risk Calculator, based on current evidence, the NCCN Panel continues to recommend an annual MRI with and without contrast as an adjunct to mammography with tomosynthesis. Individuals with LCIS or ALH/ADH with a lifetime risk of ≥20% should be considered for breast MRI with and without contrast based on emerging evidence of the benefits.

Criteria for the performance/interpretation of high-quality breast MRI include a dedicated breast coil, radiologists experienced in breast MRI, the ability to perform MRI-guided needle sampling and/or wire localization of MRI-detected findings, and regional availability. MRI findings should be correlated with findings from other breast imaging modalities. The ACR has published guidelines for the performance of contrast-enhanced MRI of the breast.[73]

Other Breast Imaging Modalities

CEM and MBI are also options for high-risk breast cancer screening in those who cannot undergo breast MRI; however, these studies may increase recalls and benign breast biopsies.

There is emerging evidence that CEM may improve detection of early breast cancers among females with mammographically dense breasts.[47,74,75] CEM carries a risk of iodinated contrast reactions, though a systematic review revealed a pooled rate of adverse events of only 0.82%.[76] CEM also has a higher breast radiation exposure per exam than standard mammography, though the radiation dose remains below the dose limits set by the FDA for standard mammography.[76,77]

Limited data exist regarding the use of MBI for breast cancer screening; however, screening MBI has similar sensitivity but improved specificity compared to ultrasound in studies with individuals with dense breasts.[78-81] Additionally, MBI has a whole-body effective radiation dose higher than that of mammography.[78]

Thermography and ductal lavage are *not* recommended by the NCCN Panel for breast cancer screening or diagnosis. The FDA has issued a safety alert stating that ductal lavage should not be a replacement for mammograms.[82]

Screening Recommendations for Individuals at Average Risk of Breast Cancer

The NCCN Panel recognizes that the primary purpose of screening individuals with average risk for developing breast cancer is to detect breast cancer early, which allows treatment to decrease mortality and morbidity associated with breast cancer.

Those with Average Risk Between 25 and 39 Years of Age

The NCCN Panel recommends a clinical encounter, which includes ongoing breast cancer risk assessment, risk reduction counseling, as well as a CBE every 1 to 3 years, and encouraging individuals to be aware of their breasts and promptly report any changes to their HCP. Although the screening CBE by itself does not rule out disease, the high specificity of certain abnormal findings by highly qualified clinicians increases the

Version 1.2026 © 2026 National Comprehensive Cancer Network© (NCCN©), All rights reserved. NCCN Guidelines® and this illustration may not be reproduced in any form without the express written permission of NCCN.

PLEASE NOTE that use of this NCCN Content is governed by the End-User License Agreement, and you MAY NOT distribute this Content or use it with any artificial intelligence model or tool.
Printed by Ambrish Chauhan on 5/1/2026 7:03:18 AM. Copyright © 2026 National Comprehensive Cancer Network, Inc. All Rights Reserved.

probability of finding certain breast cancers (eg, lobular carcinoma). The NCCN Panel believes that a clinical encounter provides an opportunity for providers to perform a CBE, conduct a breast cancer risk assessment, provide risk reduction recommendations, and counsel on healthy lifestyles.

Those with Average Risk ≥40 Years of Age

The NCCN Panel recommends annual clinical encounter, which includes ongoing breast cancer risk assessment, risk reduction counseling, as well as a CBE, encourages individuals to be aware of their breasts and promptly report any changes, and recommends annual screening mammography (category 1 recommendation) with tomosynthesis. Those electing to undergo screening mammography with tomosynthesis should be counseled regarding its potential benefits, risks, and limitations. The NCCN Panel is in agreement with ACS and other organizations that annual screening mammograms in individuals ≥40 years of age at average risk for breast cancer should be covered by health care payers without additional cost-sharing or copayments.

The mammography screening guidelines put forth by various organizations vary with respect to age to initiate screening, the frequency of screening, and when to stop screening.[83-85] The assessment of the benefits of mammography versus the risks based on age are weighed on different scales by different organizations.

The NCCN Panel continues to support its long-standing recommendation of *annual* screening mammography beginning at age 40 years (category 1 recommendation), as it results in the greatest mortality reduction, most lives saved, and most life years gained. Mammography with tomosynthesis is now recommended as previously discussed, as multiple studies show that tomosynthesis can decrease call back rates and improve cancer detected compared with 2D mammography alone, though long-term data on incremental mortality reduction have not yet been demonstrated.[22-36] Radiation exposure may be increased, but remains within FDA guidelines and can be reduced with FDA-approved synthesized 2D reconstruction.[23,37,38]

The NCCN Panel has not established an upper age limit for screening. According to the Panel, if a patient has severe comorbid conditions limiting life expectancy and no further therapeutic interventions based on the screening findings would be appropriate and acceptable to the patient, then the patient should not undergo screening, regardless of age. The Panel notes that periodic reassessment of risk is recommended, particularly when risk factors change. Similarly, ACS guidelines have not established an upper age limit for screening, and recommend that individuals in overall good health should continue screening if their life expectancy is ≥10 years.[83] Current U.S. Preventive Services Task Force (USPSTF) and draft recommendations are for screening for individuals 50 to 74 years of age and state that there is insufficient evidence to weigh the benefits and harms of screening in individuals ≥75 years of age.[84,85]

Rationale for Mammographic Screening Starting at 40 Years of Age

Mammographic screening and subsequent treatment have been shown to decrease breast cancer mortality beginning at age 40 years.[83,84] Meta-analysis of invitational RCTs, observational studies, and computer modeling of mammographic screening consistently show benefit, although the magnitude of benefit has varied in part due to the diversity of study designs and screening frequency. However, the RCTs are now old and may not reflect current mammography technology, interpretation, and oncologic care. Therefore, effectiveness may be better estimated in more modern observational studies.

Breast cancer screening guidelines put forth by all the organizations acknowledge mortality reduction benefit from current studies of mammography screening in females 40 to 49 years of age. The American

Version 1.2026 © 2026 National Comprehensive Cancer Network© (NCCN©), All rights reserved. NCCN Guidelines® and this illustration may not be reproduced in any form without the express written permission of NCCN.

PLEASE NOTE that use of this NCCN Content is governed by the End-User License Agreement, and you MAY NOT distribute this Content or use it with any artificial intelligence model or tool.
Printed by Ambrish Chauhan on 5/1/2026 7:03:18 AM. Copyright © 2026 National Comprehensive Cancer Network, Inc. All Rights Reserved.

Cancer Society recommended screening commencement at age 45 as a "strong" recommendation, as data has shown the absolute benefit of ages 45 to 49 to be very similar to ages 50 to 54.[83] While showing there is benefit of screening for ages 40 to 44, a "qualified" rather than a "strong" recommendation is given for the younger age group due to the lower absolute benefit. The "qualified" recommendation means "most" females would want the earlier screening and only a "small proportion" would not.[83] While the USPSTF has recently updated its recommendation for screening to begin at age 40 rather than age 50, the recommendation is for biennial rather than annual mammography.[86]

Benefits of Mammographic Screening

Systematic reviews of RCTs have generally shown a reduction in breast cancer mortality with mammography screening.[87]

The UK Age trial specifically studied the effect of film-screen mammographic screening starting at age 40 years.[88] A mean of 10.7 years of follow-up showed a non-statistically significant breast cancer mortality reduction in females invited to screening (RR, 0.83; 95% CI, 0.66–1.04).[88] A follow-up of the UK AGE trial was carried out to study breast cancer mortality and incidence at a median of 17.7 years of follow-up, an increase of 7 years from the previous analysis.[89] There continued to be a non-significant overall reduction in risk of breast cancer mortality (RR, 0.88; 95% CI, 0.74–1.04) during a median of 17 years of follow-up. However, the reduction in breast cancer mortality noted in the first 10 years after diagnosis was now significant in the group that underwent screening compared with the control group (RR, 0.75; 95% CI, 0.58–0.97).[89] Other trials included females who were ≤49 years at the time of entry into the trial, who were therefore in their 50s during the screening intervention. The results of the UK Age trial support the importance of annual mammography screening in females 40 to 49 years of age to reduce breast cancer-related mortality.[89]

A Swedish study compared breast cancer mortality rates in females 40 to 49 years of age living in different counties. Counties included those that invited females for screening starting at age 40 and others that did not invite females to be screened at age 40 and started screening at age 50.[90] After an average 16 years of follow-up, the investigators observed an overall 29% mortality reduction (RR, 0.71; 95% CI, 0.62–0.80). For age groups 40 to 44 and 45 to 59 years, the RR estimates were 0.82 (95% CI, 0.67–1.00) and 0.63 (95% CI, 0.54–0.75).[90] Although the estimated reduction in breast cancer mortality was smaller for ages 40 to 44 compared with ages 45 to 49, the reduction in mortality seen for ages 40 to 44 was still substantial.[90]

It is important to note that the RCTs studying the benefits of screening mammography used screen film mammography, sometimes using only a single view. Therefore, they may not reflect results obtained with modern advances in imaging. Digital mammography has been shown to detect more breast cancers in females with dense breasts, which is common in younger females. The more recent observational studies better quantify the effectiveness of screening in the context of improved imaging techniques.

Case-control observational studies have shown benefits of reduction in breast cancer mortality ranging from 40% to 45%.[91,92] A meta-analysis of observational case-control studies found a significant reduction in breast cancer mortality with mammographic screening for females aged 40 to >79 years with a 48% mortality reduction (odds ratio [OR], 0.52; 95% CI, 0.42–0.65) after adjustment for self-selection.[93] Relevant to the North American population, data from a Canadian study showed a mortality reduction of 44% (95% CI, 33%–55%) among females screened between 40 and 49 years of age, which was similar to the overall reduction in mortality of 40% (95% CI, 33%–48%) found among females ages 40 to 79 years.[92]

Version 1.2026 © 2026 National Comprehensive Cancer Network© (NCCN©), All rights reserved. NCCN Guidelines® and this illustration may not be reproduced in any form without the express written permission of NCCN.

PLEASE NOTE that use of this NCCN Content is governed by the End-User License Agreement, and you MAY NOT distribute this Content or use it with any artificial intelligence model or tool.
Printed by Ambrish Chauhan on 5/1/2026 7:03:18 AM. Copyright © 2026 National Comprehensive Cancer Network, Inc. All Rights Reserved.

A retrospective analysis evaluating the benefits of mammographic screening of females aged 40 to 49 years found that mammography-detected breast cancer coincides with lower-stage disease at detection, resulting in reduced treatment morbidity and lower rates of recurrence.[94] A population-based study of data from the Netherlands Cancer Registry estimated the impact of tumor size in females with breast cancer in two time intervals: 1999 to 2005 and 2006 to 2012. The year 2005 was used to divide the data into two time intervals studies, because trastuzumab and other effective adjuvant therapy were introduced after this year in the Netherlands. The analysis found that tumor size remained a critical component of survival even with the availability of new and effective systemic therapy options.[95] These findings reiterate the fact that diagnosing breast cancer at an early stage is important.

The Cancer Intervention and Surveillance Modeling Network (CISNET) models from 2009 demonstrate a 29% to 54% (mean 39%) mortality reduction for annual screening for females ages 40 to 84 years.[96] The CISNET models from 2015, based on digital screening mammography, show greater mortality reduction benefit.[97] Benefits of screening females in their 40s are more favorable when considered from the perspective of life years saved compared exclusively to mortality reduction.[98] Females in their 40s have the highest number of life years at risk to be lost due to longevity even though their breast cancer risk is smaller. Breast cancer is the second leading cause of death for females in their 40s, trailing only poisonings.

Individuals should be informed of the evidence demonstrating the value of detecting breast cancer early, before symptoms develop. The benefits of early detection include mortality reduction, less aggressive treatment, and a wide range of treatment options. Screening also identifies those with atypical hyperplasia or LCIS who may be candidates for risk reduction therapy to reduce their chance of developing breast cancer.

Harms of Mammographic Screening

The risk profile for harms of breast cancer screening, such as false-positive results and overdiagnosis, are weighted differently by different organizations.[83,84] This is a very subjective rating as there are limited data regarding a female's perspective of the harms of screening. The clinical practice guidelines that recommend delaying screening to age ≥50 years[83] place a greater emphasis on the risks of screening mammography, specifically false-positive results and overdiagnosis. Most females highly value the reduction in breast cancer mortality, whereas many females do not consider false positives and potential overdiagnosis to be a "harm."[99] In this study, 63% of females thought ≥500 false positives per life saved was acceptable.[99]

The NCCN Panel believes that the harms analysis of mammographic screening is most informative if it includes the net harms of mammographic screening in individuals who underwent screening versus those who did not. According to the NCCN Panel, the major harm related to *not performing* any screening for breast cancer is diagnosis of later-stage breast cancer, which may prove to be lethal or require therapy that is more extensive. There is evidence showing that females diagnosed with breast cancer who did not undergo screening had substantially more need for chemotherapy and more extensive surgery than females who underwent routine screening.[100]

Furthermore, absence of mammographic screening for breast cancer does not mean absence of breast-related problems. Females who are not screened develop signs and symptoms leading to diagnostic investigation, false-positive biopsies, or potential diagnosis of non-lethal conditions.

A mammogram result is often considered a false positive when it prompts additional imaging tests and/or biopsy in an abnormality that is not cancerous. False-positive results can occur at any age. It is important to distinguish between recalls from screening and biopsies that result in a

Version 1.2026 © 2026 National Comprehensive Cancer Network© (NCCN©), All rights reserved. NCCN Guidelines® and this illustration may not be reproduced in any form without the express written permission of NCCN.

PLEASE NOTE that use of this NCCN Content is governed by the End-User License Agreement, and you MAY NOT distribute this Content or use it with any artificial intelligence model or tool.
Printed by Ambrish Chauhan on 5/1/2026 7:03:18 AM. Copyright © 2026 National Comprehensive Cancer Network, Inc. All Rights Reserved.

false-positive outcome. Recalls are defined by the FDA as "incomplete" and not a false positive. Recalls are resolved by obtaining incremental diagnostic mammographic imaging and/or ultrasound with the vast majority of recalls proving negative and not requiring biopsy. The frequency of recalls from screening are the same per decade whether screening begins at age 40 or 50 years.[84] While recalls are commonly thought to be higher in younger females, this primarily reflects higher recall rates at the prevalent or initial screen when prior mammograms are not available for comparison and not the age at which screening commences. Initiating screening mammography at age 50 years would shift this "prevalent" false positive to that decade. Furthermore, the decade-long false-positive biopsy recommendation rate is somewhat lower when screening begins at age 40 compared to age 50 years. Less than 1% of females screened per year will be recommended for a biopsy that proves benign, whether annual screening commences at age 40 or 50 years. The vast majority of false-positive biopsies are now performed as outpatient image-guided needle biopsies using local anesthesia and are generally well-tolerated and acceptable to females.

Those considering false positives as one of the harms of screening note psychological consequence as one of the negative consequences of false positives.[101] However, a cross-sectional survey of female's attitudes toward false positives found that females consider false positives as an acceptable consequence.[99]

Overdiagnosis is the detection of a condition by screening that would not have become apparent by usual care absent screening. Overdiagnosis may lead to overtreatment, which is the more significant problem. It is important to understand that overdiagnosis would not be influenced by the age to initiate screening or the screening interval. The mammographic abnormality that leads to a potential overdiagnosis does not go away without treatment. If the age to initiate screening is raised from 40 to 45 years, or the screening interval is lengthened to biennial, the potential overdiagnosis would occur at the next mammogram that showed the imaging abnormality.

Overdiagnosis is difficult to measure, because neither the clinician, pathologist, nor the patient can be sure whether the abnormality detected by screening would be harmless or life threatening to the patient. Furthermore, overdiagnosis assumes that the level or amount of diagnosis by symptomatic usual care is optimal. The estimates of overdiagnosis vary widely between various studies (from almost none to up to 54%[83,87,102-104]) due to methods and parameters used for estimation and whether ductal carcinoma in situ (DCIS) is included or excluded. Furthermore, overdiagnosis estimates vary by age and duration of follow-up.

The most reliable estimates of overdiagnosis would be from RCTs in which there was no formal screening offered to the control group for a long period at the end of the screening period. The Malmo randomized trial, in which the invited cohort group aged 55 to 69 years was not routinely screened at the end of the trial,[105] showed an overdiagnosis rate of 10% after an average 15 years of follow-up, which included invasive cancer and DCIS. The rate was 7% for invasive cancer.[105] The National Breast Screening Studies in Canada conducted two randomized trials that included a control group that did not receive routine screening at the end of the trial. The follow-up period was 13 years. In the first trial, in which females were aged 40 to 49 years at recruitment, the estimated overdiagnosis was 14%. In the second trial, in which females were aged 50 to 59 years at recruitment, the estimated overdiagnosis rate was 11%.[106,107] Using these three studies, the UK review estimated overdiagnosis (including DCIS) to be 10.7%.[108] Yet, these studies are limited by their age and differing use of diagnostic mammography among females who were not screened. However, analysis of the UK AGE trial, which included females aged 40 to 49 years, showed a very low rate of

Version 1.2026 © 2026 National Comprehensive Cancer Network© (NCCN©), All rights reserved. NCCN Guidelines® and this illustration may not be reproduced in any form without the express written permission of NCCN.

PLEASE NOTE that use of this NCCN Content is governed by the End-User License Agreement, and you MAY NOT distribute this Content or use it with any artificial intelligence model or tool.
Printed by Ambrish Chauhan on 5/1/2026 7:03:18 AM. Copyright © 2026 National Comprehensive Cancer Network, Inc. All Rights Reserved.

overdiagnosis of 1%,[109] a value similar to estimates from Sweden for females in their 40s.[90] A reported population-based screening study showed a rate of only 0.3% overdiagnosis after 12 years of follow-up in females either invited or uninvited (n = 988,090) and a 46% reduction in breast cancer mortality among attenders.[110] Direct estimates of type 1 overdiagnosis for females screened in the United States show marked differences depending on age of diagnosis, with <1% among females who are premenopausal and 22% among females aged 80 years.[111]

Prevention of cancer death is highly valued compared with false-positive results/overdiagnosis by most females.[99] Current science cannot predict which breast cancer may be overdiagnosed or be potentially lethal in any one individual. Personalized treatment programs are recommended and advances in personalized treatment will diminish the risk of overtreatment and significance of overdiagnosis. The treatment of cancer may cause suffering and anxiety, but that suffering is likely worth the gain from the potential reduction in breast cancer mortality. According to the NCCN Panel, the risk of overdiagnosis and false positives are outweighed by the benefit of mortality reduction in determining the age to recommend starting screening.

The NCCN Panel emphasizes adopting strategies and research to reduce the harms of screening (false positives and overdiagnosis) rather than raising the age to initiate screening to potentially delay these issues. This includes newer imaging modalities that improve the detection of breast cancer with fewer recalls (eg, tomosynthesis). Research to better define the biology of breast cancer is needed so that lesions that are not destined to progress are either not treated or are treated less aggressively.

Screening Interval and Rationale for Annual Mammogram Screening

Another consideration is the time interval between screening exams. Performing screening mammography annually versus biennially remains controversial. Most studies and models suggest incremental benefit with annual screening, especially among younger females and females who are premenopausal.[83,84,96,112] The evaluation of benefits versus risk strongly supports the value of screening and the importance of adhering to a schedule of regular mammograms.

The NCCN Panel believes that the benefits of annual mammography outweigh the risks. Breast cancer mortality is estimated to be lower with annual compared to biennial screening mammograms.[96] Additionally, mammograms can often detect a lesion 2 years before the lesion is discovered by CBE. Interval cancer rates are lower among females screened annually. To reduce mortality from breast cancer, yearly screening is thought to be more beneficial. The Panel also acknowledges that incomplete adherence will alter the outcome of any recommendation.

An evaluation of the CISNET modeling of benefits of screening females between 40 to 49 years found that using *annual* digital mammography saves 30% more lives and 34% more life years than *biennial* digital mammography.[113] Also, with annual digital screening mammography, the deaths averted (0.6/1000) are similar for ages 40 to 44 *and* 45 to 49 years (0.7/1000).[112,114]

A decline in breast cancer specific-mortality was observed in a cohort of females for every additional annual mammogram performed 5 years prior to breast cancer diagnosis; this further emphasizes the importance of annual mammography.[115] The results of a primary analysis to estimate the association between incidence of DCIS detected by screening and subsequent invasive interval cancer incidence showed a DCIS detection rate of 1.5 per 1000 screened and a reduction of one invasive interval cancer per 1.5 to 3 DCIS cases detected.[116]

Version 1.2026 © 2026 National Comprehensive Cancer Network© (NCCN©), All rights reserved. NCCN Guidelines® and this illustration may not be reproduced in any form without the express written permission of NCCN.

PLEASE NOTE that use of this NCCN Content is governed by the End-User License Agreement, and you MAY NOT distribute this Content or use it with any artificial intelligence model or tool.
Printed by Ambrish Chauhan on 5/1/2026 7:03:18 AM. Copyright © 2026 National Comprehensive Cancer Network, Inc. All Rights Reserved.

While the risk of false positives is greater with annual compared to biennial mammograms,[84] the Panel believes that the lower mortality and morbidity of annual screening outweighs this harm.

Age to Stop Mammographic Screening

Most trials for breast screening have used a cutoff age of 65 or 70 years.[117-119] However, observational studies and computer models show mortality benefit to age 80 to 84.[83,96] Considering the high incidence of breast cancer in individuals who are older, the screening guidelines used for those ≥40 years of age are recommended for all individuals aged ≥40 years with no age cutoff to stop screening. Clinicians should always use judgment when applying screening guidelines. The mortality benefit of screening mammography is often delayed for 5 to 7 years in RCTs, thus emphasizing the importance of life expectancy and overall health when considering age to stop screening. Mammography screening should be individualized, weighing its potential benefits/risks in the context of the patient's overall health and estimated longevity.[120] If a patient has severe comorbid conditions limiting life expectancy and no further therapeutic intervention based on the screening findings would be appropriate and acceptable to the patient, then the patient should not undergo screening, regardless of age.[120,121]

Screening Recommendations for Individuals at Increased Risk of Breast Cancer

It is important to note that, for individuals who meet criteria for multiple increased risk categories, the most comprehensive set of screening recommendations should be followed.

Those with a Known Genetic Predisposition or Pedigree Suggestive of a Genetic Predisposition

Accurate family history information is needed to adequately assess breast cancer risk. Familial cancers share some but not all features of hereditary cancers. For example, although familial breast cancers occur in a given family more frequently than expected based on statistics, they generally do not exhibit inheritance patterns or onset age consistent with hereditary cancers. Familial breast cancers may be associated with chance clustering, genetic variations in lower-penetrance genes, a shared environment, small family size, and/or other factors.

The NCCN Guidelines for Genetic/Familial High-Risk Assessment: Breast, Ovarian, Pancreatic, and Prostate (available at www.NCCN.org) include recommendations for referral to a cancer genetics professional for further evaluation for individuals who have either a personal history or a close family history meeting certain criteria and also list screening recommendations for common hereditary syndromes that confer increased risk for breast and ovarian cancer.

Those with a Lifetime Risk of Breast Cancer ≥20% Based on Models That Include a Comprehensive Family History

A lifetime risk of breast cancer of ≥20% as assessed by models that include a comprehensive family history (including first, second, and, when included in the model, third degree relatives) is a risk threshold used in the guidelines to identify an individual as a potential candidate for risk reduction strategies, as well as to direct screening recommendations. According to the ACS guidelines for breast screening, MRI may be performed as an adjunct to mammography[60] in a female at high risk if the lifetime risk of breast cancer is approximately ≥20% based on models that rely mainly on family history. A cancer genetic professional may be helpful in determining the lifetime risk of the individual based on models that include a comprehensive family history. These include Tyrer-Cuzick,[13] BRCAPRO,[12] BOADICEA/CanRisk,[14] BCSC Invasive Breast Cancer Risk Calculator,[15] and other models.[60,122,123] BRCAPRO[12] and BOADICEA[14] are also commonly used to estimate the risk of *BRCA* mutations. Strong genetic association between breast and ovarian cancer has been demonstrated in some

Version 1.2026 © 2026 National Comprehensive Cancer Network© (NCCN©), All rights reserved. NCCN Guidelines® and this illustration may not be reproduced in any form without the express written permission of NCCN.

PLEASE NOTE that use of this NCCN Content is governed by the End-User License Agreement, and you MAY NOT distribute this Content or use it with any artificial intelligence model or tool.
Printed by Ambrish Chauhan on 5/1/2026 7:03:18 AM. Copyright © 2026 National Comprehensive Cancer Network, Inc. All Rights Reserved.

families by linkage analyses (see NCCN Guidelines for Genetic/Familial High-Risk Assessment: Breast, Ovarian, Pancreatic, and Prostate, available at www.NCCN.org).

For those with a ≥20% lifetime risk of breast cancer based on models that include a comprehensive family history, the NCCN Panel encourages breast awareness and clinical encounter every 6 to 12 months to begin at the age identified as being at increased risk. The NCCN Panel recommends annual screening mammography with tomosynthesis to begin no later than age 40 years, or 10 years prior to when the youngest family member was diagnosed with breast cancer but not prior to age 30 (whichever comes first). Beginning annual screening mammography with tomosynthesis at age 25 years can be considered on a case-by-case basis depending on the extent of family history and age(s) of diagnosis or for patients who cannot undergo breast MRI. In addition, in accordance with the ACS guidelines,[60] the NCCN Panel recommends annual breast MRI with and without contrast to begin no later than age 40 years, or 10 years prior to when the youngest family member was diagnosed, but not prior to age 25 years (whichever comes first). Of note, some individuals at increased risk of breast cancer may undergo breast MRI prior to qualifying for screening mammogram. Many experts recommend alternating the mammogram and MRI every 6 months. While there are limited data to support this approach, the presumption is that this may lead to earlier identification of interval cancers.[124] For those who qualify for but cannot undergo MRI, CEM or MBI can be considered. Whole breast ultrasound may be done if CEM or MBI are not available or accessible; however, in a recent direct comparison trial, MRI had a cancer detection rate approximately 4 times higher than ultrasound in patients with dense breasts.[47] According to the NCCN Panel, individuals in this group should be asked to consider risk reduction strategies in accordance with the NCCN Guidelines for Breast Cancer Risk Reduction (available at www.NCCN.org). As noted previously, periodic reassessment of risk is recommended, particularly when risk factors change, to ensure residual lifetime risk remains ≥20%.

Individuals with a residual lifetime risk of 15% to 20% may be considered for supplemental screening on an individual basis, depending on risk factors.

Those Who Have Received Prior Irradiation with Exposure to Breast Tissue Between 10 and 30 Years of Age

Results from several studies have demonstrated that females who received thoracic irradiation in their second or third decade of life have a substantially increased risk of developing breast cancer by age 40 years.[125-130] For example, in the Late Effects Study Group trial, the overall risk of breast cancer associated with prior thoracic irradiation at a young age was found to be 56.7-fold (55.5-fold for female patients) greater than the risk of breast cancer in the general population.[126,129] The RR of breast cancer in females according to follow-up interval was 0 at 5 to 9 years; 71.3 at 10 to 14 years; 90.8 at 15 to 19 years; 50.9 at 20 to 24 years; 41.2 at 25 to 29 years; and 24.5 at >29 years.[129] Results from a case-control study of females treated with thoracic radiation at a young age for Hodgkin lymphoma indicated that the estimated cumulative absolute risk of breast cancer at 55 years of age was 29.0% (95% CI, 20.2%–40.1%) for a female treated at 25 years of age with at least 40 Gy of radiation and no alkylating agents.[131] Although there is a concern that the cumulative radiation exposure from mammography in a young female may itself pose a risk for cancer, it is felt that the additional radiation in this population is negligible compared to the overall radiation exposure. Unfortunately, findings from a survey of breast screening practices in this population of patients suggest that a sizable segment of this group is not undergoing regular mammographic screening.[132]

For those ≥25 years of age who have received prior irradiation with exposure to breast tissue, the NCCN Panel recommends encouraging

Version 1.2026 © 2026 National Comprehensive Cancer Network© (NCCN©), All rights reserved. NCCN Guidelines® and this illustration may not be reproduced in any form without the express written permission of NCCN.

PLEASE NOTE that use of this NCCN Content is governed by the End-User License Agreement, and you MAY NOT distribute this Content or use it with any artificial intelligence model or tool.
Printed by Ambrish Chauhan on 5/1/2026 7:03:18 AM. Copyright © 2026 National Comprehensive Cancer Network, Inc. All Rights Reserved.

breast awareness, and recommends a clinical encounter be initiated every 6 to 12 months beginning 8 years after radiation exposure.[133] Breast imaging assessments with annual mammograms with tomosynthesis and annual MRI with and without contrast are recommended 8 years after RT but not prior to age 25 years.[134,135] As noted previously, the NCCN Panel recommends alternating the mammogram and breast MRI every 6 months, as this may lead to earlier identification of interval cancers.[124]

For those <25 years of age who have received prior irradiation with exposure to breast tissue, the NCCN Panel recommends encouraging breast awareness, counseling on risk, and an annual clinical encounter starting 8 years after RT.

Consideration should be made for screening on a case-by-case basis for individuals outside the age range of 10 to 30 years as well. While screening mammogram would not be done prior to age 25 years, breast MRI may be considered.

Individuals ≥35 Years of Age with a 5-Year Risk of Invasive Breast Carcinoma ≥1.7% by the Modified Gail Model or as Calculated by an Imaging-Based Risk Assessment Model

For individuals aged ≥35 years, a risk assessment tool is available to identify those who are at increased risk. The National Cancer Institute (NCI) and the National Surgical Adjuvant Breast and Bowel Project (NSABP) Biostatistics Center have developed a computerized, interactive risk assessment tool based on the modified Gail model[136-140] that can be accessed at https://bcrisktool.cancer.gov, which provides risk projections based on several risk factors for breast cancer. The modified Gail model assesses the risk of invasive breast cancer as a function of age, menarche, age at first live birth or nulliparity, number of first-degree relatives with breast cancer, number of previous benign breast biopsies, atypical hyperplasia in a previous breast biopsy, and race. The model calculates 5-year and lifetime projected probabilities of developing invasive breast cancer and can be used to identify those who are at increased risk. The Gail model should not be used for those with a predisposing gene mutation, a strong family history of breast or ovarian cancer suggestive of a genetic predisposition, a prior history of thoracic radiation, or LCIS.

The Gail model was updated using combined data from the Women's Contraceptive and Reproductive Experiences (CARE) study and the SEER database, as well as causes of death from the National Center for Health Statistics, to provide a more accurate determination of risk for African-American females.[141] It has also been updated using data from the Asian American Breast Cancer Study (AABCS) and the SEER database to provide a more accurate risk assessment for Asian and Pacific Islander females in the United States.[142]

Increased risk of developing breast cancer is defined by the modified Gail model for females ≥35 years of age as a 5-year risk of ≥1.7%. This is the average risk for a 60-year-old female, which is the median age of diagnosis of breast cancer in the United States. The 5-year predicted risk of breast cancer required to enter the NSABP Breast Cancer Prevention Trial of tamoxifen versus placebo, as well as the Study of Tamoxifen and Raloxifene (STAR) trial, was ≥1.7%. As previously mentioned, the modified Gail model risk assessment tool also provides an estimate of a female's lifetime risk of breast cancer. However, this estimate is based on the Gail model risk criteria, which differ from criteria used in risk assessment models predominantly based on family history (see below). Lifetime breast cancer risk as determined by the Gail model is not used in these guidelines to determine whether an individual is eligible for screening breast MRI.

Artificial intelligence (AI)-based risk assessment models are emerging as another effective tool in assessing risk of invasive breast cancer. These

Version 1.2026 © 2026 National Comprehensive Cancer Network© (NCCN©), All rights reserved. NCCN Guidelines® and this illustration may not be reproduced in any form without the express written permission of NCCN.

PLEASE NOTE that use of this NCCN Content is governed by the End-User License Agreement, and you MAY NOT distribute this Content or use it with any artificial intelligence model or tool.
Printed by Ambrish Chauhan on 5/1/2026 7:03:18 AM. Copyright © 2026 National Comprehensive Cancer Network, Inc. All Rights Reserved.

deep-learning algorithms utilize features of negative screening mammograms to generate risk assessment scores.

A systemic review assessed the efficacy of mammography-based AI algorithms, with or without the use of additional clinical risk information such as family history or breast density.[143] Studies with AI image-only based models were found to have a higher median AUC performance (0.72; range, 0.62–0.90) compared to breast density models or clinical risk prediction tools such as Gail or Tyrer-Cuzick (0.61; range, 0.54–0.69). Studies that combined image and clinical risk factor AI algorithms performed slightly better than AI image-only based models, with a median AUC of 0.73 (range, 0.66–0.84).

For an individual ≥35 years of age with a 5-year risk ≥1.7% per the Gail Model or as calculated by an imaging-based risk assessment model, the NCCN Panel encourages breast awareness and recommends a clinical encounter every 6 to 12 months and annual digital mammography with tomosynthesis, to begin at the age identified as being at increased risk by either model. Annual breast MRI with and without contrast may be considered, with CEM or MBI as additional alternatives for those who qualify for but cannot undergo MRI. As noted previously, many experts recommend alternating the mammogram and MRI every 6 months, as this may lead to earlier identification of interval cancers.[124] Whole breast ultrasound may be done if CEM or MBI are not available or accessible; however, as noted previously, has a cancer detection rate approximately 4 times lower than MRI in patients with dense breasts.[47] Periodic reassessment of risk is recommended, particularly when risk factors change, to ensure risk remains ≥1.7%. In addition, according to the NCCN Panel, those in these groups should be counseled for consideration of risk reduction strategies in accordance with the NCCN Guidelines for Breast Cancer Risk Reduction (available at www.NCCN.org).

Those with a History of ADH or Lobular Neoplasia (LCIS/ALH)

A diagnosis of ADH or LCIS/ALH is associated with high risk of development of cancer in either breast and not just at the site of diagnosis of high risk breast lesion.[144-149]

For those with a history of ADH or LCIS/ALH, the NCCN Panel encourages breast awareness and recommends a clinical encounter every 6 to 12 months beginning at the age of diagnosis and annual mammography with tomosynthesis, beginning at the age of diagnosis of ADH or LCIS/ALH but not prior to age 30. In addition, according to the NCCN Panel, annual MRI with and without contrast should be considered beginning at the age of diagnosis of ADH or LCIS/ALH but not prior to age 25.[62] Many experts recommend alternating the mammogram and MRI every 6 months, as this may lead to earlier identification of interval cancers.[124] For those who qualify for but cannot undergo MRI, CEM or MBI can be considered. Whole breast ultrasound may be done if contrasted imaging or functional imaging is not available or accessible; however, as previously noted has shown an approximately 4 times lower cancer detection rate compared to MRI in patients with dense breasts in a recent direct comparison trial,.[47] Individuals in these groups should also be strongly considered for risk reduction strategies in accordance with the NCCN Guidelines for Breast Cancer Risk Reduction (available at www.NCCN.org).

Mammographic Breast Density (Heterogeneously or Extremely Dense Breasts) in Patients Who Do Not Meet any Other Increased Risk Category

Dense breast tissue as measured by mammography is increasingly recognized as an important risk factor for breast cancer.[150-153] Compared to patients with scattered areas of fibroglandular density, the OR for developing breast cancer is 1.28 for heterogeneously dense breasts and 1.83 for extremely dense breasts.[154] Additionally, the presence of

Version 1.2026 © 2026 National Comprehensive Cancer Network© (NCCN©), All rights reserved. NCCN Guidelines® and this illustration may not be reproduced in any form without the express written permission of NCCN.

PLEASE NOTE that use of this NCCN Content is governed by the End-User License Agreement, and you MAY NOT distribute this Content or use it with any artificial intelligence model or tool.
Printed by Ambrish Chauhan on 5/1/2026 7:03:18 AM. Copyright © 2026 National Comprehensive Cancer Network, Inc. All Rights Reserved.

increased dense breast tissue limits the sensitivity of mammography due to the obscuration or "masking" of cancers by overlying dense breast tissue. Mammographic textural patterns also impact the sensitivity of mammography and are associated with breast cancer risk.[155]

About half of all females of screening age have "dense" breast tissue referred to as "heterogeneously dense" or "extremely dense" by ACR Breast Imaging Reporting and Data System (BI-RADS) nomenclature. Of note, the presence of dense tissue is not abnormal and can change over time. While many individual states have passed legislation mandating patient notification of breast density,[156] not all states require insurance coverage for supplemental screening. The FDA issued a final rule, effective nationally September 10, 2024, to update the Mammography Quality Standards Act by requiring a breast density assessment be reported to patients and HCPs, with additional language notifying patients that in the setting of dense breast tissue, supplemental imaging studies beyond mammography may help detect cancer and that individuals should discuss their risk of breast cancer and review their personal preferences with their HCPs.[157]

In a prospective study, females (n = 40,373; age range, 50–75 years) with extremely dense breast tissue and normal screening mammogram results were given the option to undergo supplemental breast MRI or mammography only.[158] Among females who opted to undergo supplemental breast MRI, the interval-cancer rate was significantly lower compared to the mammography only arm (2.5 per 1000 screenings vs. 5.0 per 1000 screenings, respectively; $P < .001$). In those that underwent MRI, the cancer-detection rate was 16.5 per 1000 screenings, with positive predictive values of 17.4% for recall for additional imaging and 26.3% for biopsy. The rate of false positive MRIs was 79.8 per 1000 screenings.

For those with mammographic breast density (heterogenously and/or extremely dense breasts) who do not meet any other increased risk category, the NCCN Panel encourages breast awareness and recommends a clinical encounter every 6 to 12 months starting when breast density is identified on mammography. Annual screening mammogram with tomosynthesis is recommended to begin no later than age 40 years, but not prior to age 30 years. For patients with extremely dense breasts, breast MRI with and without contrast is recommended (category 1 for those aged 50–75 years with normal mammograms[158]). The NCCN Panel recommends beginning breast MRI at age 50 years, though consideration can be given to start at age 40 years based on individual risk factors. The ideal frequency of supplemental screening MRI in this patient population is not yet known.

The risks and benefits of such screening should be discussed with individual patients.[159] Different supplemental imaging modalities may be considered based on risk and patient values/preference.[40] The ACR has published guidelines for supplemental screening based on breast density.[160] For individuals in all breast density and risk categories, the NCCN Panel recommends shared decision-making with counseling on the risks and benefits of supplemental screening following evaluation of the individual's breast density and other risk factors.

Individuals in these groups should also be considered for risk reduction strategies in accordance with the NCCN Guidelines for Breast Cancer Risk Reduction (available at www.NCCN.org).

Diagnostic Evaluation

Breast signs and symptoms are common. A retrospective study of females aged 40 to 70 years showed that 16% (total visits of 23 per 100 females) of females will present to their provider with symptoms during a decade with higher frequency among those aged 40 to 59 years compared to those aged 60 to 79 years.[161] Pain is found to be the most common symptom followed by palpable mass. In addition, palpable areas of

Version 1.2026 © 2026 National Comprehensive Cancer Network© (NCCN©), All rights reserved. NCCN Guidelines® and this illustration may not be reproduced in any form without the express written permission of NCCN.

PLEASE NOTE that use of this NCCN Content is governed by the End-User License Agreement, and you MAY NOT distribute this Content or use it with any artificial intelligence model or tool.
Printed by Ambrish Chauhan on 5/1/2026 7:03:18 AM. Copyright © 2026 National Comprehensive Cancer Network, Inc. All Rights Reserved.

concern are identified during a breast physical exam. Breast clinical findings are not specific and there is variability in interpretation. Each sign and symptom is associated with a risk of malignancy and warrants diagnostic evaluation; however, most symptoms will be determined to be benign in etiology. Those <40 years of age, who are not usually recommended for routine breast screening, also frequently present with breast signs or symptoms.

Diagnostic evaluation includes physical examination and diagnostic imaging for symptomatic individuals and diagnostic imaging for those recalled from screening. Attention to timely diagnostic follow-up after abnormal breast screening is recommended, as racial disparities have been observed in time to diagnostic imaging and/or biopsy following abnormal breast screening. In a study that assessed time to assessment following abnormal breast screening, time to tissue diagnosis was 1.75 times longer for Black individuals compared to white individuals.[162] Patient navigation may be beneficial for populations at risk for delays in care.[163,164]

A clinical encounter for an individual with breast signs or symptoms should include, at a minimum, a review of medical and family history and a CBE. Subsequent visits should include risk assessment (by age 25) and risk reductional counseling. Known breast density should be factored into risk assessment if available from a prior mammogram.

Unlike imaging for screening, which is used to detect cancer in asymptomatic individuals, diagnostic evaluation is used to characterize a clinical finding or possible abnormality found during screening. There is confusion regarding the term “diagnostic” imaging, as it is applied to two very different situations: 1) imaging for a clinical finding such as a palpable mass; and 2) incremental imaging after a possible abnormal screening mammogram in an asymptomatic individual (also referred to as recall or callback). To add further confusion, insurance carriers may consider a routine mammogram to be “diagnostic” in certain asymptomatic individuals (eg, in those with prior cancer). Diagnostic evaluation in this review will be restricted to the former two situations.

Diagnostic imaging may include diagnostic mammography with tomosynthesis, ultrasound, and at times diagnostic breast MRI with and without contrast. The eventual decision regarding need for tissue sampling is based on level of suspicion on imaging and/or clinical examination. Biopsy is needed in situations where imaging is negative but clinical findings are suspicious since imaging is not completely sensitive for cancer detection.

While the term “diagnostic” implies diagnosis, imaging results are often not specific enough to be truly “diagnostic.”

Diagnostic Imaging After Screening Mammography Recall

Diagnostic Mammography

Screening mammography consists of two standard x-ray images of each breast, whereas a diagnostic mammogram includes additional views, such as spot compression views or magnifications views, to investigate the finding in question. Diagnostic mammography is associated with higher sensitivity but lower specificity as compared to screening mammography. The NCCN Panel recommends that tomosynthesis replace traditional diagnostic mammographic imaging.[165-169]

Frequently, especially for masses or asymmetries, diagnostic ultrasound is also performed. Each imaging modality may be positive or negative, which allows for four outcomes: both imaging modality results are negative; both are positive; mammogram is positive and ultrasound is negative; and mammogram is negative and ultrasound is positive. In general, a “final” combined imaging assessment category is rendered after a “recall’ from screening, which is the most suspicious imaging outcome assessment.

Version 1.2026 © 2026 National Comprehensive Cancer Network© (NCCN©), All rights reserved. NCCN Guidelines® and this illustration may not be reproduced in any form without the express written permission of NCCN.

PLEASE NOTE that use of this NCCN Content is governed by the End-User License Agreement, and you MAY NOT distribute this Content or use it with any artificial intelligence model or tool.
Printed by Ambrish Chauhan on 5/1/2026 7:03:18 AM. Copyright © 2026 National Comprehensive Cancer Network, Inc. All Rights Reserved.

The mammographic final assessments are mandated by the Mammography Quality Standards Act and Program (MQSA) and are reported using the ACR BI-RADS assessment categories, which classify likelihood of the breast findings into six final assessment categories.[157] The BI-RADS assessment categories (which include words and numbers) help to standardize both the reporting of mammographic findings and the recommendations for further management. The assessment wording and numbers are often used interchangeably. The definitions of the mammogram assessment categories are outlined in *Mammographic Assessment Category Definitions* in the algorithm. Importantly, the same imaging terms are used for both asymptomatic and symptomatic individuals that are screened, which can create confusion regarding recommendations.

NCCN Recommendations for Screening Mammogram BI-RADS Assessment Categories 0, 1, 2, 3, 4, 5, and 6 are listed below. The NCCN recommendations following evaluation of symptomatic diagnostic individuals can be found in the next section. Importantly, negative or benign BI-RADS imaging assessments, in the setting of symptoms, rely upon correlation of clinical finding, which may indicate need for biopsy even with negative imaging. Conversely, suspicious imaging findings for those with clinical findings of very low suspicion still warrant biopsy.

For BI-RADS category 0 (incomplete), the NCCN Panel recommends diagnostic workup, including comparison to prior mammograms, and additional imaging evaluation with diagnostic mammogram with tomosynthesis and/or ultrasound as indicated.

For BI-RADS category 1 (negative finding) or category 2 (benign), the NCCN Panel recommends resuming routine screening.

For BI-RADS category 3 (probably benign), the NCCN Panel recommends diagnostic mammograms with tomosynthesis at 6 months, then every 6 to 12 months for up to 24 months as appropriate. If the lesion remains stable or resolves mammographically, the patient resumes routine screening intervals for mammography with tomosynthesis. If, in any of the interval mammograms, the lesion increases in size or changes its benign characteristics, a core needle biopsy is then performed. The exception to this approach of short-term follow-up is when the patient strongly desires a biopsy or in the setting of overriding clinical concern. In those cases, initial biopsy with histologic sampling may be a reasonable option.

For BI-RADS categories 4 and 5 (suspicious or highly suggestive of malignancy), tissue diagnosis using image-guided core needle biopsy is necessary. When a core needle biopsy is performed, concordance between the pathology report and the imaging finding must be obtained.[170,171] For example, a negative core needle biopsy associated with a spiculated category 5 mass (highly suggestive of malignancy) is discordant and clearly would not be an acceptable diagnosis. When the pathology and the imaging are discordant, surgical excision is recommended. Those with a benign result exhibiting pathology/image concordance may either resume routine screening or be followed with physical examination and/or imaging every 6 to 12 months for up to 1 year to assess for changes. If the exam or imaging findings remain stable, routine screening can resume. If the lesion increases in size or changes its benign characteristics, surgical excision is recommended.

For BI-RADS category 6 (proven malignancy), the patient should be cared for according to the NCCN Guidelines for Breast Cancer (available at www.NCCN.org).

Breast Ultrasonography

Imaging by ultrasound is an important adjunct for diagnosing breast cancer.[172] However, breast ultrasonography does not detect most microcalcifications.[40,52,173-175] The definitions of the ultrasound assessment

Version 1.2026 © 2026 National Comprehensive Cancer Network© (NCCN©), All rights reserved. NCCN Guidelines® and this illustration may not be reproduced in any form without the express written permission of NCCN.

PLEASE NOTE that use of this NCCN Content is governed by the End-User License Agreement, and you MAY NOT distribute this Content or use it with any artificial intelligence model or tool.
Printed by Ambrish Chauhan on 5/1/2026 7:03:18 AM. Copyright © 2026 National Comprehensive Cancer Network, Inc. All Rights Reserved.

categories are outlined in *Ultrasound Assessment Category Definitions* in the algorithm.

Diagnostic Breast MRI

MRI can also play a role in the diagnostic setting. For patients with skin changes consistent with serious breast disease, consideration of breast MRI with and without contrast is included in the guidelines for those with BI-RADS category 1–3 assessment or for those with benign biopsy of skin or nipple following BI-RADS category 4–5 assessment (see *Signs/Symptoms During Clinical Encounter: Skin Changes* in the algorithm). Since a benign skin punch biopsy in a patient with a clinical suspicion of inflammatory breast cancer (IBC) does not rule out malignancy, further evaluation is recommended. There is evidence that certain MRI features may facilitate diagnosis of IBC.[176] MRI with and without contrast may also be used for suspicious nipple inversion/retraction, nipple discharge, and axillary mass(es) expected to represent adenopathy when mammography and ultrasound are not diagnostic.[177-179]

Breast Tissue Biopsy

Breast biopsy is recommended if diagnostic imaging findings or clinical findings are suspicious (BI-RADS 4) or highly suggestive of malignancy (BI-RADS 5).

Fine-Needle Aspiration Biopsy

A fine-needle aspiration (FNA) biopsy involves use of a smaller-bore needle to obtain cytologic samples from a breast mass. Advantages of FNA biopsy include its minimally invasive methodology and low cost,[180,181] whereas the need for pathologists with specific expertise in the interpretation of test results and the necessity of performing a follow-up tissue biopsy when atypia or malignancy is identified are disadvantages of the procedure. FNA of nonpalpable lesions can be performed under imaging guidance (eg, ultrasound), although there is evidence to indicate that both core needle biopsy and excisional biopsy are more accurate than FNA in the evaluation of nonpalpable breast lesions.[182,183] The NCCN Panel only recommends use of FNA for symptomatic relief of a cyst or possible abscess.

Core Needle Biopsy

A core needle biopsy, also called percutaneous core breast biopsy, is a procedure that typically involves obtaining multiple cores of solid tissue using standard techniques.[184,185] It can be performed under imaging guidance (eg, stereotactic [mammographic], ultrasound, MRI) or directed by palpation. Advantages of breast core needle biopsy include: 1) increased accuracy over FNA when the procedure is performed in situations where no mass is palpable; and 2) an ability to obtain tissue samples of sufficient size so as to eliminate the need for a follow-up biopsy to confirm malignancy.[186] In some situations, the core needle biopsy is performed under vacuum assistance, which can facilitate collection of adequate tissue from a breast lesion without the need for multiple needle insertions.[187-189] Marker clip placement is done at the time of core needle biopsy so that the radiologist can identify the location of the lesion in the event that it is entirely removed with the core needle biopsy or disappears during neoadjuvant treatment of a breast cancer.[190] With a few exceptions, core needle biopsy is preferred in the NCCN Guidelines over surgical excision when tissue biopsy is required. Sensitivity for core needle biopsy directed by ultrasound or stereotaxis is 97% to 99%.[114] According to the NCCN Panel, surgical excision is appropriate if unable to perform core needle biopsy.

Excisional Biopsy

An excisional biopsy involves removal of the entire breast mass or suspicious area of the breast by a surgeon in an operating room setting. Needle or wire localization is done by the radiologist immediately prior to an excisional biopsy of a nonpalpable mammographic or sonographic

Version 1.2026 © 2026 National Comprehensive Cancer Network© (NCCN©), All rights reserved. NCCN Guidelines® and this illustration may not be reproduced in any form without the express written permission of NCCN.

PLEASE NOTE that use of this NCCN Content is governed by the End-User License Agreement, and you MAY NOT distribute this Content or use it with any artificial intelligence model or tool.
Printed by Ambrish Chauhan on 5/1/2026 7:03:18 AM. Copyright © 2026 National Comprehensive Cancer Network, Inc. All Rights Reserved.

finding to direct surgical excision. The wire localization may bracket a lesion that had a clip placed in it at the time of the core needle biopsy.[190] Newer localization methods using radionucleotide seeds, reflector devices, or magnetic devices are being explored.

Excisional biopsy is included in the NCCN Guidelines as an option when tissue biopsy is required. Although excisional biopsy is a more invasive method than core needle biopsy and requires needle localization when lesions are not palpable, there are situations where larger tissue samples may be needed. Excisional biopsy is recommended if the diagnosis by core needle biopsy is an indeterminate lesion, a benign lesion that is not concordant with imaging, ADH, non-classic LCIS (pleomorphic or florid LCIS), or other specific histologies that require additional tissue including mucin-producing lesions, potential phyllodes tumor, papillary lesions, radial scars, or other histologies of concern to the pathologist.[181,186,191,192] Select patients may be suitable for repeat core needle biopsy attempt. For select patients with other specific histologies (eg, classic LCIS, ALH, flat epithelial atypia [FEA], papillomas without atypia, fibroepithelial lesions favoring fibroadenoma, some ADH), excision may be considered depending on the level of suspicion. Support for this recommendation includes results of studies demonstrating an underestimation of cancer when atypical hyperplasia and LCIS are diagnosed by core needle biopsy.[193-198]

Diagnostic Evaluation for Symptomatic Findings on Physical Examination

In general, the breast imaging evaluations after physical exam include mammography with tomosynthesis and ultrasound. The addition of ultrasound to diagnostic mammography with tomosynthesis significantly increases cancer detection and detection of specific benign findings such as cysts. Imaging for individuals <30 years of age begins with ultrasound, while those ≥30 years of age generally have both studies unless a cyst is likely.[199-204] Combined negative imaging results place a patient in a very low risk of malignancy (generally <3%) category; however, clinical judgment is necessary as some individuals with negative imaging may warrant biopsy that may identify a malignant mass.[199,205-207] The recommendations for subsequent management follow imaging assessments and clinical level of suspicion. Imaging should precede biopsy in most situations due to potential alteration of imaging findings by the biopsy. BI-RADS imaging assessments, even if negative, must be correlated with the clinical findings prior to final clinical recommendations and do not stand alone as in the screening situation. There are clinical situations where biopsy is warranted even with negative imaging results.

Symptomatic or positive findings on physical examination include palpable symptom in the breast, acquired/new-onset nipple inversion/retraction without palpable mass, nipple discharge without a palpable symptom, skin changes, breast pain, axillary mass(es), and breast implant-related symptoms (>1-year post-implantation).

Palpable Symptom in the Breast

A palpable mass is a discrete lesion that can be readily identified during a physical exam. There are other palpable symptoms in the breast that warrant diagnostic evaluation, including new-onset asymmetric thickening/nodularity, asymmetric breast enlargement, or change in shape/contour of the breast (which may be due to implant rupture[208]). The NCCN Guidelines separate the evaluation of individuals with palpable symptoms into two age groups: those ≥30 years of age and those <30 years of age.

Those ≥30 Years of Age with Palpable Symptom

The main difference in the guidelines for evaluating a palpable symptom in those ≥30 years of age compared with those <30 years of age is the increased degree of suspicion of breast cancer. The initial evaluation begins with a diagnostic mammogram with tomosynthesis and ultrasound.

Version 1.2026 © 2026 National Comprehensive Cancer Network© (NCCN©), All rights reserved. NCCN Guidelines® and this illustration may not be reproduced in any form without the express written permission of NCCN.

PLEASE NOTE that use of this NCCN Content is governed by the End-User License Agreement, and you MAY NOT distribute this Content or use it with any artificial intelligence model or tool.
Printed by Ambrish Chauhan on 5/1/2026 7:03:18 AM. Copyright © 2026 National Comprehensive Cancer Network, Inc. All Rights Reserved.

CEM in combination with ultrasound may be used as an alternative if available. Ultrasound should be geographically correlated with the palpable symptom in question. Observation without further evaluation is not an option for these individuals. There are some clinical circumstances, such as mass with low clinical suspicion on CBE or suspected simple cyst, in which ultrasound would be preferred and may suffice for those 30 to 39 years of age due to the high sensitivity of ultrasound alone.[202,203,209] After the diagnostic imaging assessment, the abnormality is placed into one of the following categories: negative or benign; probably benign; or suspicious or highly suggestive of cancer with management following BI-RADS final assessment recommendations.

If there is a lack of geographic correlation between clinical and imaging findings, further evaluation is recommended. Sensitivity of combined mammography and ultrasound for evaluation of palpable masses is high for cancer detection, although specificity may be relatively low.

For those with mammographic or ultrasound findings that are suspicious or highly suggestive of breast cancer, the NCCN Panel recommends core needle biopsy. When core needle biopsy is utilized, concordance between pathology, imaging, and clinical findings must be obtained.

Mammographic and/or Ultrasound Findings Corresponding to Palpable Symptom

BI-RADS Category 1; Low Clinical Suspicion

No imaging abnormality detected on mammogram and/or ultrasound is a BI-RADS category 1 finding. The negative predictive value of negative imaging is high, >96%.[199,203,205-207] For palpable masses with negative mammography and/or ultrasound, and clinical suspicion for breast cancer is low, the NCCN Panel recommends physical examination at 3 to 6 months. Patients should also be instructed to monitor for and report any changes to their breasts. If the palpable symptom remains stable or decreases in size, routine screening can resume. If there is a significant increase in size of the palpable symptom or clinical suspicion has increased, additional age-appropriate diagnostic evaluation is warranted.

BI-RADS Category 1; Clinically Suspicious

For palpable masses that are clinically suspicious but with negative mammography and/or ultrasound, the NCCN Panel recommends appropriate clinical management, which may include referral to a breast specialist, supplemental imaging, and/or tissue sampling.

BI-RADS Category 2; Low Clinical Suspicion

For palpable masses found to be benign and concordant on mammography and/or ultrasound, and clinical suspicion for breast cancer is low, routine screening can resume. Aspiration may be considered for symptomatic relief of cysts.

Simple cystic masses fall into this category. Breast cysts are classified as simple, complicated, or complex based on the characteristics identified by ultrasound evaluation (see Table 1 for definitions). A cyst meeting all criteria of a simple cyst is considered to be benign (ie, BI-RADS 2)[40,210] if the clinical findings and ultrasonographic results are concordant. In a retrospective analysis of females (n = 14,602) with benign breast biopsies developing subsequent breast cancer, it was noted that simple cysts were not associated with subsequent breast cancer development.[211]

BI-RADS Category 2; Clinically Suspicious

For palpable masses that are found to be benign on mammography and/or ultrasound, but are clinically suspicious, the NCCN Panel recommends appropriate clinical management, which may include referral to a breast specialist, supplemental imaging, and/or tissue sampling.

BI-RADS Category 3; Low Clinical Suspicion

Version 1.2026 © 2026 National Comprehensive Cancer Network© (NCCN©), All rights reserved. NCCN Guidelines® and this illustration may not be reproduced in any form without the express written permission of NCCN.

For palpable masses suspected to be probably benign on mammography and/or ultrasound, and clinical suspicion for breast cancer is low, the NCCN Panel recommends physical examination and imaging, with ultrasound or diagnostic mammogram with tomosynthesis to assess for changes. Probably benign findings are typically monitored at 6, 12, and 24 months. If a return visit is uncertain, or if the patient has a strong preference, core needle biopsy may be considered. Patients should also be encouraged to monitor and report any changes to their breasts. If the palpable symptom remains stable or decreases in size, or if imaging characteristics are now definitively benign, routine screening can resume. If there is a significant increase in size of the palpable symptom or clinical suspicion has increased, tissue sampling is recommended. Core needle biopsy is preferred; however, in some circumstances FNA may be sufficient.

Complicated cysts fall into this category and are associated with a low risk of malignancy.[40,212-214]

BI-RADS Category 3; Clinically Suspicious

For palpable masses suspected to be probably benign on mammography and/or ultrasound, but are clinically suspicious, the NCCN Panel recommends tissue sampling. While core needle biopsy is preferred, FNA may be sufficient in certain circumstances.

BI-RADS Category 4–5

For palpable masses considered to be suspicious (ie, BI-RADS category 4) or highly suggestive of malignancy (ie, BI-RADS category 5) on mammography and/or ultrasound, the NCCN Panel recommends core needle biopsy. It is important to confirm geographic correlation between clinical and imaging findings.

Complex cysts, which have both cystic and solid components, fall into this category. Complex cysts have a relatively high risk of malignancy (eg, 14% and 23% in 2 studies).[40,192,213-215]

Those <30 Years of Age with Palpable Symptom

The preferred option for initial evaluation of a palpable symptom that is clinically suspicious in an individual <30 years of age is to proceed directly to ultrasound.[202,216] Diagnostic mammogram with tomosynthesis should be performed if ultrasound results are highly suspicious for malignancy.[216] Tissue sampling prior to imaging is not recommended. From this point, the decision tree for those <30 years of age with clinically suspicious symptoms is identical to the pathway for those ≥30 years of age.

Because the incidence of malignancy in those who are <30 years of age is low, observation of the symptom for one or two menstrual cycles can be considered in cases with low suspicion on CBE. If observation is elected and the symptom resolves after one or two menstrual cycles, the patient may return to routine screening. If the symptom persists, ultrasound should be performed.

Follow-up After Aspiration Following a Clinically Suspicious BI-RADS 2 Finding

Following FNA of a palpable, clinically suspicious BI-RADS 2 mass, if the mass resolves and non-bloody cyst fluid was obtained, the NCCN Panel recommends resumption of routine screening.

If the mass resolves, but non-traumatic bloody fluid was obtained, a marker clip should be placed and the fluid should be sent to cytology. If cytology is negative, short-term clinical and imaging follow-up or core needle biopsy can be considered. If the fluid is atypical or malignant, surgical consultation is recommended. There are some circumstances in which cytology may be sufficient. If cytology is concordant, further tissue sampling may not be needed.

Version 1.2026 © 2026 National Comprehensive Cancer Network© (NCCN©), All rights reserved. NCCN Guidelines® and this illustration may not be reproduced in any form without the express written permission of NCCN.

PLEASE NOTE that use of this NCCN Content is governed by the End-User License Agreement, and you MAY NOT distribute this Content or use it with any artificial intelligence model or tool.
Printed by Ambrish Chauhan on 5/1/2026 7:03:18 AM. Copyright © 2026 National Comprehensive Cancer Network, Inc. All Rights Reserved.

If the mass persists, ultrasound with image-guided core needle biopsy is recommended. A marker clip should be placed and tissue should be sent to pathology.

Follow-up After Core Needle Biopsy

If the biopsy result indicates benign pathology, and this finding is concordant with the imaging results, the NCCN Panel recommends resumption of routine screening. Based on level of clinical suspicion, physical examination at 6 or 12 months, with or without ultrasound or mammogram with tomosynthesis, for up to 1 year may be considered to assess for changes. Concordance is established by the radiologist or breast specialist after review of the core needle biopsy pathology report and imaging findings. This may require discussion or review with the pathologist as well. However, if the biopsy result indicates benign pathology, and this finding is discordant with imaging results, the NCCN Panel recommends surgical excision; however, in certain situations, at the discretion of the radiologist, repeat attempt at percutaneous sampling may be warranted.

If the diagnosis by tissue biopsy is an indeterminate lesion, the NCCN Panel recommends either surgical excision or repeat core needle biopsy. If the diagnosis by tissue biopsy is ADH or non-classic LCIS (pleomorphic or florid LCIS), the NCCN Panel recommends complete surgical excision with negative margins. However, outcomes data regarding treatment of individuals with non-classic LCIS are limited, due in part to a paucity of histologic categorization of variants of LCIS. Select patients with ADH may be suitable for monitoring in lieu of surgical excision.

For select patients with other specific histologies (eg, classic LCIS, ALH, FEA, papillomas without atypia, fibroepithelial lesions favoring fibroadenoma, radial scars without atypia that were adequately sampled), routine excision is not generally required; however, surgical excision is recommended if pathology is discordant with imaging. Other histologies that may require additional tissue include mucin-producing lesions, potential phyllodes tumor, papillary lesions, radial scars, or other histologies of concern to the pathologist.

For patients with other specific histologies as described above, with pathology that is concordant with imaging, the NCCN Panel recommends resumption of routine screening or physical examination and/or imaging at 6 to 12 months for up to 1 year to assess for changes. There may be variability on the follow-up interval based on the level of suspicion. Counseling for risk assessment as outlined in the NCCN Guidelines for Breast Cancer Risk Reduction (available at www.NCCN.org) is also recommended.

Any malignant findings with biopsy should be treated according to the NCCN Guidelines for Breast Cancer (available at www.NCCN.org).

Follow-up After Surgical Excision

Following surgical excision, if pathology is benign, the NCCN Panel recommends resumption of routine screening.

If pathology reveals ADH, ALH, classic LCIS, or non-classic LCIS (pleomorphic or florid LCIS), routine screening can resume. Counseling for risk reduction as outlined in the NCCN Guidelines for Breast Cancer Risk Reduction (available at www.NCCN.org) is also recommended. Complete excision with negative margins would typically be performed for non-classic LCIS; however, outcomes data regarding treatment of individuals with non-classic LCIS are limited, due in part to a paucity of histologic categorization of variants of LCIS. If surgical excision results are not concordant with imaging or core needle biopsy results, clinical correlation is recommended.

If pathology is malignant, patients should be treated according to the NCCN Guidelines for Breast Cancer (available at www.NCCN.org).

Version 1.2026 © 2026 National Comprehensive Cancer Network© (NCCN©), All rights reserved. NCCN Guidelines® and this illustration may not be reproduced in any form without the express written permission of NCCN.

PLEASE NOTE that use of this NCCN Content is governed by the End-User License Agreement, and you MAY NOT distribute this Content or use it with any artificial intelligence model or tool.
Printed by Ambrish Chauhan on 5/1/2026 7:03:18 AM. Copyright © 2026 National Comprehensive Cancer Network, Inc. All Rights Reserved.

Nipple Inversion/Retraction Without Palpable Mass

In patients with acquired or new onset of nipple retraction, the NCCN Panel recommends CBE with attention to the color of the nipple; the presence and color of nipple discharge (see also *Nipple Discharge Without a Palpable Symptom*); evidence of inflammation (see also *Skin Changes)* such as erythema; the presence of a fistula on the areola or nipple; purulent discharge; or tenderness. Breast imaging should also be obtained, with breast ultrasound recommended for those <30 years of age and diagnostic mammogram with tomosynthesis and breast ultrasound recommended for those ≥30 years of age.

If mammographic and/or ultrasound findings are found to be negative (ie, BI-RADS category 1) or benign (ie, BI-RADS category 2) and the clinical suspicion for breast cancer is low, routine screening can be resumed. Patients should also be instructed to monitor for and report any changes to their symptoms. If there is clinical suspicion, consideration should be made for obtaining a breast MRI with and without contrast and/or referring the patient to a breast specialist. If clinical and/or MRI findings are abnormal, core needle biopsy is recommended. If clinical and MRI findings are normal, further imaging with ultrasound or diagnostic mammogram with tomosynthesis should be obtained to assess for changes. Probably benign findings are typically monitored at 6, 12, and 24 months.

If mammographic and/or ultrasound findings are suspected to be probably benign (ie, BI-RADS category 3) and the clinical suspicion for breast cancer is low, the NCCN Panel recommends physical exam with or without diagnostic mammogram with tomosynthesis or ultrasound for 1 to 2 years. Patients should also be instructed to monitor for and report any changes to their symptoms. If there is clinical suspicion, follow-up mirrors that for clinically suspicious BI-RADS category 1 or category 2 findings.

If mammographic and/or ultrasound findings are considered to be suspicious (ie, BI-RADS category 4) or highly suggestive of malignancy (ie, BI-RADS category 5), the NCCN Panel recommends core needle biopsy. If the abnormality is not amenable to core biopsy, surgical excision is recommended.

For patients with congenital or lifelong nipple inversion without recent changes, reassurance can be provided, and routine screening can resume. Patients should also be instructed to monitor for and report any changes to their symptoms. In the setting of recent changes to a congenital or lifelong nipple inversion, the clinical pathway mirrors the pathway for acquired or new onset of nipple retraction.

Nipple Discharge without a Palpable Symptom

Nipple discharge is common, and, in many cases, unrelated to breast pathology.[217-223] For example, non-spontaneous discharge from multiple breast ducts in an individual who is not lactating can occur during pregnancy, following breast stimulation, in the setting of certain thyroid conditions, and in those taking certain medications, such as estrogen, oral contraceptives, opiates, and particular psychoactive drugs or antihypertensive agents.[217,224]

Suspicion of underlying pathology (eg, ductal carcinoma, papilloma) is raised when nipple discharge is persistent and reproducible on examination, spontaneous, unilateral, from a single duct, and clear or bloody.[225] An endocrine workup should be considered in the setting of bilateral milky discharge.

In patients with a nipple discharge but no palpable symptom, an evaluation of the characteristics of the nipple discharge is the first step. Nipple smear cytology and ductography are not recommended. The appropriate follow-up of non-spontaneous or multiple-duct discharge in those <40 years of age is observation, coupled with education to stop compression of the breast and to report the development of any spontaneous discharge. In those ≥40 years of age, screening mammography with tomosynthesis

Version 1.2026 © 2026 National Comprehensive Cancer Network© (NCCN©), All rights reserved. NCCN Guidelines® and this illustration may not be reproduced in any form without the express written permission of NCCN.

should be performed if not done within the past year, with further workup based on the BI-RADS category, and education should be provided similar to for those <40 years of age. Evaluation of this type of nipple discharge is based on the overall BI-RADS category of the diagnostic mammogram with tomosynthesis, if not done previously.

Patients presenting with no palpable symptom but with discharge that is persistent and reproducible on examination, spontaneous, unilateral, single-duct, and clear or bloody are imaged with age-appropriate imaging. For those <30 years of age, ultrasound with or without diagnostic mammogram with tomosynthesis is recommended. For those ≥30 years of age, both diagnostic mammography with tomosynthesis and ultrasound are recommended. Several clinical studies have established a very low risk of malignancy when mammogram and ultrasound are negative.[226,227] In certain situations, MRI may play an adjunctive role, aiding in identifying a possible abnormality and its location. Several studies have shown that breast MRI aids in the diagnosis of suspected ductal disease.[177-179,228-230]

According to the NCCN Panel, when an overall imaging BI-RADS assessment is category 1–3 (negative, benign, or probably benign),[231] an MRI with and without contrast should be performed and the patient should be referred for surgical consultation. If subsequent MRI assessment is BI-RADS category 1–3, management options include duct excision[231] based on clinical suspicion or patient preference or follow-up with physical exam every 6 months, with or without imaging, for 1 to 2 years, with imaging modality dependant on the original imaging. Patients should also be instructed to monitor for and report any changes in symptoms. For those referred for duct excision with subsequent benign pathology, routine screening can be resumed. Malignant findings should be managed according to the NCCN Guidelines for Breast Cancer (available at www.NCCN.org). For those who are followed with physical exam with or without imaging and symptoms remain stable or resolve, routine screening can be resumed. If there is suspicious progression in symptoms, core needle biopsy (if an imaging abnormality is present) or surgical excision is recommended.

When mammographic and/or ultrasound or follow-up MRI assessment is BI-RADS category 4 or 5 (suspicious or highly suggestive of malignancy), the NCCN Panel recommends core needle biopsy. Surgical excision is recommended if core needle biopsy is not possible. If the pathology findings are benign, referral for surgical duct excision is recommended. If findings are indicative of malignancy, the patient should be treated according to the NCCN Guidelines for Breast Cancer (available at www.NCCN.org).

Skin Changes

Any type of unusual skin changes around the breast may represent serious disease and require evaluation. IBC should be considered when dermal pitting or dimpling (peau d'orange), skin thickening, and breast erythema and edema are present, and nipple excoriation, scaling, and skin ulceration should increase clinical suspicion of Paget's disease. IBC is a rare, aggressive form of breast cancer estimated to account for 1% to 6% of breast cancer cases in the United States. IBC is a clinical diagnosis that requires erythema and dermal edema of a third or more of the skin of the breast with a palpable border to the erythema.[232,233] Paget's disease of the breast is a rare manifestation of breast cancer characterized by neoplastic cells in the epidermis of the nipple areolar complex. It most commonly presents with scaling or eczematous changes of the nipple, bleeding, ulceration, and itching of the nipple. The diagnosis is often delayed because of the rare nature of the condition and confusion with other dermatologic conditions.[234] Pure Paget's disease is frequently occult on mammography[235] and a negative mammogram does not exclude Paget's disease, which requires skin biopsy of the nipple changes.

Version 1.2026 © 2026 National Comprehensive Cancer Network© (NCCN©), All rights reserved. NCCN Guidelines® and this illustration may not be reproduced in any form without the express written permission of NCCN.

PLEASE NOTE that use of this NCCN Content is governed by the End-User License Agreement, and you MAY NOT distribute this Content or use it with any artificial intelligence model or tool.
Printed by Ambrish Chauhan on 5/1/2026 7:03:18 AM. Copyright © 2026 National Comprehensive Cancer Network, Inc. All Rights Reserved.

In patients with a history of prior RT, skin changes such as skin thickening or skin discoloration should raise suspicion for radiogenic angiosarcoma of the breast (RASB), which is a rare, late possible complication of breast RT associated with poor prognosis.[236] RASB can have a diverse clinical presentation and may present with nodular, patch-like, or plaque-like lesions. Lesions are most commonly black, blue, or purple and may appear as telangiectasia-like formations.

The initial evaluation of a patient with breast skin changes begins with a diagnostic mammogram with tomosynthesis, with or without ultrasound imaging. If the imaging results are abnormal, the evaluation proceeds based on the imaging findings. If the breast imaging results are normal, further workup is still needed. If clinical suspicion is low for IBC or highly suspicious for infection, a short trial (eg, 7–10 days) of antibiotics with short-term clinical follow-up after completion of antibiotics to assess for improvement/resolution may be considered. Similarly, if clinical suspicion is low for Paget's disease or highly suspicious for eczema, a short trial of topical steroids with clinical follow-up in 1 to 4 weeks to assess for improvement/resolution may be considered. In either case, if the skin changes have not improved or resolved, further workup is indicated.

Referral to a breast specialist and breast MRI with and without contrast should be considered following imaging findings consistent with an overall BI-RADS assessment category 1–3 (negative, benign, or probably benign). If clinical and/or MRI findings are abnormal, tissue sampling is recommended. For abnormal clinical findings, biopsy of the skin or nipple is recommended. For abnormal MRI findings, core needle biopsy is recommended. Of note, IBC is a clinical diagnosis and is not dependent on a positive skin biopsy. If both clinical and MRI findings are normal, further imaging with ultrasound or diagnostic mammogram with tomosynthesis should be obtained to assess for changes. Probably benign findings are typically monitored at 6, 12, and 24 months.

A tissue biopsy should be performed if imaging findings are consistent with an overall BI-RADS assessment category 4–5 (suspicious or highly suggestive of malignancy). According to the NCCN Panel, core needle biopsy is the preferred option. A benign skin biopsy does not rule out malignancy when clinical suspicion of IBC is high, and further evaluation is recommended. If biopsy results are benign, surgical referral, biopsy of the skin or nipple, or MRI with and without contrast should be considered. A biopsy showing a malignant finding should be managed according to the NCCN Guidelines for Breast Cancer (available at www.NCCN.org).

Persistent or Severe Breast Pain

Breast pain is the most common symptom in the breast. Individuals presenting with breast pain fear that this is a symptom of breast cancer, therefore causing significant anxiety. The risk of cancer in a female presenting with breast pain as the only symptom is low, between 1.2% and 6.7%.[7,161,237,238]

Breast pain is considered persistent if present for a minimum of 4 to 6 weeks. During the first 4 to 6 weeks of breast pain, symptomatic management is appropriate if the patient is without other symptoms such as associated redness or mass. If other symptoms are present, physical examination should be done at that time.

Evaluation of persistent and severe breast pain includes comprehensive history, type of pain, relationship to menses, duration, location, impact on activities of daily living, factors that aggravate/alleviate pain, any other medical problems and comorbidities, and a thorough CBE. If CBE does not identify a physical abnormality such as palpable symptoms, nipple discharge, or skin changes; the pain is cyclic; or diffuse and non-focal (larger than a quadrant) and screening mammograms are current and negative or benign, the NCCN Panel recommends providing reassurance to the patient and providing symptomatic treatment of breast related pain if needed or desired (eg, over-the-counter pain medications, if needed; use

Version 1.2026 © 2026 National Comprehensive Cancer Network© (NCCN©), All rights reserved. NCCN Guidelines® and this illustration may not be reproduced in any form without the express written permission of NCCN.

PLEASE NOTE that use of this NCCN Content is governed by the End-User License Agreement, and you MAY NOT distribute this Content or use it with any artificial intelligence model or tool.
Printed by Ambrish Chauhan on 5/1/2026 7:03:18 AM. Copyright © 2026 National Comprehensive Cancer Network, Inc. All Rights Reserved.

of a good support bra; ice packs or heating pads).[239] Cyclical breast pain may often spontaneously resolve. Reassurance alone has shown to help resolve the symptom in 86% of females with mild pain and 52% of females with severe pain.[240] Patients with non-breast related pain may be referred back to the original provider for management.

If the breast pain is focal in nature, the NCCN Panel recommends age-appropriate diagnostic imaging (ultrasound with diagnostic mammogram with tomosynthesis for those ≥30 years of age; and ultrasound for those <30 years of age). There are some clinical circumstances such as a suspected painful simple cyst in which ultrasound would be preferred as the first imaging modality and may suffice for individuals aged 30 to 39 years. Mammogram may not be necessary if performed and results were negative within the past 6 months. Conversely, for those <30 years of age, there are some clinical circumstances, such as when clinical suspicion for malignancy is high, that diagnostic mammogram with tomosynthesis would be preferred over ultrasound.

For those with BI-RADS assessment category 1 (negative findings), the NCCN Panel recommends appropriate symptomatic management of breast pain. For a simple cyst (benign or BI-RADS assessment category 2) geographically correlated with focal pain, drainage may be considered for symptom relief. For complicated cysts, aspiration may be considered. For those with BI-RADS assessment category 3 (probably benign) findings, the Panel recommends physical examination and imaging, with follow-up ultrasound and/or diagnostic mammogram with tomosynthesis to assess for changes. Probably benign findings are typically monitored at 6, 12, and 24 months. If imaging indicates possible abscess as the cause of focal pain, antibiotics, aspiration, and/or surgical consultation should be considered. If imaging or exam findings remain stable or resolve, or if there are now definitively benign imaging characteristics, routine screening can resume. If imaging or exam findings significantly increase in size or if level of suspicion increases, core needle biopsy is recommended. Core needle biopsy should also be performed if imaging findings are consistent with an overall BI-RADS assessment category 4–5 (suspicious or highly suggestive of malignancy).

Axillary Mass(es) Suspected to Represent Adenopathy

Localized axillary masses are more often related to benign disorders than malignancy.[241] Masses may relate to axillary lymph nodes, accessory breast tissue in the axilla, or other soft tissue abnormality. Infections, inflammation, and malignancy can cause lymphadenopathy. Breast implants can also cause benign axillary lymphadenopathy.[242] However, when cancer is identified in the axillary lymph nodes, breast cancer is the most common cause of axillary lymphadenopathy. In a study evaluating 31 patients with isolated axillary masses, 9 of the 17 patients with cancer had occult breast cancer (5 in the contralateral breast).[243]

For an individual presenting with a unilateral axillary mass expected to represent adenopathy, the NCCN Panel recommends imaging with diagnostic mammogram with tomosynthesis and ultrasound. Diagnostic mammogram with tomosynthesis is optional in those <30 years of age unless ultrasound results are suspicious. CEM may be considered in lieu of mammogram if available when clinically suspicious. If imaging findings are suspicious for malignancy, tissue sampling is recommended. If lymphoma is suspected, the tissue or specimen may require special pathologic processing and/or surgical excision. If tissue sampling results indicate malignancy of breast origin, management per the NCCN Guidelines for Breast Cancer (available at www.NCCN.org) is recommended. If no breast mass is evident, the Panel also recommends a breast MRI with and without contrast. If tissue sampling results indicate malignant axillary lymph node of non-breast origin, the Panel recommends referring to the appropriate NCCN Guidelines for management. A

Version 1.2026 © 2026 National Comprehensive Cancer Network© (NCCN©), All rights reserved. NCCN Guidelines® and this illustration may not be reproduced in any form without the express written permission of NCCN.

PLEASE NOTE that use of this NCCN Content is governed by the End-User License Agreement, and you MAY NOT distribute this Content or use it with any artificial intelligence model or tool.
Printed by Ambrish Chauhan on 5/1/2026 7:03:18 AM. Copyright © 2026 National Comprehensive Cancer Network, Inc. All Rights Reserved.

unilateral axillary mass with negative or benign imaging or tissue sampling findings should be clinically managed, as appropriate depending on the level of clinical suspicion, which may include a referral to a breast specialist, supplemental imaging, and/or tissue sampling if not done previously.

For an individual presenting with bilateral axillary masses suspected to represent adenopathy, the NCCN Panel recommends complete clinical evaluation to assess for other sites of adenopathy and potential non-breast etiologies of adenopathy, including but not limited to lupus, rheumatoid arthritis, or HIV infection.[244] Recent vaccination status should also be assessed, as lymphadenopathy is common following vaccines that elicit a strong immune response, reported in up to 16% of individuals following COVID-19 vaccination.[245] In a study examining the effect of influenza vaccination on fluorodeoxyglucose (FDG)-PET/CT imaging in patients with cancer, FDG uptake in the axillary lymph nodes was increased in 50% of individuals who received the vaccine within 1 week before the FDG-PET/CT.[246] If no systemic disease is found, evaluation recommendations mirror those for unilateral adenopathy. If systemic disease is discovered, appropriate clinical management is recommended, which may include a referral to a breast specialist, supplemental imaging, and/or tissue sampling. If malignancy is discovered, the NCCN Panel recommends referring to the appropriate NCCN Guidelines for management.

Breast Implant-Related Symptoms

Individuals with breast implants have a very small risk of developing breast implant-associated anaplastic large cell lymphoma (BIA-ALCL) and breast-implant associated squamous cell carcinoma (BIA-SCC). BIA-ALCL is a rare type of peripheral T-cell lymphoma that occurs on average 7.5 to 11 years following implantation.[247] BIA-SCC is also exceedingly rare, with only 19 cases reported in current literature.[248] The majority of cases of BIA-ALCL have been associated with textured implants, while BIA-SCC is associated with either smooth or textured implants.[249]

For those with breast implant-related symptoms concerning for BIA-ALCL (eg, effusion, enlargement, mass), or BIA-SCC (eg, ulceration) occurring >1 year post-implantation, the NCCN Panel recommends consultation with a multidisciplinary team with experience in managing BIA-ALCL and BIA-SCC.

Presentation of Signs and Symptoms in Individuals Assigned Male at Birth

For individuals assigned male at birth with bilateral breast enlargement consistent with gynecomastia or pseudogynecomastia, reassurance should be provided. Appropriate clinical management of gynecomastia or pseudogynecomastia depends on the age of the patient, presence of symptoms, and the presumed cause, whether drug-induced or related to hypogonadism or hyperthyroidism.

For individuals assigned male at birth with presumed asymmetric gynecomastia, a palpable symptom not explained by gynecomastia, or with bloody nipple discharge, the NCCN Panel recommends diagnostic mammogram with tomosynthesis, with or without ultrasound. Mammograms are not generally performed prior to age 25 years for individuals assigned male at birth.

For BI-RADS assessment category 1–3 (negative, benign, or probably benign) findings, the NCCN Panel recommends appropriate clinical management, which may include surgical referral for suspicious clinical findings.

For BI-RADS assessment category 4–5 (suspicious or highly suggestive of malignancy) findings, the NCCN Panel recommends core needle biopsy.

Version 1.2026 © 2026 National Comprehensive Cancer Network© (NCCN©), All rights reserved. NCCN Guidelines® and this illustration may not be reproduced in any form without the express written permission of NCCN.

PLEASE NOTE that use of this NCCN Content is governed by the End-User License Agreement, and you MAY NOT distribute this Content or use it with any artificial intelligence model or tool.
Printed by Ambrish Chauhan on 5/1/2026 7:03:18 AM. Copyright © 2026 National Comprehensive Cancer Network, Inc. All Rights Reserved.

Breast Imaging During Pregnancy and Lactation

Pregnancy-associated breast cancer (PABC) is defined as breast cancer occurring during pregnancy, while breastfeeding, or within 1 year of delivery. PABC complicates approximately 1 in 3000 to 1 in 10,000 pregnancies[250] and is the most common invasive cancer diagnosed during pregnancy.[251]

Pregnancy and lactation are associated with profound changes in the structure of the breast. Breast changes during this time are due to hyperplasia and hypertrophy of the breast ducts and breast lobules with a substantial increase in the overall fluid content of the breast as well as a significant reduction of stromal adipose tissue. With lactation, under the influence of prolactin, there is production of milk with distention of the ducts as well as further propagation and enlargement of the lobular alveoli. As a result of these changes, there are visible alterations in the appearance of breast tissue in all modes of breast imaging as well as palpable changes on CBE.[252] These changes in the breast can lead to both reduction in the sensitivity of detecting small breast cancers, and also reduce the specificity of breast imaging (ie, more false-positive results).[253] Similarly, the breast changes resulting from pregnancy and lactation may result in a reduced ability to detect small breast cancers on CBE or may result in suspicious breast changes due to normal, physiologic changes.

Delayed diagnosis of breast cancer during pregnancy or lactation does occur, which may result in individuals presenting with more advanced disease, larger tumors, and a greater likelihood of axillary nodal disease positivity.[254,255] More advanced breast cancers during pregnancy and lactation may occur as a result of changing physical characteristics of the breast as well as a reluctance to pursue breast imaging when suspicious clinical findings are detected. It remains uncertain whether the more advanced breast cancers diagnosed during pregnancy and lactation compared to age-matched individuals is due to delayed diagnosis or due to increased biologic aggressiveness of PABC during pregnancy and lactation. More biologically aggressive tumors associated with PABC are theorized based on these tumors arising in the altered biology (more triple-negative tumors compared to age-matched controls), hormonal and immunologic milieu of pregnancy and lactation.

Avoiding ionizing radiation during pregnancy is frequently on the minds of both individuals and their providers. It should be reassuring to them that mammography results in extremely low fetal ionizing radiation doses, substantially below suspicious worrisome thresholds for harm.[256,257] The generally accepted minimum threshold for inducing fetal teratogenic effect is 50 mGy.[256,258,259] The measured fetal radiation dose from a 4-view mammogram is <0.03 mGy, a magnitude of difference approximating 1600-fold.[260] While there are no specific studies evaluating the sensitivity and specificity of mammogram with tomosynthesis compared to digital mammography in pregnancy, the improved specificity of mammogram with tomosynthesis in dense breast tissue in individuals who are not pregnant may make this modality particularly useful in this setting of increased breast density in individuals who are pregnant and lactating. While there may be a small increase in ionizing radiation delivery with mammogram with tomosynthesis compared to digital mammography, this small increase should not have any expected effect on fetal safety and appropriate diagnostic mammography should not be withheld.

In individuals who are lactating, nursing or breast pumping prior to mammography may improve sensitivity by decreasing the density of the breast parenchyma.[260] Mammography is always appropriate in individuals who are lactating who have an indication. There is no contraindication to diagnostic mammogram with tomosynthesis or routine screening mammography with tomosynthesis in individuals when lactating, and if an individual is due for their routine screening mammogram with tomosynthesis, this should not be delayed due to ongoing lactation.

Version 1.2026 © 2026 National Comprehensive Cancer Network© (NCCN©), All rights reserved. NCCN Guidelines® and this illustration may not be reproduced in any form without the express written permission of NCCN.

PLEASE NOTE that use of this NCCN Content is governed by the End-User License Agreement, and you MAY NOT distribute this Content or use it with any artificial intelligence model or tool.
Printed by Ambrish Chauhan on 5/1/2026 7:03:18 AM. Copyright © 2026 National Comprehensive Cancer Network, Inc. All Rights Reserved.

The use of contrast-enhanced breast MRI during pregnancy is contraindicated because gadolinium in all forms crosses the placenta and enters the fetal circulation.[259,261,262] There are concerns that the gadolinium ion may then dissociate in the fetal circulation and cause toxicity for the fetus. The exact frequency of this occurring and the associated impact of dissociated gadolinium on fetal toxicity is uncertain as there are no reliable data on fetal safety of gadolinium exposure during pregnancy. Therefore, gadolinium administered with breast MRI is best avoided during pregnancy, and other modes of breast imaging should be used. Non-contrast MRI is not recommended due to lack of sensitivity.

It is recommended that individuals who are lactating either pump the breast or breastfeed just prior to imaging to improve sensitivity and comfort of the examination. Fortunately, there is minimal excretion of gadolinium into human breast milk, with <1% of permitted neonatal dose of contrast over the first 24 hours after maternal administration.[263] Breast MRI appears to be highly sensitive for the detection of known PABC, although there appears to be lower specificity of breast MRI (higher false-positive rate) in individuals who undergo breast MRI while still lactating.[264] If individuals undergo breast MRI, due to the minimal contrast excretion into breast milk, individuals are not required to “pump and discard” breast milk after administration.[259] The ACR states that there is no role for molecular breast imaging (Tc-99m Sestamibi MBI) in breast cancer screening or evaluation of breast complaints during pregnancy or lactation and is in fact contraindicated in screening during pregnancy.[261,265]

Breast Cancer Screening During Pregnancy and Lactation

Screening in Individuals ≥40 Years at Average Risk of Breast Cancer

Recommendations for breast cancer screening in individuals ≥40 years of age who are pregnant or lactating and who are at average risk for developing breast cancer include a CBE and mammogram with tomosynthesis. While ionizing radiation exposure with mammography is manyfold below the threshold of fetal teratogenesis,[260] due to the infrequency of PABC[250] and the decreased sensitivity and specificity of mammography during pregnancy and lactation,[253] providers and patients may implement a short delay in routine breast imaging based on date of delivery and/or prior imaging in individuals who are at average risk of breast cancer until after pregnancy and lactation. There are no data evaluating the use of ultrasound alone as an alternative screening method in individuals at average risk of breast cancer during pregnancy or lactation; therefore, it is not recommended as an alternative to screening mammography. Supplemental screening should be considered for individuals who are pregnant and lactating who have heterogenous or extremely dense breasts and are at average risk of breast cancer.

Screening in Individuals at Increased Risk of Breast Cancer

Recommendations for breast cancer screening in individuals at increased risk of developing breast cancer who are pregnant or lactating include CBE and age-appropriate mammogram with tomosynthesis. The use of screening ultrasound alone has not been evaluated as a method to reduce breast cancer mortality in individuals who are pregnant or lactating and are at increased risk for breast cancer. While contrast-enhanced MRI is not recommended during pregnancy due to the trans-placental passage of gadolinium,[259,261,262] it is appropriate to recommend screening breast MRI at routine intervals for individuals at increased risk of developing breast cancer who are lactating given the minimal excretion of gadolinium into human breast milk.[257,263,266]

Management of Breast Signs and Symptoms During Pregnancy and Lactation

Palpable Symptom

Age-appropriate evaluation of a palpable symptom during pregnancy or lactation should proceed similar to that for individuals who are not pregnant or lactating (see *Palpable Symptom* in the algorithm). If

Version 1.2026 © 2026 National Comprehensive Cancer Network© (NCCN©), All rights reserved. NCCN Guidelines® and this illustration may not be reproduced in any form without the express written permission of NCCN.

PLEASE NOTE that use of this NCCN Content is governed by the End-User License Agreement, and you MAY NOT distribute this Content or use it with any artificial intelligence model or tool.
Printed by Ambrish Chauhan on 5/1/2026 7:03:18 AM. Copyright © 2026 National Comprehensive Cancer Network, Inc. All Rights Reserved.

mammographic and/or ultrasound imaging is negative and findings are clinically suspicious, consider CEM.

Nipple Inversion/Retraction without Palpable Mass

Age-appropriate evaluation of a palpable symptom during pregnancy or lactation should proceed similar to that for individuals who are not pregnant or lactating (see *Nipple Inversion/Retraction without Palpable Mass* in the algorithm). If mammographic and/or ultrasound imaging is negative and findings are clinically suspicious, consider CEM. Breast MRI is not contraindicated for the management of nipple inversion/retraction without palpable mass during lactation if clinically indicated.

Nipple Discharge, No Palpable Symptom

Because of the frequency of normal nipple discharge during pregnancy and lactation, the NCCN Panel defines abnormal nipple discharge as spontaneous, uniductal, unilateral bloody or clear nipple discharge that is persistent and reproducible on exam. Due to normal physiologic changes of pregnancy and lactation, bloody nipple discharge is common, but usually short-lived.[267,268] Persistence beyond one or two episodes should undergo evaluation. Spontaneous multi-duct discharge that is milky may be due to pregnancy, and if not, should be evaluated for galactorrhea. Greenish, coffee-colored, yellow, brown/black multi-duct discharge is nearly always non-neoplastic, and reassurance can be provided. However, if the discharge is bothersome to the patient, referral to a breast specialist may be considered. Age-appropriate evaluation of abnormal nipple discharge during lactation should proceed similar to that for individuals who are not pregnant or lactating (See *Nipple Discharge, No Palpable Symptom* in the algorithm). If mammographic and/or ultrasound imaging is negative and findings are clinically suspicious, consider CEM. Breast MRI is not contraindicated for the management of abnormal nipple discharge during lactation if clinically indicated. If there is persistent bloody nipple discharge without abnormal breast imaging, a breast surgical expert should be consulted to discuss possible further diagnostic testing (eg, duct excision).

Suspicious Skin Changes

Individuals who are pregnant with suspicious skin changes should undergo age-appropriate breast imaging evaluation similar to that for individuals who are not pregnant or lactating, with diagnostic mammogram with tomosynthesis with or without ultrasound (see *Skin Changes* in the algorithm). If mammographic and/or ultrasound imaging is negative and findings are clinically suspicious, consider CEM or skin punch biopsy.

Suspicious skin changes in individuals who are lactating may be due to puerperal mastitis. If symptoms are clinically consistent with mastitis, appropriate treatment should proceed, including the use of antimicrobials. Mastitis that does not improve with usual treatment should result in both clinical and imaging evaluation for alternative etiologies (eg, breast abscess, breast cancer). Breast imaging is nearly always indicated to assist in the diagnosis of persistent breast skin changes that have not responded to usual treatment for mastitis. In this circumstance, age-appropriate evaluation should proceed similar to that for individuals who are not lactating (see *Skin Changes* in the algorithm).

Breast ultrasound is particularly useful in diagnosing breast abscess and may be the appropriate first imaging modality. If breast abscess is found, drainage is usually indicated and provides a definitive diagnosis.

Persistent or Severe Focal Breast Pain

While breast pain is common due to the physiologic changes of pregnancy and lactation and is considered normal, individuals with focal persistent breast pain (defined as lasting 4–6 weeks in duration) should undergo age-appropriate evaluation as outlined for those who are not pregnant or lactating (see *Persistent or Severe Breast Pain* in the algorithm). If mammographic and/or ultrasound imaging is negative and findings are

Version 1.2026 © 2026 National Comprehensive Cancer Network© (NCCN©), All rights reserved. NCCN Guidelines® and this illustration may not be reproduced in any form without the express written permission of NCCN.

PLEASE NOTE that use of this NCCN Content is governed by the End-User License Agreement, and you MAY NOT distribute this Content or use it with any artificial intelligence model or tool.
Printed by Ambrish Chauhan on 5/1/2026 7:03:18 AM. Copyright © 2026 National Comprehensive Cancer Network, Inc. All Rights Reserved.

clinically suspicious, consider CEM or palpable biopsy. While breast MRI is not contraindicated for the management of persistent, focal breast pain during lactation, it is usually not indicated.

Axillary Mass(es) Suspected to Represent Adenopathy

The development of an axillary mass during pregnancy may be due to normal breast enlargement that occurs during pregnancy or lactation in accessory axillary breast tissue that is present in ~15% of individuals. It is also not uncommon for this to be asymmetric. The development of an axillary mass within the first 2 weeks following delivery is clinically consistent with lactational changes due to the presence of axillary breast tissue.

If after clinical examination there remains concern that the physical findings are not due to normal axillary breast tissue that has enlarged due to pregnancy, providers should proceed with evaluation as outlined for individuals who are not pregnant or lactating (See *Axillary Mass* in the algorithm). If suspicious axillary lymph nodes are identified, mammography is recommended.

BI-RADS Category Imaging Follow-up

Pregnancy or lactation should not change the management of follow-up of a BI-RADS 3 imaging finding, and appropriate follow-up imaging and/or examination should proceed as outlined for individuals who are not pregnant or lactating (see *Mammographic and/or Ultrasound Evaluation and Follow-up* in the algorithm). In the case of a BI-RADS 3 finding on MRI without associated ultrasound or mammography findings in an individual who is pregnant, a breast expert should be consulted to assist with counseling regarding follow-up and management recommendations (eg, defer to after pregnancy).

Because it is rare to develop a milk fistula after core needle biopsy,[269] image-guided core needle biopsy should proceed in the usual prompt timeframe following a BI-RADS 4 or BI-RADS 5 imaging result during pregnancy or lactation.

Summary

The intent of the NCCN Guidelines for Breast Cancer Screening and Diagnosis is to give clinicians a practical, consistent framework for screening and evaluating a spectrum of clinical breast presentations. Clinical judgment should always be an important component of the optimal management of the patient.

Version 1.2026 © 2026 National Comprehensive Cancer Network© (NCCN©), All rights reserved. NCCN Guidelines® and this illustration may not be reproduced in any form without the express written permission of NCCN.

PLEASE NOTE that use of this NCCN Content is governed by the End-User License Agreement, and you MAY NOT distribute this Content or use it with any artificial intelligence model or tool.
Printed by Ambrish Chauhan on 5/1/2026 7:03:18 AM. Copyright © 2026 National Comprehensive Cancer Network, Inc. All Rights Reserved.

Table 1: Breast Cysts - Types and Definitions	
Simple	Anechoic (cystic), well-circumscribed, round, or oval with well-defined imperceptible wall and posterior enhancement.
Complicated	Has most but not all elements of a simple cyst. Complicated cysts do not contain solid elements, intracystic masses, thick walls, or thick septa. This type of cyst may contain low-level echoes or intracystic debris, and can be described as a round, circumscribed mass containing low-level echoes without vascular flow, fulfilling most but not all criteria of a simple cyst.
Complex	Has some discrete solid component, which may include thick walls, thick septa, and/or intracystic mass. Complex cysts have both anechoic (cystic) and echogenic (solid) components.
References	181,192,210,212-215,270

Version 1.2026 © 2026 National Comprehensive Cancer Network© (NCCN©), All rights reserved. NCCN Guidelines© and this illustration may not be reproduced in any form without the express written permission of NCCN.

PLEASE NOTE that use of this NCCN Content is governed by the End-User License Agreement, and you MAY NOT distribute this Content or use it with any artificial intelligence model or tool.
Printed by Ambrish Chauhan on 5/1/2026 7:03:18 AM. Copyright © 2026 National Comprehensive Cancer Network, Inc. All Rights Reserved.

References

1. American Cancer Society. Breast Cancer Facts and Figures 2009-2010. Atlanta: American Cancer Society, Inc. Available at: https://www.cancer.org/content/dam/cancer-org/research/cancer-facts-and-statistics/breast-cancer-facts-and-figures/breast-cancer-facts-and-figures-2009-2010.pdf.

2. Siegel RL, Kratzer TB, Wagle NS, et al. Cancer statistics, 2026. CA Cancer J Clin 2026;76:e70043. Available at: https://www.ncbi.nlm.nih.gov/pubmed/41528114.

3. Giaquinto AN, Sung H, Miller KD, et al. Breast cancer statistics, 2022. CA Cancer J Clin 2022;72:524–541. Available at: https://www.ncbi.nlm.nih.gov/pubmed/36190501.

4. Humphrey LL, Helfand M, Chan BK, Woolf SH. Breast cancer screening: a summary of the evidence for the U.S. Preventive Services Task Force. Ann Intern Med 2002;137:347–360. Available at: http://www.ncbi.nlm.nih.gov/pubmed/12204020.

5. PubMed overview. Available at: https://pubmed.ncbi.nlm.nih.gov/about/. Accessed April 10, 2023.

6. Expert Panel on Breast I, Brown A, Lourenco AP, et al. ACR Appropriateness Criteria(R) transgender breast cancer screening. J Am Coll Radiol 2021;18:S502–S515. Available at: https://www.ncbi.nlm.nih.gov/pubmed/34794604.

7. Barton MB, Harris R, Fletcher SW. The rational clinical examination. Does this patient have breast cancer? The screening clinical breast examination: should it be done? How? JAMA 1999;282:1270–1280. Available at: http://www.ncbi.nlm.nih.gov/pubmed/10517431.

8. Mittra I, Mishra GA, Dikshit RP, et al. Effect of screening by clinical breast examination on breast cancer incidence and mortality after 20 years: prospective, cluster randomised controlled trial in Mumbai. BMJ 2021;372:n256. Available at: https://www.ncbi.nlm.nih.gov/pubmed/33627312.

9. Bevers TB. Breast awareness: a shift in the paradigm of breast self-examination. J Natl Compr Canc Netw 2009;7:1042–1043. Available at: http://www.ncbi.nlm.nih.gov/pubmed/19930973.

10. Bevers T. Breast Self-examination. In: Singletary SE, Robb GL, Hortobagyi GN, eds. Advanced Therapy of Breast Disease. 2nd ed. New York: B.C. Decker, Inc; 2004.

11. Thomas DB, Gao DL, Ray RM, et al. Randomized trial of breast self-examination in Shanghai: final results. J Natl Cancer Inst 2002;94:1445–1457. Available at: http://www.ncbi.nlm.nih.gov/pubmed/12359854.

12. Parmigiani G, Berry D, Aguilar O. Determining carrier probabilities for breast cancer-susceptibility genes BRCA1 and BRCA2. Am J Hum Genet 1998;62:145–158. Available at: https://www.ncbi.nlm.nih.gov/pubmed/9443863.

13. Tyrer J, Duffy SW, Cuzick J. A breast cancer prediction model incorporating familial and personal risk factors. Stat Med 2004;23:1111–1130. Available at: https://www.ncbi.nlm.nih.gov/pubmed/15057881.

14. Antoniou AC, Cunningham AP, Peto J, et al. The BOADICEA model of genetic susceptibility to breast and ovarian cancers: updates and extensions. Br J Cancer 2008;98:1457–1466. Available at: https://www.ncbi.nlm.nih.gov/pubmed/18349832.

15. Breast Cancer Surveillance Consortium (BCSC) Invasive Breast Cancer Risk Calculator. Available at: https://tools.bcsc-scc.ucdavis.edu/BC5yearRisk/#/. Accessed March 25, 2025.

16. Dr. Kate Hendricks Thomas supporting expanded review for Veterans in Combat Environments Act 2022. Available at: https://www.congress.gov/117/plaws/publ133/PLAW-117publ133.pdf.

17. Feig SA, Yaffe MJ. Digital mammography. Radiographics 1998;18:893–901. Available at: https://www.ncbi.nlm.nih.gov/pubmed/9672974.

Version 1.2026 © 2026 National Comprehensive Cancer Network© (NCCN©), All rights reserved. NCCN Guidelines® and this illustration may not be reproduced in any form without the express written permission of NCCN.

PLEASE NOTE that use of this NCCN Content is governed by the End-User License Agreement, and you MAY NOT distribute this Content or use it with any artificial intelligence model or tool.
Printed by Ambrish Chauhan on 5/1/2026 7:03:18 AM. Copyright © 2026 National Comprehensive Cancer Network, Inc. All Rights Reserved.

18. Pisano ED, Yaffe MJ, Hemminger BM, et al. Current status of full-field digital mammography. Acad Radiol 2000;7:266–280. Available at: https://www.ncbi.nlm.nih.gov/pubmed/10766101.

19. Pisano ED, Gatsonis C, Hendrick E, et al. Diagnostic performance of digital versus film mammography for breast-cancer screening. N Engl J Med 2005;353:1773–1783. Available at: http://www.ncbi.nlm.nih.gov/pubmed/16169887.

20. Pisano ED, Hendrick RE, Yaffe MJ, et al. Diagnostic accuracy of digital versus film mammography: exploratory analysis of selected population subgroups in DMIST. Radiology 2008;246:376–383. Available at: http://www.ncbi.nlm.nih.gov/pubmed/18227537.

21. Skaane P, Hofvind S, Skjennald A. Randomized trial of screen-film versus full-field digital mammography with soft-copy reading in population-based screening program: follow-up and final results of Oslo II study. Radiology 2007;244:708–717. Available at: http://www.ncbi.nlm.nih.gov/pubmed/17709826.

22. Ciatto S, Houssami N, Bernardi D, et al. Integration of 3D digital mammography with tomosynthesis for population breast-cancer screening (STORM): a prospective comparison study. Lancet Oncol 2013;14:583–589. Available at: https://www.ncbi.nlm.nih.gov/pubmed/23623721.

23. Skaane P, Bandos AI, Gullien R, et al. Comparison of digital mammography alone and digital mammography plus tomosynthesis in a population-based screening program. Radiology 2013;267:47–56. Available at: https://www.ncbi.nlm.nih.gov/pubmed/23297332.

24. Rafferty EA, Park JM, Philpotts LE, et al. Assessing radiologist performance using combined digital mammography and breast tomosynthesis compared with digital mammography alone: results of a multicenter, multireader trial. Radiology 2013;266:104–113. Available at: https://www.ncbi.nlm.nih.gov/pubmed/23169790.

25. Friedewald SM, Rafferty EA, Rose SL, et al. Breast cancer screening using tomosynthesis in combination with digital mammography. JAMA 2014;311:2499–2507. Available at: https://www.ncbi.nlm.nih.gov/pubmed/25058084.

26. Lourenco AP, Barry-Brooks M, Baird GL, et al. Changes in recall type and patient treatment following implementation of screening digital breast tomosynthesis. Radiology 2015;274:337–342. Available at: https://www.ncbi.nlm.nih.gov/pubmed/25247407.

27. Rose SL, Tidwell AL, Ice MF, et al. A reader study comparing prospective tomosynthesis interpretations with retrospective readings of the corresponding FFDM examinations. Acad Radiol 2014;21:1204–1210. Available at: https://www.ncbi.nlm.nih.gov/pubmed/25107868.

28. Destounis S, Arieno A, Morgan R. Initial experience with combination digital breast tomosynthesis plus full field digital mammography or full field digital mammography alone in the screening environment. J Clin Imaging Sci 2014;4:9. Available at: https://www.ncbi.nlm.nih.gov/pubmed/24744966.

29. Margolies L, Cohen A, Sonnenblick E, et al. Digital breast tomosynthesis changes management in patients seen at a tertiary care breast center. ISRN Radiol 2014;2014:658929. Available at: https://www.ncbi.nlm.nih.gov/pubmed/24967297.

30. Lang K, Andersson I, Rosso A, et al. Performance of one-view breast tomosynthesis as a stand-alone breast cancer screening modality: results from the Malmo Breast Tomosynthesis Screening Trial, a population-based study. Eur Radiol 2016;26:184–190. Available at: https://www.ncbi.nlm.nih.gov/pubmed/25929946.

31. Gilbert FJ, Tucker L, Gillan MG, et al. Accuracy of digital breast tomosynthesis for depicting breast cancer subgroups in a UK retrospective reading study (TOMMY Trial). . Radiology 2015;277:697–706. Available at: https://www.ncbi.nlm.nih.gov/pubmed/26176654.

32. Marinovich ML, Hunter KE, Macaskill P, Houssami N. Breast cancer screening using tomosynthesis or mammography: A meta-analysis of cancer detection and recall. J Natl Cancer Inst 2018;110:942–949. Available at: https://www.ncbi.nlm.nih.gov/pubmed/30107542.

Version 1.2026 © 2026 National Comprehensive Cancer Network© (NCCN©), All rights reserved. NCCN Guidelines® and this illustration may not be reproduced in any form without the express written permission of NCCN.

PLEASE NOTE that use of this NCCN Content is governed by the End-User License Agreement, and you MAY NOT distribute this Content or use it with any artificial intelligence model or tool.
Printed by Ambrish Chauhan on 5/1/2026 7:03:18 AM. Copyright © 2026 National Comprehensive Cancer Network, Inc. All Rights Reserved.

33. Heindel W, Weigel S, Gerss J, et al. Digital breast tomosynthesis plus synthesised mammography versus digital screening mammography for the detection of invasive breast cancer (TOSYMA): a multicentre, open-label, randomised, controlled, superiority trial. Lancet Oncol 2022;23:601–611. Available at: https://www.ncbi.nlm.nih.gov/pubmed/35427470.

34. Pattacini P, Nitrosi A, Giorgi Rossi P, et al. A randomized trial comparing breast cancer incidence and interval cancers after tomosynthesis plus mammography versus mammography alone. Radiology 2022;303:256–266. Available at: https://www.ncbi.nlm.nih.gov/pubmed/35103537.

35. Moshina N, Aase HS, Danielsen AS, et al. Comparing screening outcomes for digital breast tomosynthesis and digital mammography by automated breast density in a randomized controlled trial: Results from the to-be trial. Radiology 2020;297:522–531. Available at: https://www.ncbi.nlm.nih.gov/pubmed/32930649.

36. Conant EF, Barlow WE, Herschorn SD, et al. Association of digital breast tomosynthesis vs digital mammography with cancer detection and recall rates by age and breast density. JAMA Oncol 2019;5:635–642. Available at: https://www.ncbi.nlm.nih.gov/pubmed/30816931.

37. Zuckerman SP, Conant EF, Keller BM, et al. Implementation of synthesized two-dimensional mammography in a population-based digital breast tomosynthesis screening program. Radiology 2016;281:730–736. Available at: https://www.ncbi.nlm.nih.gov/pubmed/27467468.

38. Skaane P, Bandos AI, Eben EB, et al. Two-view digital breast tomosynthesis screening with synthetically reconstructed projection images: comparison with digital breast tomosynthesis with full-field digital mammographic images. Radiology 2014;271:655–663. Available at: https://www.ncbi.nlm.nih.gov/pubmed/24484063.

39. Abdullah P, Alabousi M, Ramadan S, et al. Synthetic 2D mammography versus standard 2D digital mammography: A diagnostic test accuracy systematic review and meta-analysis. AJR Am J Roentgenol 2021;217:314–325. Available at: https://www.ncbi.nlm.nih.gov/pubmed/32966115.

40. Berg WA, Blume JD, Cormack JB, et al. Combined screening with ultrasound and mammography vs mammography alone in women at elevated risk of breast cancer. JAMA 2008;299:2151–2163. Available at: http://www.ncbi.nlm.nih.gov/pubmed/18477782.

41. Berg WA, Zhang Z, Lehrer D, et al. Detection of breast cancer with addition of annual screening ultrasound or a single screening MRI to mammography in women with elevated breast cancer risk. JAMA 2012;307:1394–1404. Available at: https://www.ncbi.nlm.nih.gov/pubmed/22474203.

42. Berg WA, Bandos AI, Mendelson EB, et al. Ultrasound as the primary screening test for breast cancer: Analysis from ACRIN 6666. J Natl Cancer Inst 2016;108. Available at: https://www.ncbi.nlm.nih.gov/pubmed/26712110.

43. Weigert J, Steenbergen S. The connecticut experiments second year: ultrasound in the screening of women with dense breasts. Breast J 2015;21:175–180. Available at: https://www.ncbi.nlm.nih.gov/pubmed/25683369.

44. Bevers TB. Ultrasound for the screening of breast cancer. Curr Oncol Rep 2008;10:527–528. Available at: http://www.ncbi.nlm.nih.gov/pubmed/18928668.

45. Hooley RJ, Greenberg KL, Stackhouse RM, et al. Screening US in patients with mammographically dense breasts: initial experience with Connecticut Public Act 09-41. Radiology 2012;265:59–69. Available at: https://www.ncbi.nlm.nih.gov/pubmed/22723501.

46. Scheel JR, Lee JM, Sprague BL, et al. Screening ultrasound as an adjunct to mammography in women with mammographically dense breasts. Am J Obstet Gynecol 2015;212:9–17. Available at: https://www.ncbi.nlm.nih.gov/pubmed/24959654.

Version 1.2026 © 2026 National Comprehensive Cancer Network© (NCCN©), All rights reserved. NCCN Guidelines® and this illustration may not be reproduced in any form without the express written permission of NCCN.

PLEASE NOTE that use of this NCCN Content is governed by the End-User License Agreement, and you MAY NOT distribute this Content or use it with any artificial intelligence model or tool.
Printed by Ambrish Chauhan on 5/1/2026 7:03:18 AM. Copyright © 2026 National Comprehensive Cancer Network, Inc. All Rights Reserved.

47. Gilbert FJ, Payne NR, Allajbeu I, et al. Comparison of supplemental breast cancer imaging techniques-interim results from the BRAID randomised controlled trial. Lancet 2025;405:1935–1944. Available at: https://www.ncbi.nlm.nih.gov/pubmed/40412427.

48. Lord SJ, Lei W, Craft P, et al. A systematic review of the effectiveness of magnetic resonance imaging (MRI) as an addition to mammography and ultrasound in screening young women at high risk of breast cancer. Eur J Cancer 2007;43:1905–1917. Available at: http://www.ncbi.nlm.nih.gov/pubmed/17681781.

49. Mann RM, Kuhl CK, Kinkel K, Boetes C. Breast MRI: guidelines from the European Society of Breast Imaging. Eur Radiol 2008;18:1307–1318. Available at: http://www.ncbi.nlm.nih.gov/pubmed/18389253.

50. Schnall M, Orel S. Breast MR imaging in the diagnostic setting. Magn Reson Imaging Clin N Am 2006;14:329–337, vi. Available at: http://www.ncbi.nlm.nih.gov/pubmed/17098174.

51. Ng AK, Garber JE, Diller LR, et al. Prospective study of the efficacy of breast magnetic resonance imaging and mammographic screening in survivors of Hodgkin lymphoma. J Clin Oncol 2013;31:2282–2288. Available at: https://www.ncbi.nlm.nih.gov/pubmed/23610104.

52. Kuhl CK, Schrading S, Leutner CC, et al. Mammography, breast ultrasound, and magnetic resonance imaging for surveillance of women at high familial risk for breast cancer. J Clin Oncol 2005;23:8469–8476. Available at: http://www.ncbi.nlm.nih.gov/pubmed/16293877.

53. Kriege M, Brekelmans CTM, Boetes C, et al. Differences between first and subsequent rounds of the MRISC breast cancer screening program for women with a familial or genetic predisposition. Cancer 2006;106:2318–2326. Available at: http://www.ncbi.nlm.nih.gov/pubmed/16615112.

54. Kriege M, Brekelmans CTM, Obdeijn IM, et al. Factors affecting sensitivity and specificity of screening mammography and MRI in women with an inherited risk for breast cancer. Breast Cancer Res Treat 2006;100:109–119. Available at: http://www.ncbi.nlm.nih.gov/pubmed/16791481.

55. Robson ME, Offit K. Breast MRI for women with hereditary cancer risk. JAMA 2004;292:1368–1370. Available at: http://www.ncbi.nlm.nih.gov/pubmed/15367560.

56. Warner E. The role of magnetic resonance imaging in screening women at high risk of breast cancer. Top Magn Reson Imaging 2008;19:163–169. Available at: http://www.ncbi.nlm.nih.gov/pubmed/18941396.

57. Warner E, Messersmith H, Causer P, et al. Systematic review: using magnetic resonance imaging to screen women at high risk for breast cancer. Ann Intern Med 2008;148:671–679. Available at: http://www.ncbi.nlm.nih.gov/pubmed/18458280.

58. Warner E, Plewes DB, Hill KA, et al. Surveillance of BRCA1 and BRCA2 mutation carriers with magnetic resonance imaging, ultrasound, mammography, and clinical breast examination. JAMA 2004;292:1317–1325. Available at: http://www.ncbi.nlm.nih.gov/pubmed/15367553.

59. Lehman CD, Smith RA. The role of MRI in breast cancer screening. J Natl Compr Canc Netw 2009;7:1109–1115. Available at: http://www.ncbi.nlm.nih.gov/pubmed/19930977.

60. Saslow D, Boetes C, Burke W, et al. American Cancer Society guidelines for breast screening with MRI as an adjunct to mammography. CA Cancer J Clin 2007;57:75–89. Available at: http://www.ncbi.nlm.nih.gov/pubmed/17392385.

61. Leach MO, Boggis CR, Dixon AK, et al. Screening with magnetic resonance imaging and mammography of a UK population at high familial risk of breast cancer: a prospective multicentre cohort study (MARIBS). Lancet 2005;365:1769–1778. Available at: http://www.ncbi.nlm.nih.gov/pubmed/15910949.

62. Port ER, Park A, Borgen PI, et al. Results of MRI screening for breast cancer in high-risk patients with LCIS and atypical hyperplasia.

Version 1.2026 © 2026 National Comprehensive Cancer Network© (NCCN©), All rights reserved. NCCN Guidelines® and this illustration may not be reproduced in any form without the express written permission of NCCN.

PLEASE NOTE that use of this NCCN Content is governed by the End-User License Agreement, and you MAY NOT distribute this Content or use it with any artificial intelligence model or tool.
Printed by Ambrish Chauhan on 5/1/2026 7:03:18 AM. Copyright © 2026 National Comprehensive Cancer Network, Inc. All Rights Reserved.

Ann Surg Oncol 2007;14:1051–1057. Available at: http://www.ncbi.nlm.nih.gov/pubmed/17206485.

63. Xia D, Davis RL, Crawford JA, Abraham JL. Gadolinium released from MR contrast agents is deposited in brain tumors: in situ demonstration using scanning electron microscopy with energy dispersive X-ray spectroscopy. Acta Radiol 2010;51:1126–1136. Available at: https://www.ncbi.nlm.nih.gov/pubmed/20868305.

64. Ramalho J, Ramalho M, Jay M, et al. Gadolinium toxicity and treatment. Magn Reson Imaging 2016;34:1394–1398. Available at: https://www.ncbi.nlm.nih.gov/pubmed/27693607.

65. Stojanov D, Aracki-Trenkic A, Benedeto-Stojanov D. Gadolinium deposition within the dentate nucleus and globus pallidus after repeated administrations of gadolinium-based contrast agents-current status. Neuroradiology 2016;58:433–441. Available at: https://www.ncbi.nlm.nih.gov/pubmed/26873830.

66. McDonald RJ, McDonald JS, Kallmes DF, et al. Gadolinium deposition in human brain tissues after contrast-enhanced MR imaging in adult patients without intracranial abnormalities. Radiology 2017;285:546–554. Available at: https://www.ncbi.nlm.nih.gov/pubmed/28653860.

67. Darrah TH, Prutsman-Pfeiffer JJ, Poreda RJ, et al. Incorporation of excess gadolinium into human bone from medical contrast agents. Metallomics 2009;1:479–488. Available at: https://www.ncbi.nlm.nih.gov/pubmed/21305156.

68. Lord ML, Chettle DR, Grafe JL, et al. Observed deposition of gadolinium in bone using a new noninvasive in vivo biomedical device: Results of a small pilot feasibility study. Radiology 2018;287:96–103. Available at: https://www.ncbi.nlm.nih.gov/pubmed/29237148.

69. FDA Drug Safety Communication: FDA warns that gadolinium-based contrast agents (GBCAs) are retained in the body; requires new class warnings. 2022. Available at: https://www.fda.gov/drugs/drug-safety-and-availability/fda-drug-safety-communication-fda-warns-gadolinium-based-contrast-agents-gbcas-are-retained-body. Accessed September 26, 2025.

70. Comstock CE, Gatsonis C, Newstead GM, et al. Comparison of abbreviated breast MRI vs digital breast tomosynthesis for breast cancer detection among women with dense breasts undergoing screening. JAMA 2020;323:746–756. Available at: https://www.ncbi.nlm.nih.gov/pubmed/32096852.

71. Baxter GC, Selamoglu A, Mackay JW, et al. A meta-analysis comparing the diagnostic performance of abbreviated MRI and a full diagnostic protocol in breast cancer. Clin Radiol 2021;76:154 e123–154 e132. Available at: https://www.ncbi.nlm.nih.gov/pubmed/33032820.

72. Geach R, Jones LI, Harding SA, et al. The potential utility of abbreviated breast MRI (FAST MRI) as a tool for breast cancer screening: a systematic review and meta-analysis. Clin Radiol 2021;76:154 e111–154 e122. Available at: https://www.ncbi.nlm.nih.gov/pubmed/33010932.

73. ACR practice parameter for the performance of contrast-enhanced magnetic resonance imaging (MRI) of the breast 2023. Available at: https://www.acr.org/-/media/ACR/Files/Practice-Parameters/MR-Contrast-Breast.pdf.

74. Jochelson M. Contrast-enhanced digital mammography. Radiol Clin North Am 2014;52:609–616. Available at: https://www.ncbi.nlm.nih.gov/pubmed/24792660.

75. Berg WA, Vargo A, Lu AH, et al. Screening for Breast Cancer with Contrast-enhanced Mammography as an Alternative to MRI: SCEMAM Trial Results. Radiology 2025;315:e242634. Available at: https://www.ncbi.nlm.nih.gov/pubmed/40525975.

76. Zanardo M, Cozzi A, Trimboli RM, et al. Technique, protocols and adverse reactions for contrast-enhanced spectral mammography (CESM): a systematic review. Insights Imaging 2019;10:76. Available at: https://www.ncbi.nlm.nih.gov/pubmed/31376021.

Version 1.2026 © 2026 National Comprehensive Cancer Network© (NCCN©), All rights reserved. NCCN Guidelines® and this illustration may not be reproduced in any form without the express written permission of NCCN.

PLEASE NOTE that use of this NCCN Content is governed by the End-User License Agreement, and you MAY NOT distribute this Content or use it with any artificial intelligence model or tool.
Printed by Ambrish Chauhan on 5/1/2026 7:03:18 AM. Copyright © 2026 National Comprehensive Cancer Network, Inc. All Rights Reserved.

77. Gennaro G, Cozzi A, Schiaffino S, et al. Radiation dose of contrast-enhanced mammography: A two-center prospective comparison. Cancers (Basel) 2022;14:1774. Available at: https://www.ncbi.nlm.nih.gov/pubmed/35406546.

78. Hruska CB. Molecular breast imaging for screening in dense breasts: state of the art and future directions. AJR Am J Roentgenol 2017;208:275–283. Available at: https://www.ncbi.nlm.nih.gov/pubmed/27762607.

79. Shermis RB, Wilson KD, Doyle MT, et al. Supplemental breast cancer screening with molecular breast imaging for women with dense breast tissue. AJR Am J Roentgenol 2016;207:450–457. Available at: https://www.ncbi.nlm.nih.gov/pubmed/27186635.

80. Meissnitzer T, Seymer A, Keinrath P, et al. Added value of semi-quantitative breast-specific gamma imaging in the work-up of suspicious breast lesions compared to mammography, ultrasound and 3-T MRI. Br J Radiol 2015;88:20150147. Available at: https://www.ncbi.nlm.nih.gov/pubmed/25882690.

81. Covington MF, Parent EE, Dibble EH, et al. Advances and future directions in molecular breast imaging. J Nucl Med 2022;63:17–21. Available at: https://www.ncbi.nlm.nih.gov/pubmed/34887334.

82. U.S. Food and Drug Administration (FDA) safety alert on ductal lavage. Available at: http://www.breastcancer.org/research-news/20140220

83. Oeffinger KC, Fontham ET, Etzioni R, et al. Breast cancer screening for women at average risk: 2015 guideline update from the American Cancer Society. JAMA 2015;314:1599–1614. Available at: http://www.ncbi.nlm.nih.gov/pubmed/26501536.

84. Siu AL, Force USPST. Screening for breast cancer: U.S. Preventive Services Task Force recommendation statement. Ann Intern Med 2016;164:279–296. Available at: https://www.ncbi.nlm.nih.gov/pubmed/26757170.

85. U.S. Preventive Services Task Force Draft Recommendation Statement. Breast Cancer: Screening. 2023. Available at: https://www.uspreventiveservicestaskforce.org/uspstf/draft-recommendation/breast-cancer-screening-adults#fullrecommendationstart. Accessed August 2, 2023.

86. Force USPST, Nicholson WK, Silverstein M, et al. Screening for breast cancer: US Preventive Services Task Force recommendation statement. JAMA 2024;331:1918–1930. Available at: https://www.ncbi.nlm.nih.gov/pubmed/38687503.

87. Myers ER, Moorman P, Gierisch JM, et al. Benefits and harms of breast cancer screening: A systematic review. JAMA 2015;314:1615–1634. Available at: https://www.ncbi.nlm.nih.gov/pubmed/26501537.

88. Moss SM, Cuckle H, Evans A, et al. Effect of mammographic screening from age 40 years on breast cancer mortality at 10 years' follow-up: a randomised controlled trial. Lancet 2006;368:2053–2060. Available at: http://www.ncbi.nlm.nih.gov/pubmed/17161727.

89. Moss SM, Wale C, Smith R, et al. Effect of mammographic screening from age 40 years on breast cancer mortality in the UK Age trial at 17 years' follow-up: a randomised controlled trial. Lancet Oncol 2015;16:1123–1132. Available at: http://www.ncbi.nlm.nih.gov/pubmed/26206144.

90. Hellquist BN, Duffy SW, Abdsaleh S, et al. Effectiveness of population-based service screening with mammography for women ages 40 to 49 years: evaluation of the Swedish Mammography Screening in Young Women (SCRY) cohort. Cancer 2011;117:714–722. Available at: https://www.ncbi.nlm.nih.gov/pubmed/20882563.

91. Swedish Organised Service Screening Evaluation G. Reduction in breast cancer mortality from organized service screening with mammography: 1. Further confirmation with extended data. Cancer Epidemiol Biomarkers Prev 2006;15:45–51. Available at: https://www.ncbi.nlm.nih.gov/pubmed/16434585.

Version 1.2026 © 2026 National Comprehensive Cancer Network© (NCCN©), All rights reserved. NCCN Guidelines® and this illustration may not be reproduced in any form without the express written permission of NCCN.

PLEASE NOTE that use of this NCCN Content is governed by the End-User License Agreement, and you MAY NOT distribute this Content or use it with any artificial intelligence model or tool.
Printed by Ambrish Chauhan on 5/1/2026 7:03:18 AM. Copyright © 2026 National Comprehensive Cancer Network, Inc. All Rights Reserved.

92. Coldman A, Phillips N, Wilson C, et al. Pan-Canadian study of mammography screening and mortality from breast cancer. J Natl Cancer Inst 2014;106. Available at: https://www.ncbi.nlm.nih.gov/pubmed/25274578.

93. Broeders M, Moss S, Nystrom L, et al. The impact of mammographic screening on breast cancer mortality in Europe: a review of observational studies. J Med Screen 2012;19 Suppl 1:14–25. Available at: https://www.ncbi.nlm.nih.gov/pubmed/22972807.

94. Malmgren JA, Parikh J, Atwood MK, Kaplan HG. Impact of mammography detection on the course of breast cancer in women aged 40-49 years. Radiology 2012;262:797–806. Available at: http://www.ncbi.nlm.nih.gov/pubmed/22357883.

95. Saadatmand S, Bretveld R, Siesling S, Tilanus-Linthorst MM. Influence of tumour stage at breast cancer detection on survival in modern times: population based study in 173,797 patients. BMJ 2015;351:h4901. Available at: https://www.ncbi.nlm.nih.gov/pubmed/26442924.

96. Mandelblatt JS, Cronin KA, Bailey S, et al. Effects of mammography screening under different screening schedules: model estimates of potential benefits and harms. Ann Intern Med 2009;151:738–747. Available at: http://www.ncbi.nlm.nih.gov/pubmed/19920274.

97. Modeling Report: Collaborative Modeling of U.S. Breast Cancer Screening Strategies: Breast Cancer: Screening. U.S. Preventive Services Task Force. April 2015. Available at: http://www.uspreventiveservicestaskforce.org/Page/Document/modeling-report-collaborative-modeling-of-us-breast-cancer-1/breast-cancer-screening1.

98. Practice bulletin no. 122: Breast cancer screening. Obstet Gynecol 2011;118:372–382. Available at: https://www.ncbi.nlm.nih.gov/pubmed/21775869.

99. Schwartz LM, Woloshin S, Sox HC, et al. US women's attitudes to false positive mammography results and detection of ductal carcinoma in situ: cross sectional survey. BMJ 2000;320:1635–1640. Available at: https://www.ncbi.nlm.nih.gov/pubmed/10856064.

100. Coldman AJ, Phillips N, Speers C. A retrospective study of the effect of participation in screening mammography on the use of chemotherapy and breast conserving surgery. Int J Cancer 2007;120:2185–2190. Available at: http://www.ncbi.nlm.nih.gov/pubmed/17290404.

101. Tosteson AN, Fryback DG, Hammond CS, et al. Consequences of false-positive screening mammograms. JAMA Intern Med 2014;174:954–961. Available at: https://www.ncbi.nlm.nih.gov/pubmed/24756610.

102. Yen AM, Duffy SW, Chen TH, et al. Long-term incidence of breast cancer by trial arm in one county of the Swedish Two-County Trial of mammographic screening. Cancer 2012;118:5728–5732. Available at: https://www.ncbi.nlm.nih.gov/pubmed/22605639.

103. Bleyer A, Welch HG. Effect of three decades of screening mammography on breast-cancer incidence. N Engl J Med 2012;367:1998–2005. Available at: http://www.ncbi.nlm.nih.gov/pubmed/23171096.

104. Puliti D, Duffy SW, Miccinesi G, et al. Overdiagnosis in mammographic screening for breast cancer in Europe: a literature review. J Med Screen 2012;19 Suppl 1:42–56. Available at: https://www.ncbi.nlm.nih.gov/pubmed/22972810.

105. Zackrisson S, Andersson I, Janzon L, et al. Rate of over-diagnosis of breast cancer 15 years after end of Malmo mammographic screening trial: follow-up study. BMJ 2006;332:689–692. Available at: https://www.ncbi.nlm.nih.gov/pubmed/16517548.

106. Miller AB, To T, Baines CJ, Wall C. Canadian National Breast Screening Study-2: 13-year results of a randomized trial in women aged 50-59 years. J Natl Cancer Inst 2000;92:1490–1499. Available at: https://www.ncbi.nlm.nih.gov/pubmed/10995804.

Version 1.2026 © 2026 National Comprehensive Cancer Network© (NCCN©), All rights reserved. NCCN Guidelines® and this illustration may not be reproduced in any form without the express written permission of NCCN.

PLEASE NOTE that use of this NCCN Content is governed by the End-User License Agreement, and you MAY NOT distribute this Content or use it with any artificial intelligence model or tool.
Printed by Ambrish Chauhan on 5/1/2026 7:03:18 AM. Copyright © 2026 National Comprehensive Cancer Network, Inc. All Rights Reserved.

107. Miller AB, To T, Baines CJ, Wall C. The Canadian National Breast Screening Study-1: breast cancer mortality after 11 to 16 years of follow-up. A randomized screening trial of mammography in women age 40 to 49 years. Ann Intern Med 2002;137:305–312. Available at: https://www.ncbi.nlm.nih.gov/pubmed/12204013.

108. Marmot MG, Altman DG, Cameron DA, et al. The benefits and harms of breast cancer screening: an independent review. Br J Cancer 2013;108:2205–2240. Available at: https://www.ncbi.nlm.nih.gov/pubmed/23744281.

109. Gunsoy NB, Garcia-Closas M, Moss SM. Estimating breast cancer mortality reduction and overdiagnosis due to screening for different strategies in the United Kingdom. Br J Cancer 2014;110:2412–2419. Available at: https://www.ncbi.nlm.nih.gov/pubmed/24762956.

110. Johns LE, Coleman DA, Swerdlow AJ, Moss SM. Effect of population breast screening on breast cancer mortality up to 2005 in England and Wales: an individual-level cohort study. Br J Cancer 2017;116:246–252. Available at: https://www.ncbi.nlm.nih.gov/pubmed/27931047.

111. Hendrick RE. Obligate overdiagnosis due to mammographic screening: A direct estimate for U.S. women. Radiology 2018;287:391–397. Available at: https://www.ncbi.nlm.nih.gov/pubmed/29267146.

112. Mandelblatt JS, Stout NK, Schechter CB, et al. Collaborative modeling of the benefits and harms associated with different U.S. breast cancer screening strategies. Ann Intern Med 2016;164:215–225. Available at: https://www.ncbi.nlm.nih.gov/pubmed/26756606.

113. Hendrick RE, Helvie MA, Hardesty LA. Implications of CISNET modeling on number needed to screen and mortality reduction with digital mammography in women 40-49 years old. AJR Am J Roentgenol 2014;203:1379–1381. Available at: https://www.ncbi.nlm.nih.gov/pubmed/25415718.

114. Mandelblatt, JS.; Cronin, K.; de Koning, H.; Miglioretti, DL.; Schechter, CS.; Stout, N. Collaborative modeling of U.S. breast cancer screening strategies. AHRQ Publication No. 14-05201-EF-4. 2015 Available at: https://www.uspreventiveservicestaskforce.org/Page/Document/modeling-report-collaborative-modeling-of-us-breast-cancer-1/breast-cancer-screening1.

115. Engel JM, Stankowski-Drengler TJ, Stankowski RV, et al. All-cause mortality is decreased in women undergoing annual mammography before breast cancer diagnosis. AJR Am J Roentgenol 2015;204:898–902. Available at: https://www.ncbi.nlm.nih.gov/pubmed/25794084.

116. Duffy SW, Dibden A, Michalopoulos D, et al. Screen detection of ductal carcinoma in situ and subsequent incidence of invasive interval breast cancers: a retrospective population-based study. Lancet Oncol 2016;17:109–114. Available at: http://www.ncbi.nlm.nih.gov/pubmed/26655422.

117. Badgwell BD, Giordano SH, Duan ZZ, et al. Mammography before diagnosis among women age 80 years and older with breast cancer. J Clin Oncol 2008;26:2482–2488. Available at: http://www.ncbi.nlm.nih.gov/pubmed/18427152.

118. Mandelblatt JS, Silliman R. Hanging in the balance: making decisions about the benefits and harms of breast cancer screening among the oldest old without a safety net of scientific evidence. J Clin Oncol 2009;27:487–490. Available at: http://www.ncbi.nlm.nih.gov/pubmed/19075258.

119. van Dijck J, Verbeek A, Hendriks J, et al. Mammographic screening after the age of 65 years: early outcomes in the Nijmegen programme. Br J Cancer 1996;74:1838–1842. Available at: http://www.ncbi.nlm.nih.gov/pubmed/8956803.

120. Walter LC, Covinsky KE. Cancer screening in elderly patients: a framework for individualized decision making. JAMA 2001;285:2750–2756. Available at: http://www.ncbi.nlm.nih.gov/pubmed/11386931.

121. Smith RA, Saslow D, Sawyer KA, et al. American Cancer Society guidelines for breast cancer screening: update 2003. CA Cancer J Clin

Version 1.2026 © 2026 National Comprehensive Cancer Network© (NCCN©), All rights reserved. NCCN Guidelines® and this illustration may not be reproduced in any form without the express written permission of NCCN.

PLEASE NOTE that use of this NCCN Content is governed by the End-User License Agreement, and you MAY NOT distribute this Content or use it with any artificial intelligence model or tool.
Printed by Ambrish Chauhan on 5/1/2026 7:03:18 AM. Copyright © 2026 National Comprehensive Cancer Network, Inc. All Rights Reserved.

2003;53:141–169. Available at: http://www.ncbi.nlm.nih.gov/pubmed/12809408.

122. Amir E, Evans DG, Shenton A, et al. Evaluation of breast cancer risk assessment packages in the family history evaluation and screening programme. J Med Genet 2003;40:807–814. Available at: http://www.ncbi.nlm.nih.gov/pubmed/14627668.

123. Evans DG, Howell A. Breast cancer risk-assessment models. Breast Cancer Res 2007;9:213. Available at: http://www.ncbi.nlm.nih.gov/pubmed/17888188.

124. MD Anderson Cancer Center breast cancer screening algorithm 2020. Available at: https://www.mdanderson.org/content/dam/mdanderson/documents/for-physicians/algorithms/screening/screening-breast-web-algorithm.pdf. Accessed April 10, 2023

125. Bhatia S, Robison LL, Oberlin O, et al. Breast cancer and other second neoplasms after childhood Hodgkin's disease. N Engl J Med 1996;334:745–751. Available at: http://www.ncbi.nlm.nih.gov/pubmed/8592547.

126. Bhatia S, Yasui Y, Robison LL, et al. High risk of subsequent neoplasms continues with extended follow-up of childhood Hodgkin's disease: report from the Late Effects Study Group. J Clin Oncol 2003;21:4386–4394. Available at: http://www.ncbi.nlm.nih.gov/pubmed/14645429.

127. Hancock SL, Tucker MA, Hoppe RT. Breast cancer after treatment of Hodgkin's disease. J Natl Cancer Inst 1993;85:25–31. Available at: http://www.ncbi.nlm.nih.gov/pubmed/8416252.

128. Metayer C, Lynch CF, Clarke EA, et al. Second cancers among long-term survivors of Hodgkin's disease diagnosed in childhood and adolescence. J Clin Oncol 2000;18:2435–2443. Available at: http://www.ncbi.nlm.nih.gov/pubmed/10856104.

129. van Leeuwen FE, Klokman WJ, Stovall M, et al. Roles of radiation dose, chemotherapy, and hormonal factors in breast cancer following Hodgkin's disease. J Natl Cancer Inst 2003;95:971–980. Available at: http://www.ncbi.nlm.nih.gov/pubmed/12837833.

130. Yahalom J, Petrek JA, Biddinger PW, et al. Breast cancer in patients irradiated for Hodgkin's disease: a clinical and pathologic analysis of 45 events in 37 patients. J Clin Oncol 1992;10:1674–1681. Available at: http://www.ncbi.nlm.nih.gov/pubmed/1403050.

131. Travis LB, Hill D, Dores GM, et al. Cumulative absolute breast cancer risk for young women treated for Hodgkin lymphoma. J Natl Cancer Inst 2005;97:1428–1437. Available at: http://www.ncbi.nlm.nih.gov/pubmed/16204692.

132. Oeffinger KC, Ford JS, Moskowitz CS, et al. Breast cancer surveillance practices among women previously treated with chest radiation for a childhood cancer. JAMA 2009;301:404–414. Available at: http://www.ncbi.nlm.nih.gov/pubmed/19176442.

133. Mulder RL, Kremer LC, Hudson MM, et al. Recommendations for breast cancer surveillance for female survivors of childhood, adolescent, and young adult cancer given chest radiation: a report from the International Late Effects of Childhood Cancer Guideline Harmonization Group. Lancet Oncol 2013;14:e621–629. Available at: https://www.ncbi.nlm.nih.gov/pubmed/24275135.

134. Children's Oncology Group long-term follow-up guidelines for survivors of childhood, adolescent, and young adult cancers version 6.0. 2023. Available at: http://www.survivorshipguidelines.org/. Accessed February 22, 2024.

135. Mulder RL, Hudson MM, Bhatia S, et al. Updated breast cancer surveillance recommendations for female survivors of childhood, adolescent, and young adult cancer from the International Guideline Harmonization Group. J Clin Oncol 2020;38:4194–4207. Available at: https://www.ncbi.nlm.nih.gov/pubmed/33078972.

Version 1.2026 © 2026 National Comprehensive Cancer Network© (NCCN©), All rights reserved. NCCN Guidelines® and this illustration may not be reproduced in any form without the express written permission of NCCN.

PLEASE NOTE that use of this NCCN Content is governed by the End-User License Agreement, and you MAY NOT distribute this Content or use it with any artificial intelligence model or tool.
Printed by Ambrish Chauhan on 5/1/2026 7:03:18 AM. Copyright © 2026 National Comprehensive Cancer Network, Inc. All Rights Reserved.

136. Costantino JP, Gail MH, Pee D, et al. Validation studies for models projecting the risk of invasive and total breast cancer incidence. J Natl Cancer Inst 1999;91:1541–1548. Available at: http://www.ncbi.nlm.nih.gov/pubmed/10491430.

137. Gail MH, Brinton LA, Byar DP, et al. Projecting individualized probabilities of developing breast cancer for white females who are being examined annually. J Natl Cancer Inst 1989;81:1879–1886. Available at: http://www.ncbi.nlm.nih.gov/pubmed/2593165.

138. Gail MH, Costantino JP. Validating and improving models for projecting the absolute risk of breast cancer. J Natl Cancer Inst 2001;93:334–335. Available at: http://www.ncbi.nlm.nih.gov/pubmed/11238688.

139. Rockhill B, Spiegelman D, Byrne C, et al. Validation of the Gail et al. model of breast cancer risk prediction and implications for chemoprevention. J Natl Cancer Inst 2001;93:358–366. Available at: http://www.ncbi.nlm.nih.gov/pubmed/11238697.

140. Spiegelman D, Colditz GA, Hunter D, Hertzmark E. Validation of the Gail et al. model for predicting individual breast cancer risk. J Natl Cancer Inst 1994;86:600–607. Available at: http://www.ncbi.nlm.nih.gov/pubmed/8145275.

141. Gail MH, Costantino JP, Pee D, et al. Projecting individualized absolute invasive breast cancer risk in African American women. J Natl Cancer Inst 2007;99:1782–1792. Available at: http://www.ncbi.nlm.nih.gov/pubmed/18042936.

142. Matsuno RK, Costantino JP, Ziegler RG, et al. Projecting individualized absolute invasive breast cancer risk in Asian and Pacific Islander American women. J Natl Cancer Inst 2011;103:951–961. Available at: http://www.ncbi.nlm.nih.gov/pubmed/21562243.

143. Schopf CM, Ramwala OA, Lowry KP, et al. Artificial intelligence-driven mammography-based future breast cancer risk prediction: A systematic review. J Am Coll Radiol 2024;21:319–328. Available at: https://www.ncbi.nlm.nih.gov/pubmed/37949155.

144. Arpino G, Laucirica R, Elledge RM. Premalignant and in situ breast disease: biology and clinical implications. Ann Intern Med 2005;143:446–457. Available at: http://www.ncbi.nlm.nih.gov/pubmed/16172443.

145. Lakhani SR. In-situ lobular neoplasia: time for an awakening. Lancet 2003;361:96. Available at: http://www.ncbi.nlm.nih.gov/pubmed/12531570.

146. Page DL, Schuyler PA, Dupont WD, et al. Atypical lobular hyperplasia as a unilateral predictor of breast cancer risk: a retrospective cohort study. Lancet 2003;361:125–129. Available at: https://www.ncbi.nlm.nih.gov/pubmed/12531579.

147. Morrow M, Schnitt SJ, Norton L. Current management of lesions associated with an increased risk of breast cancer. Nat Rev Clin Oncol 2015;12:227–238. Available at: https://www.ncbi.nlm.nih.gov/pubmed/25622978.

148. Hartmann LC, Degnim AC, Santen RJ, et al. Atypical hyperplasia of the breast — risk assessment and management options. N Engl J Med 2015;372:78–89. Available at: https://www.nejm.org/doi/full/10.1056/NEJMsr1407164.

149. King TA, Pilewskie M, Muhsen S, et al. Lobular carcinoma in situ: A 29-year longitudinal experience evaluating clinicopathologic features and breast cancer risk. J Clin Oncol 2015;33:3945–3952. Available at: https://www.ncbi.nlm.nih.gov/pubmed/26371145.

150. Nelson HD, Zakher B, Cantor A, et al. Risk factors for breast cancer for women aged 40 to 49 years: a systematic review and meta-analysis. Ann Intern Med 2012;156:635–648. Available at: https://www.ncbi.nlm.nih.gov/pubmed/22547473.

151. Mandelson MT, Oestreicher N, Porter PL, et al. Breast density as a predictor of mammographic detection: comparison of interval- and screen-detected cancers. J Natl Cancer Inst 2000;92:1081–1087. Available at: https://www.ncbi.nlm.nih.gov/pubmed/10880551.

Version 1.2026 © 2026 National Comprehensive Cancer Network© (NCCN©), All rights reserved. NCCN Guidelines® and this illustration may not be reproduced in any form without the express written permission of NCCN.

PLEASE NOTE that use of this NCCN Content is governed by the End-User License Agreement, and you MAY NOT distribute this Content or use it with any artificial intelligence model or tool.
Printed by Ambrish Chauhan on 5/1/2026 7:03:18 AM. Copyright © 2026 National Comprehensive Cancer Network, Inc. All Rights Reserved.

152. Chiu SY, Duffy S, Yen AM, et al. Effect of baseline breast density on breast cancer incidence, stage, mortality, and screening parameters: 25-year follow-up of a Swedish mammographic screening. Cancer Epidemiol Biomarkers Prev 2010;19:1219–1228. Available at: http://www.ncbi.nlm.nih.gov/pubmed/20406961.

153. Vachon CM, Sellers TA, Scott CG, et al. Abstract 4828: Longitudinal breast density and risk of breast cancer. Cancer Research 2010;70:4828–4828. Available at: http://cancerres.aacrjournals.org/cgi/content/meeting_abstract/70/8_MeetingAbstracts/4828.

154. Bodewes FTH, van Asselt AA, Dorrius MD, et al. Mammographic breast density and the risk of breast cancer: A systematic review and meta-analysis. Breast 2022;66:62–68. Available at: https://www.ncbi.nlm.nih.gov/pubmed/36183671.

155. Wanders JOP, van Gils CH, Karssemeijer N, et al. The combined effect of mammographic texture and density on breast cancer risk: a cohort study. Breast Cancer Res 2018;20:36. Available at: https://www.ncbi.nlm.nih.gov/pubmed/29720220.

156. Richman I, Asch SM, Bendavid E, et al. Breast density notification legislation and breast cancer stage at diagnosis: Early evidence from the SEER registry. J Gen Intern Med 2017;32:603–609. Available at: https://www.ncbi.nlm.nih.gov/pubmed/27844260.

157. Mammography Quality Standards Act; 2023. Available at: https://www.federalregister.gov/documents/2023/03/10/2023-04550/mammography-quality-standards-act.

158. Bakker MF, de Lange SV, Pijnappel RM, et al. Supplemental MRI screening for women with extremely dense breast tissue. N Engl J Med 2019;381:2091–2102. Available at: https://www.ncbi.nlm.nih.gov/pubmed/31774954.

159. Breast density and supplemental screening. Society of Breast Imaging. White Papers. 2017. Available at: https://www.sbi-online.org/white-papers/breast-density-and-supplemental-screening. Accessed April 4, 2024.

160. Expert Panel on Breast I, Paulis LV, Lewin AA, et al. ACR Appropriateness Criteria(R) supplemental breast cancer screening based on breast density: 2024 update. J Am Coll Radiol 2025;22:S405–S423. Available at: https://www.ncbi.nlm.nih.gov/pubmed/40409891.

161. Barton MB, Elmore JG, Fletcher SW. Breast symptoms among women enrolled in a health maintenance organization: frequency, evaluation, and outcome. Ann Intern Med 1999;130:651–657. Available at: https://www.ncbi.nlm.nih.gov/pubmed/10215561.

162. Manik R, Grady CB, Ginzberg SP, et al. Racial disparities and strategies for improving equity in diagnostic follow-up for abnormal screening mammograms. JCO Oncology Practice 2024;20:1367–1375. Available at: https://ascopubs.org/doi/abs/10.1200/OP.23.00782.

163. Kim S, Molina Y, Glassgow AE, et al. The effects of navigation and types of neighborhoods on timely follow-up of abnormal mammogram among black women. Med Res Arch 2015;2015. Available at: https://www.ncbi.nlm.nih.gov/pubmed/26949738.

164. Marshall JK, Mbah OM, Ford JG, et al. Effect of patient navigation on breast cancer screening among African American medicare beneficiaries: A randomized controlled trial. J Gen Intern Med 2016;31:68–76. Available at: https://www.ncbi.nlm.nih.gov/pubmed/26259762.

165. Noroozian M, Hadjiiski L, Rahnama-Moghadam S, et al. Digital breast tomosynthesis is comparable to mammographic spot views for mass characterization. Radiology 2012;262:61–68. Available at: https://www.ncbi.nlm.nih.gov/pubmed/21998048.

166. Zuley ML, Bandos AI, Ganott MA, et al. Digital breast tomosynthesis versus supplemental diagnostic mammographic views for evaluation of noncalcified breast lesions. Radiology 2013;266:89–95. Available at: https://www.ncbi.nlm.nih.gov/pubmed/23143023.

Version 1.2026 © 2026 National Comprehensive Cancer Network© (NCCN©), All rights reserved. NCCN Guidelines® and this illustration may not be reproduced in any form without the express written permission of NCCN.

PLEASE NOTE that use of this NCCN Content is governed by the End-User License Agreement, and you MAY NOT distribute this Content or use it with any artificial intelligence model or tool.
Printed by Ambrish Chauhan on 5/1/2026 7:03:18 AM. Copyright © 2026 National Comprehensive Cancer Network, Inc. All Rights Reserved.

167. Waldherr C, Cerny P, Altermatt HJ, et al. Value of one-view breast tomosynthesis versus two-view mammography in diagnostic workup of women with clinical signs and symptoms and in women recalled from screening. AJR Am J Roentgenol 2013;200:226–231. Available at: https://www.ncbi.nlm.nih.gov/pubmed/23255766.

168. Brandt KR, Craig DA, Hoskins TL, et al. Can digital breast tomosynthesis replace conventional diagnostic mammography views for screening recalls without calcifications? A comparison study in a simulated clinical setting. AJR Am J Roentgenol 2013;200:291–298. Available at: https://www.ncbi.nlm.nih.gov/pubmed/23345348.

169. Raghu M, Durand MA, Andrejeva L, et al. Tomosynthesis in the diagnostic setting: Changing rates of BI-RADS final assessment over time. Radiology 2016;281:54–61. Available at: https://www.ncbi.nlm.nih.gov/pubmed/27139264.

170. American College of Radiology (ACR). ACR-BI-RADS®--5th Edition. ACR Breast Imaging Reporting and Data System, Breast Imaging Atlas; BI-RADS. Reston VA. American College of Radiology, 2014. . Available at: https://www.acr.org/Clinical-Resources/Reporting-and-Data-Systems/Bi-Rads.

171. Bassett L, Winchester DP, Caplan RB, et al. Stereotactic core-needle biopsy of the breast: a report of the Joint Task Force of the American College of Radiology, American College of Surgeons, and College of American Pathologists. CA Cancer J Clin 1997;47:171–190. Available at: http://www.ncbi.nlm.nih.gov/pubmed/9152175.

172. Flobbe K, Bosch AM, Kessels AG, et al. The additional diagnostic value of ultrasonography in the diagnosis of breast cancer. Arch Intern Med 2003;163:1194–1199. Available at: https://www.ncbi.nlm.nih.gov/pubmed/12767956.

173. Buchberger W, DeKoekkoek-Doll P, Springer P, et al. Incidental findings on sonography of the breast: clinical significance and diagnostic workup. AJR Am J Roentgenol 1999;173:921–927. Available at: http://www.ncbi.nlm.nih.gov/pubmed/10511149.

174. Corsetti V, Houssami N, Ferrari A, et al. Breast screening with ultrasound in women with mammography-negative dense breasts: evidence on incremental cancer detection and false positives, and associated cost. Eur J Cancer 2008;44:539–544. Available at: http://www.ncbi.nlm.nih.gov/pubmed/18267357.

175. Kaplan SS. Clinical utility of bilateral whole-breast US in the evaluation of women with dense breast tissue. Radiology 2001;221:641–649. Available at: http://www.ncbi.nlm.nih.gov/pubmed/11719658.

176. Renz DM, Baltzer PAT, Bottcher J, et al. Inflammatory breast carcinoma in magnetic resonance imaging: a comparison with locally advanced breast cancer. Acad Radiol 2008;15:209–221. Available at: http://www.ncbi.nlm.nih.gov/pubmed/18206620.

177. Bahl M, Baker JA, Greenup RA, Ghate SV. Evaluation of pathologic nipple discharge: What is the added diagnostic value of MRI? Ann Surg Oncol 2015;22 Suppl 3:S435–441. Available at: https://www.ncbi.nlm.nih.gov/pubmed/26249144.

178. Lubina N, Schedelbeck U, Roth A, et al. 3.0 Tesla breast magnetic resonance imaging in patients with nipple discharge when mammography and ultrasound fail. Eur Radiol 2015;25:1285–1293. Available at: https://www.ncbi.nlm.nih.gov/pubmed/25433415.

179. Morrogh M, Morris EA, Liberman L, et al. MRI identifies otherwise occult disease in select patients with Paget disease of the nipple. J Am Coll Surg 2008;206:316–321. Available at: https://www.ncbi.nlm.nih.gov/pubmed/18222386.

180. Abati A, Simsir A. Breast fine needle aspiration biopsy: prevailing recommendations and contemporary practices. Clin Lab Med 2005;25:631–654, v. Available at: https://www.ncbi.nlm.nih.gov/pubmed/16308084.

181. Levine P, Simsir A, Cangiarella J. Management issues in breast lesions diagnosed by fine-needle aspiration and percutaneous core breast biopsy. Am J Clin Pathol 2006;125 Suppl:S124–134. Available at: http://www.ncbi.nlm.nih.gov/pubmed/16830962.

Version 1.2026 © 2026 National Comprehensive Cancer Network© (NCCN©), All rights reserved. NCCN Guidelines® and this illustration may not be reproduced in any form without the express written permission of NCCN.

PLEASE NOTE that use of this NCCN Content is governed by the End-User License Agreement, and you MAY NOT distribute this Content or use it with any artificial intelligence model or tool.
Printed by Ambrish Chauhan on 5/1/2026 7:03:18 AM. Copyright © 2026 National Comprehensive Cancer Network, Inc. All Rights Reserved.

182. Pijnappel RM, van den Donk M, Holland R, et al. Diagnostic accuracy for different strategies of image-guided breast intervention in cases of nonpalpable breast lesions. Br J Cancer 2004;90:595–600. Available at: http://www.ncbi.nlm.nih.gov/pubmed/14760370.

183. Pisano ED, Fajardo LL, Caudry DJ, et al. Fine-needle aspiration biopsy of nonpalpable breast lesions in a multicenter clinical trial: results from the radiologic diagnostic oncology group V. Radiology 2001;219:785–792. Available at: http://www.ncbi.nlm.nih.gov/pubmed/11376270.

184. Fishman JE, Milikowski C, Ramsinghani R, et al. US-guided core-needle biopsy of the breast: how many specimens are necessary? Radiology 2003;226:779–782. Available at: http://www.ncbi.nlm.nih.gov/pubmed/12601206.

185. Yeow KM, Lo YF, Wang CS, et al. Ultrasound-guided core needle biopsy as an initial diagnostic test for palpable breast masses. J Vasc Interv Radiol 2001;12:1313–1317. Available at: http://www.ncbi.nlm.nih.gov/pubmed/11698631.

186. Verkooijen HM. Diagnostic accuracy of stereotactic large-core needle biopsy for nonpalpable breast disease: results of a multicenter prospective study with 95% surgical confirmation. Int J Cancer 2002;99:853–859. Available at: http://www.ncbi.nlm.nih.gov/pubmed/12115488.

187. Pandelidis S, Heiland D, Jones D, et al. Accuracy of 11-gauge vacuum-assisted core biopsy of mammographic breast lesions. Ann Surg Oncol 2003;10:43–47. Available at: http://www.ncbi.nlm.nih.gov/pubmed/12513959.

188. Kettritz U, Rotter K, Schreer I, et al. Stereotactic vacuum-assisted breast biopsy in 2874 patients: a multicenter study. Cancer 2004;100:245–251. Available at: https://www.ncbi.nlm.nih.gov/pubmed/14716757.

189. Sigal-Zafrani B, Muller K, El Khoury C, et al. Vacuum-assisted large-core needle biopsy (VLNB) improves the management of patients with breast microcalcifications - analysis of 1009 cases. Eur J Surg Oncol 2008;34:377–381. Available at: http://www.ncbi.nlm.nih.gov/pubmed/17604937.

190. Burbank F, Forcier N. Tissue marking clip for stereotactic breast biopsy: initial placement accuracy, long-term stability, and usefulness as a guide for wire localization. Radiology 1997;205:407–415. Available at: http://www.ncbi.nlm.nih.gov/pubmed/9356621.

191. Egyed Z, Pentek Z, Jaray B, et al. Radial scar-significant diagnostic challenge. Pathol Oncol Res 2008;14:123–129. Available at: http://www.ncbi.nlm.nih.gov/pubmed/18409019.

192. Tea M-KM, Grimm C, Fink-Retter A, et al. The validity of complex breast cysts after surgery. Am J Surg 2009;197:199–202. Available at: http://www.ncbi.nlm.nih.gov/pubmed/18649871.

193. Cangiarella J, Guth A, Axelrod D, et al. Is surgical excision necessary for the management of atypical lobular hyperplasia and lobular carcinoma in situ diagnosed on core needle biopsy?: a report of 38 cases and review of the literature. Arch Pathol Lab Med 2008;132:979–983. Available at: http://www.ncbi.nlm.nih.gov/pubmed/18517282.

194. Elsheikh TM, Silverman JF. Follow-up surgical excision is indicated when breast core needle biopsies show atypical lobular hyperplasia or lobular carcinoma in situ: a correlative study of 33 patients with review of the literature. Am J Surg Pathol 2005;29:534–543. Available at: http://www.ncbi.nlm.nih.gov/pubmed/15767810.

195. Frouge C, Tristant H, Guinebretiere JM, et al. Mammographic lesions suggestive of radial scars: microscopic findings in 40 cases. Radiology 1995;195:623–625. Available at: http://www.ncbi.nlm.nih.gov/pubmed/7753984.

196. Margenthaler JA, Duke D, Monsees BS, et al. Correlation between core biopsy and excisional biopsy in breast high-risk lesions. Am J Surg 2006;192:534–537. Available at: http://www.ncbi.nlm.nih.gov/pubmed/16978969.

Version 1.2026 © 2026 National Comprehensive Cancer Network© (NCCN©), All rights reserved. NCCN Guidelines® and this illustration may not be reproduced in any form without the express written permission of NCCN.

PLEASE NOTE that use of this NCCN Content is governed by the End-User License Agreement, and you MAY NOT distribute this Content or use it with any artificial intelligence model or tool.
Printed by Ambrish Chauhan on 5/1/2026 7:03:18 AM. Copyright © 2026 National Comprehensive Cancer Network, Inc. All Rights Reserved.

197. Parker SH, Burbank F, Jackman RJ, et al. Percutaneous large-core breast biopsy: a multi-institutional study. Radiology 1994;193:359–364. Available at: http://www.ncbi.nlm.nih.gov/pubmed/7972743.

198. Linell F, Pinder SE, Ellis IO. Precursor lesions of breast carcinoma. The Breast 1993;2:220–223. Available at: http://www.sciencedirect.com/science/article/pii/096097769390003X.

199. Kaiser JS, Helvie MA, Blacklaw RL, Roubidoux MA. Palpable breast thickening: role of mammography and US in cancer detection. Radiology 2002;223:839–844. Available at: https://www.ncbi.nlm.nih.gov/pubmed/12034957.

200. Loving VA, DeMartini WB, Eby PR, et al. Targeted ultrasound in women younger than 30 years with focal breast signs or symptoms: outcomes analyses and management implications. AJR Am J Roentgenol 2010;195:1472–1477. Available at: https://www.ncbi.nlm.nih.gov/pubmed/21098212.

201. Robbins J, Jeffries D, Roubidoux M, Helvie M. Accuracy of diagnostic mammography and breast ultrasound during pregnancy and lactation. AJR Am J Roentgenol 2011;196:716–722. Available at: https://www.ncbi.nlm.nih.gov/pubmed/21343518.

202. Lehman CD, Lee CI, Loving VA, et al. Accuracy and value of breast ultrasound for primary imaging evaluation of symptomatic women 30-39 years of age. AJR Am J Roentgenol 2012;199:1169–1177. Available at: http://www.ncbi.nlm.nih.gov/pubmed/23096195.

203. Lehman CD, Lee AY, Lee CI. Imaging management of palpable breast abnormalities. AJR Am J Roentgenol 2014;203:1142–1153. Available at: https://www.ncbi.nlm.nih.gov/pubmed/25341156.

204. Harvey JA, Mahoney MC, Newell MS, et al. ACR appropriateness criteria palpable breast masses. J Am Coll Radiol 2016;13:e31–e42. Available at: https://www.ncbi.nlm.nih.gov/pubmed/27814822.

205. Soo MS, Rosen EL, Baker JA, et al. Negative predictive value of sonography with mammography in patients with palpable breast lesions. AJR Am J Roentgenol 2001;177:1167–1170. Available at: https://www.ncbi.nlm.nih.gov/pubmed/11641195.

206. Shetty MK, Shah YP. Prospective evaluation of the value of negative sonographic and mammographic findings in patients with palpable abnormalities of the breast. J Ultrasound Med 2002;21:1211–1216; quiz 1217–1219. Available at: https://www.ncbi.nlm.nih.gov/pubmed/12418762.

207. Moy L, Slanetz PJ, Moore R, et al. Specificity of mammography and US in the evaluation of a palpable abnormality: retrospective review. Radiology 2002;225:176–181. Available at: https://www.ncbi.nlm.nih.gov/pubmed/12355002.

208. Breast implants - certain labeling

recommendations to improve patient

communication 2020. Available at: https://www.fda.gov/media/131885/download. Accessed November 5, 2023.

209. Leung SE, Ben-Nachum I, Kornecki A. New palpable breast lump with recent negative mammogram: Is repeat mammography necessary? AJR Am J Roentgenol 2016;207:200–204. Available at: https://www.ncbi.nlm.nih.gov/pubmed/27081707.

210. Booi RC, Carson PL, O'Donnell M, et al. Characterization of cysts using differential correlation coefficient values from two dimensional breast elastography: preliminary study. Ultrasound Med Biol 2008;34:12–21. Available at: https://www.ncbi.nlm.nih.gov/pmc/articles/PMC2330278/pdf/nihms36784.pdf.

211. Ashbeck EL, Rosenberg RD, Stauber PM, Key CR. Benign breast biopsy diagnosis and subsequent risk of breast cancer. Cancer Epidemiol Biomarkers Prev 2007;16:467–472. Available at: https://www.ncbi.nlm.nih.gov/pubmed/17337650.

Version 1.2026 © 2026 National Comprehensive Cancer Network© (NCCN©), All rights reserved. NCCN Guidelines® and this illustration may not be reproduced in any form without the express written permission of NCCN.

PLEASE NOTE that use of this NCCN Content is governed by the End-User License Agreement, and you MAY NOT distribute this Content or use it with any artificial intelligence model or tool.
Printed by Ambrish Chauhan on 5/1/2026 7:03:18 AM. Copyright © 2026 National Comprehensive Cancer Network, Inc. All Rights Reserved.

212. Daly CP, Bailey JE, Klein KA, Helvie MA. Complicated breast cysts on sonography: is aspiration necessary to exclude malignancy? Acad Radiol 2008;15:610–617. Available at: http://www.ncbi.nlm.nih.gov/pubmed/18423318.

213. Huff JG. The sonographic findings and differing clinical implications of simple, complicated, and complex breast cysts. J Natl Compr Canc Netw 2009;7:1101–1104; quiz 1105. Available at: http://www.ncbi.nlm.nih.gov/pubmed/19930976.

214. Venta LA, Kim JP, Pelloski CE, Morrow M. Management of complex breast cysts. AJR Am J Roentgenol 1999;173:1331–1336. Available at: http://www.ncbi.nlm.nih.gov/pubmed/10541113.

215. Doshi DJ, March DE, Crisi GM, Coughlin BF. Complex cystic breast masses: diagnostic approach and imaging-pathologic correlation. Radiographics 2007;27 Suppl 1:53–64. Available at: http://www.ncbi.nlm.nih.gov/pubmed/18180235.

216. Expert Panel on Breast I, Klein KA, Kocher M, et al. ACR Appropriateness Criteria(R) palpable breast masses: 2022 Update. J Am Coll Radiol 2023;20:S146–S163. Available at: https://www.ncbi.nlm.nih.gov/pubmed/37236740.

217. Hussain AN, Policarpio C, Vincent MT. Evaluating nipple discharge. Obstet Gynecol Surv 2006;61:278–283. Available at: http://www.ncbi.nlm.nih.gov/pubmed/16551379.

218. Jain A, Crawford S, Larkin A, et al. Management of nipple discharge: technology chasing application. Breast J 2010;16:451–452. Available at: http://www.ncbi.nlm.nih.gov/pubmed/20443787.

219. Markopoulos C, Mantas D, Kouskos E, et al. Surgical management of nipple discharge. Eur J Gynaecol Oncol 2006;27:275–278. Available at: http://www.ncbi.nlm.nih.gov/pubmed/16800258.

220. Fuchsjager MH, Philipp MO, Loewe C, Helbich TH. [Diagnostic management of nipple discharge]. Wien Klin Wochenschr 2003;115 Suppl 2:33–39. Available at: http://www.ncbi.nlm.nih.gov/pubmed/15518144.

221. Jardines L. Management of nipple discharge. Am Surg 1996;62:119–122. Available at: http://www.ncbi.nlm.nih.gov/pubmed/8554189.

222. Ohuchi N, Furuta A, Mori S. Management of ductal carcinoma in situ with nipple discharge. Intraductal spreading of carcinoma is an unfavorable pathologic factor for breast-conserving surgery. Cancer 1994;74:1294–1302. Available at: http://www.ncbi.nlm.nih.gov/pubmed/8055451.

223. Gulay H, Bora S, Kilicturgay S, et al. Management of nipple discharge. J Am Coll Surg 1994;178:471–474. Available at: http://www.ncbi.nlm.nih.gov/pubmed/8167884.

224. Vavolizza RD, Dengel LT. Management of nipple discharge. Surg Clin North Am 2022;102:1077–1087. Available at: https://www.ncbi.nlm.nih.gov/pubmed/36335926.

225. Leis HP, Jr. Management of nipple discharge. World J Surg 1989;13:736–742. Available at: http://www.ncbi.nlm.nih.gov/pubmed/2696228.

226. Sabel MS, Helvie MA, Breslin T, et al. Is duct excision still necessary for all cases of suspicious nipple discharge? Breast J 2012;18:157–162. Available at: https://www.ncbi.nlm.nih.gov/pubmed/22211878.

227. Ashfaq A, Senior D, Pockaj BA, et al. Validation study of a modern treatment algorithm for nipple discharge. Am J Surg 2014;208:222–227. Available at: https://www.ncbi.nlm.nih.gov/pubmed/24767970.

228. Tokuda Y, Kuriyama K, Nakamoto A, et al. Evaluation of suspicious nipple discharge by magnetic resonance mammography based on breast imaging reporting and data system magnetic resonance imaging descriptors. J Comput Assist Tomogr 2009;33:58–62. Available at: https://www.ncbi.nlm.nih.gov/pubmed/19188786.

Version 1.2026 © 2026 National Comprehensive Cancer Network© (NCCN©), All rights reserved. NCCN Guidelines® and this illustration may not be reproduced in any form without the express written permission of NCCN.

PLEASE NOTE that use of this NCCN Content is governed by the End-User License Agreement, and you MAY NOT distribute this Content or use it with any artificial intelligence model or tool.
Printed by Ambrish Chauhan on 5/1/2026 7:03:18 AM. Copyright © 2026 National Comprehensive Cancer Network, Inc. All Rights Reserved.

229. Ballesio L, Maggi C, Savelli S, et al. Role of breast magnetic resonance imaging (MRI) in patients with unilateral nipple discharge: preliminary study. Radiol Med 2008;113:249–264. Available at: http://www.ncbi.nlm.nih.gov/pubmed/18386126.

230. Morrogh M, Morris EA, Liberman L, et al. The predictive value of ductography and magnetic resonance imaging in the management of nipple discharge. Ann Surg Oncol 2007;14:3369–3377. Available at: https://www.ncbi.nlm.nih.gov/pubmed/17896158.

231. Foulkes RE, Heard G, Boyce T, et al. Duct excision is still necessary to rule out breast cancer in patients presenting with spontaneous bloodstained nipple discharge. Int J Breast Cancer 2011;2011:495315. Available at: http://www.ncbi.nlm.nih.gov/pubmed/22295227.

232. Dawood S, Cristofanilli M. What progress have we made in managing inflammatory breast cancer? Oncology (Williston Park) 2007;21:673–679. Available at: http://www.ncbi.nlm.nih.gov/pubmed/17564325.

233. Haagensen C. Inflammatory carcinoma. In: Diseases of the breast. 3rd ed. Philadelphia: WB Saunders; 1986.

234. Sakorafas GH, Blanchard DK, Sarr MG, Farley DR. Paget's disease of the breast: a clinical perspective. Langenbecks Arch Surg 2001;386:444–450. Available at: http://www.ncbi.nlm.nih.gov/pubmed/11735019.

235. Ikeda DM, Helvie MA, Frank TS, et al. Paget disease of the nipple: radiologic-pathologic correlation. Radiology 1993;189:89–94. Available at: https://www.ncbi.nlm.nih.gov/pubmed/8396786.

236. Dogan A, Kern P, Schultheis B, et al. Radiogenic angiosarcoma of the breast: case report and systematic review of the literature. BMC Cancer 2018;18:463. Available at: https://www.ncbi.nlm.nih.gov/pubmed/29690864.

237. Smith RL, Pruthi S, Fitzpatrick LA. Evaluation and management of breast pain. Mayo Clin Proc 2004;79:353–372. Available at: https://www.ncbi.nlm.nih.gov/pubmed/15008609.

238. Noroozian M, Stein LF, Gaetke-Udager K, Helvie MA. Long-term clinical outcomes in women with breast pain in the absence of additional clinical findings: mammography remains indicated. Breast Cancer Res Treat 2015;149:417–424. Available at: https://www.ncbi.nlm.nih.gov/pubmed/25556516.

239. Cornell LF, Sandhu NP, Pruthi S, Mussallem DM. Current management and treatment options for breast pain. Mayo Clin Proc 2020;95:574–580. Available at: https://www.ncbi.nlm.nih.gov/pubmed/32138883.

240. Barros AC, Mottola J, Ruiz CA, et al. Reassurance in the treatment of mastalgia. Breast J 1999;5:162–165. Available at: https://www.ncbi.nlm.nih.gov/pubmed/11348279.

241. Walsh R, Kornguth PJ, Soo MS, et al. Axillary lymph nodes: mammographic, pathologic, and clinical correlation. AJR Am J Roentgenol 1997;168:33–38. Available at: https://www.ncbi.nlm.nih.gov/pubmed/8976915.

242. Shipchandler TZ, Lorenz RR, McMahon J, Tubbs R. Supraclavicular lymphadenopathy due to silicone breast implants. Arch Otolaryngol Head Neck Surg 2007;133:830–832. Available at: https://www.ncbi.nlm.nih.gov/pubmed/17709626.

243. de Andrade JM, Marana HR, Sarmento Filho JM, et al. Differential diagnosis of axillary masses. Tumori 1996;82:596–599. Available at: https://www.ncbi.nlm.nih.gov/pubmed/9061072.

244. Gorkem SB, O'Connell AM. Abnormal axillary lymph nodes on negative mammograms: causes other than breast cancer. Diagn Interv Radiol 2012;18:473–479. Available at: https://www.ncbi.nlm.nih.gov/pubmed/22415745.

Version 1.2026 © 2026 National Comprehensive Cancer Network© (NCCN©), All rights reserved. NCCN Guidelines® and this illustration may not be reproduced in any form without the express written permission of NCCN.

PLEASE NOTE that use of this NCCN Content is governed by the End-User License Agreement, and you MAY NOT distribute this Content or use it with any artificial intelligence model or tool.
Printed by Ambrish Chauhan on 5/1/2026 7:03:18 AM. Copyright © 2026 National Comprehensive Cancer Network, Inc. All Rights Reserved.

245. Schiaffino S, Pinker K, Magni V, et al. Axillary lymphadenopathy at the time of COVID-19 vaccination: ten recommendations from the European Society of Breast Imaging (EUSOBI). Insights Imaging 2021;12:119. Available at: https://www.ncbi.nlm.nih.gov/pubmed/34417642.

246. Shirone N, Shinkai T, Yamane T, et al. Axillary lymph node accumulation on FDG-PET/CT after influenza vaccination. Ann Nucl Med 2012;26:248–252. Available at: https://www.ncbi.nlm.nih.gov/pubmed/22271546.

247. Nelson JA, Dabic S, Mehrara BJ, et al. Breast implant-associated anaplastic large cell lymphoma incidence: Determining an accurate risk. Ann Surg 2020;272:403–409. Available at: https://www.ncbi.nlm.nih.gov/pubmed/32694446.

248. Update: Reports of squamous cell carcinoma (SCC) in the capsule around breast implants - FDA safety communication. 2023. Available at: https://www.fda.gov/medical-devices/safety-communications/update-reports-squamous-cell-carcinoma-scc-capsule-around-breast-implants-fda-safety-communication#:~:text=Update%3A%20March%2022%2C%202023&text=The%20FDA%20continues%20to%20recommend,breast%20implant%20to%20the%20FDA. Accessed June 29, 2023.

249. Prothe J, Rozovics P, Sykes R, Taccona M. Breast implant surgery: An overview of the risks and health complications. Plast Aesthet Nurs (Phila) 2023;43:68–71. Available at: https://www.ncbi.nlm.nih.gov/pubmed/37000998.

250. Ayyappan AP, Kulkarni S, Crystal P. Pregnancy-associated breast cancer: spectrum of imaging appearances. Br J Radiol 2010;83:529–534. Available at: https://www.ncbi.nlm.nih.gov/pubmed/20335428.

251. Reed W, Hannisdal E, Skovlund E, et al. Pregnancy and breast cancer: a population-based study. Virchows Arch 2003;443:44–50. Available at: https://www.ncbi.nlm.nih.gov/pubmed/12756565.

252. Sabate JM, Clotet M, Torrubia S, et al. Radiologic evaluation of breast disorders related to pregnancy and lactation. Radiographics 2007;27 Suppl 1:S101–124. Available at: https://www.ncbi.nlm.nih.gov/pubmed/18180221.

253. Vashi R, Hooley R, Butler R, et al. Breast imaging of the pregnant and lactating patient: physiologic changes and common benign entities. AJR Am J Roentgenol 2013;200:329–336. Available at: https://www.ncbi.nlm.nih.gov/pubmed/23345354.

254. Barnes DM, Newman LA. Pregnancy-associated breast cancer: a literature review. Surg Clin North Am 2007;87:417–430, x. Available at: https://www.ncbi.nlm.nih.gov/pubmed/17498535.

255. Langer A, Mohallem M, Stevens D, et al. A single-institution study of 117 pregnancy-associated breast cancers (PABC): Presentation, imaging, clinicopathological data and outcome. Diagn Interv Imaging 2014;95:435–441. Available at: https://www.ncbi.nlm.nih.gov/pubmed/24485752.

256. ACR manual on contrast media. 2023. Available at: https://www.acr.org/-/media/ACR/Files/Clinical-Resources/Contrast_Media.pdf. Accessed November 5, 2023.

257. Committee opinion no. 723: Guidelines for diagnostic imaging during pregnancy and lactation. Obstet Gynecol 2017;130:e210–e216. Available at: https://www.ncbi.nlm.nih.gov/pubmed/28937575.

258. McCollough CH, Schueler BA, Atwell TD, et al. Radiation exposure and pregnancy: when should we be concerned? Radiographics 2007;27:909–917; discussion 917–908. Available at: https://www.ncbi.nlm.nih.gov/pubmed/17620458.

259. American College of O, Gynecologists' Committee on Obstetric P. Committee opinion No. 656: Guidelines for diagnostic imaging during pregnancy and lactation. Obstet Gynecol 2016;127:e75–80. Available at: https://www.ncbi.nlm.nih.gov/pubmed/26942391.

Version 1.2026 © 2026 National Comprehensive Cancer Network© (NCCN©), All rights reserved. NCCN Guidelines® and this illustration may not be reproduced in any form without the express written permission of NCCN.

PLEASE NOTE that use of this NCCN Content is governed by the End-User License Agreement, and you MAY NOT distribute this Content or use it with any artificial intelligence model or tool.
Printed by Ambrish Chauhan on 5/1/2026 7:03:18 AM. Copyright © 2026 National Comprehensive Cancer Network, Inc. All Rights Reserved.

260. Tirada N, Dreizin D, Khati NJ, et al. Imaging pregnant and lactating patients. Radiographics 2015;35:1751–1765. Available at: https://www.ncbi.nlm.nih.gov/pubmed/26466183.

261. Expert Panel on Breast I, diFlorio-Alexander RM, Slanetz PJ, et al. ACR Appropriateness Criteria((R)) breast imaging of pregnant and lactating women. J Am Coll Radiol 2018;15:S263–S275. Available at: https://www.ncbi.nlm.nih.gov/pubmed/30392595.

262. Chen MM, Coakley FV, Kaimal A, Laros RK, Jr. Guidelines for computed tomography and magnetic resonance imaging use during pregnancy and lactation. Obstet Gynecol 2008;112:333–340. Available at: https://www.ncbi.nlm.nih.gov/pubmed/18669732.

263. Kubik-Huch RA, Gottstein-Aalame NM, Frenzel T, et al. Gadopentetate dimeglumine excretion into human breast milk during lactation. Radiology 2000;216:555–558. Available at: https://www.ncbi.nlm.nih.gov/pubmed/10924585.

264. Myers KS, Green LA, Lebron L, Morris EA. Imaging appearance and clinical impact of preoperative breast MRI in pregnancy-associated breast cancer. AJR Am J Roentgenol 2017;209:W177–W183. Available at: https://www.ncbi.nlm.nih.gov/pubmed/28609163.

265. Expert Panel on Breast I, Salkowski LR, Lewin AA, et al. ACR Appropriateness Criteria(R) breast imaging during pregnancy. J Am Coll Radiol 2025;22:S492–S507. Available at: https://www.ncbi.nlm.nih.gov/pubmed/41193040.

266. ACR manual on contrast media 2023. Available at: https://www.acr.org/Clinical-Resources/Contrast-Manual. Accessed January 23, 2024.

267. Mohamad N, Sulaiman Z, Tengku Ismail TA, Ahmad S. Bloody nipple discharge post delivery: A case of "rusty pipe syndrome". Korean J Fam Med 2021;42:339–341. Available at: https://www.ncbi.nlm.nih.gov/pubmed/32475105.

268. Barco I, Vidal MC, Barco J, et al. Blood-stained colostrum and human milk during pregnancy and early lactation. J Hum Lact 2014;30:413–415. Available at: https://www.ncbi.nlm.nih.gov/pubmed/24925862.

269. Alipour S. Local complications of breast surgery during pregnancy and lactation. Adv Exp Med Biol 2020;1252:101–105. Available at: https://www.ncbi.nlm.nih.gov/pubmed/32816268.

270. Berg WA, Campassi CI, Ioffe OB. Cystic lesions of the breast: sonographic-pathologic correlation. Radiology 2003;227:183–191. Available at: http://www.ncbi.nlm.nih.gov/pubmed/12668745.

Version 1.2026 © 2026 National Comprehensive Cancer Network© (NCCN©), All rights reserved. NCCN Guidelines® and this illustration may not be reproduced in any form without the express written permission of NCCN.